ARABSPINE COURSE DIPLOMA

Module 4

Course Highlight Day-1

Deformity:

Normal Growth

Idiopathic Scoliosis

Degenerative Scoliosis

Neuromuscular Scoliosis

Sagittal Deformities

Spinal Malformations

Complications Related to:

Anterior and Posterior Approach:

Cervical Spine

Lumbar Spine

Thoracic Spine

Revision Procedures

NASS ADVANCING GLOBAL SPINE CARE

ArabSpine

RCSI

Dubai, UAE

Dear Participant,

It is our pleasure to welcome you all to the ArabSpine Course Diploma.

The course is being presented by renowned experts in the field of Spine Surgery. It is intended for Neurosurgeons, Orthopedists, Spine Specialists and Spine related physicians wishing to acquire advanced theoretical knowledge and improve their practical skills.

ArabSpine Course Diploma offers an up to date knowledge on diagnosis, treatment options of spine pathologies in addition to wide exposure to different surgical techniques practiced in the laboratory on fresh cadavers along with hands-on training on advanced technology such as spinal navigation and 3D imaging using O-Arm.

After the completion of 4 modules each attendee will be well proficient in the evaluation, diagnosis and management of spinal disorders.

We are certain that you will acquire the best knowledge and training in the spinal treatment through the courses of ArabSpine Course Diploma.

Best wishes

Prof. Jeffrey Wang
President
North American Spine Society
(NASS)

Prof. Ciaran Bolger
Head of Clinical Neuroscience
Royal College of Surgeons Ireland
(RCSI)

Prof. Richard Assaker
Chairman
Educational Committee
(ASCD)

Prof. Abdul Karim Msaddi
Chairman
ArabSpine Course Diploma
(ASCD)

INTRODUCTION:

The ASCD strive to establish Arab education high standards and position itself as a major driving force in Spine Education for the Arab region to act as a reference point and resource for spine specialists wishing to acquire up to date knowledge on the evaluation and management of spinal disorders. It aims to provide excellence in spine education and hands-on training in spinal surgery.

The ArabSpine Course Diploma is already accredited by the North American Spine Society (NASS), Royal College of Surgeons in Ireland (RCSI) and University of Basrah.

The ASCD will offer to the participant an opportunity to learn, interact, discuss with the experts and practice hands-on workshops.

We believe that this initiative will further strengthen the Spine Care in the whole Arab Region and Neighbouring Countries.

The diploma outlines includes:

ArabSpine Course Diploma	
M O D U L E S	Surgical Training
Module No. 1 Basic Science & Degenrative Lumbar Spine	Hands-on Cadaveric Workshop
Module No. 2 Cervical Spine Degenerative / Spinal Navigation / Intra-operative Monitoring - IOM	Hands-on Cadaveric Workshop
Module No. 3 Tumor / Trauma / Infection	Hands-on Cadaveric Workshop
Module No. 4 Deformity / Complications / Malformations	Hands-on Cadaveric Workshop

Target Participants

Neurosurgeons, Orthopedists, Spine Specialists & Spine Care Related Physicians

Prof. Richard Assaker
Chairman of Educational Committee (ASCD)

CONTENTS

NORMAL SPINE ALIGNMENT AND SPINAL DEFORMITY 6

BIOMECHANICS OF THE DEFORMED SPINE 15

ADOLESCENT IDIOPATHIC SCOLIOSIS: NATURAL HISTORY AND CLASSIFICATION 22

ADULT SCOLIOSIS: NATURAL HISTORY AND CLASSIFICATION 37

ADULT KYPHOSIS 46

CLINICAL ASSESSMENT IN DEFORMITY PATIENT 68

IMAGING IN SPINAL DEFORMITIES 69

NEUROMUSCULAR DEFORMITIES: SCOLIOSIS AND KYPHOSIS 74

CONGENITAL MALFORMATIONS ASSOCIATED TO SPINAL DEFORMITIES 78

ROLE OF CAST, BRACE AND REHABILITATION 86

PRE-OP ASSESSMENT 95

POSITIONING / BLOOD SAVING 107

PLANNING & STRATEGY IN DEFORMITY CORRECTION 112

IOM IN DEFORMITY SURGERY 137

INDICATIONS FOR POSTERIOR AND ANTERIOR APPROACHES 146

POSTERIOR APPROACH: PRINCIPLES AND TECHNICAL NOTES THORACO-LUMBAR 185

ANTERIOR APPROACH: PRINCIPLES AND TECHNICAL NOTES 193

HYBRID FIXATION (HOOKS, SCREWS, WIRES) 226

NAVIGATION IN DEFORMITY SURGERY 239

MANAGING COMPLEX CASES 250

SACRO-ILIAC FIXATION PRINCIPLE AND TECHNICAL OPTIONS 261

ROLES AND OPTIONS OF OSTEOTOMIES IN DEFORMITY CORRECTION 268

NORMAL SPINE ALIGNMENT AND SPINAL DEFORMITY

Normal Spine Alignment and Spinal Deformity

- Although methods for treatment of spinal deformities have changed, the fundamental goals remain the same
  - Reduce or realign spinal curvature
  - Decrease cosmetic effect of curvature
  - Decrease pain and increase function
  - Maintain and protect organs

Normal Spine Alignment and Spinal Deformity

- Thorough understanding of normal spine alignment is crucial
- "Normal spine alignment" has wide range of variability
- Multiplanar approach
- Three dimensional construct

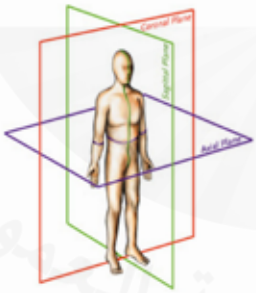

Normal Spine Alignment and Spinal Deformity

- Three planes to consider
  - Coronal
  - Sagittal
  - Axial

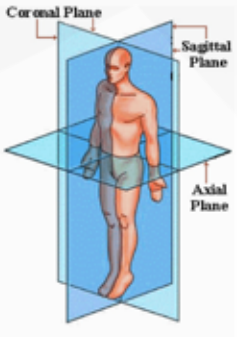

Normal Spine Alignment and Spinal Deformity

- Coronal plane
  - Spine is typically straight
  - Standing anteroposterior radiograph:
    - Plumb line from tip of the dens (C2) should bisect each verterbral body below
    - From cervical spine to sacrum

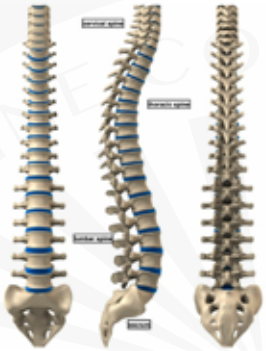

Normal Spine Alignment and Spinal Deformity

- Curves in the coronal planes described by curve convexity (left vs right)
- Cobb Angle
  - Invented in 1948
  - Most tilted vertebrae above and below
  - Lines parallel to endplate above and below
  - Angle between perpendiculars of these lines

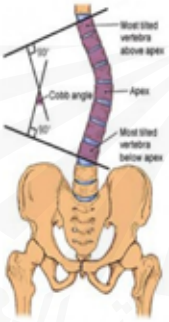

Normal Spine Alignment and Spinal Deformity

- Cobb Angle
  - Scoliosis: >10 degrees in the coronal plane
  - Standard measurement error
    - 3-5 degrees within same observer
    - 5-7 degrees between two observers

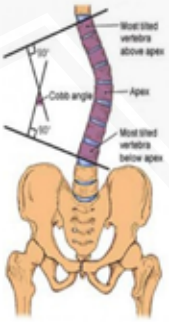

Normal Spine Alignment and Spinal Deformity

- Axial plane
  - No rotation or translocation
  - Rotational deformities can and do occur with deformities in the coronal plane
  - High correlation of axial rotation with vertebral lateral deviation
  - Recognized as the "rib hump" in thoracic scoliosis

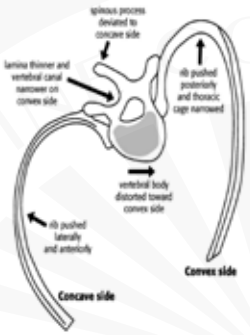

Normal Spine Alignment and Spinal Deformity

- Sagittal plane
  - "Normal" defined less easily
  - Significant variation
  - Typical "S-shape" curvature
  - Lordosis in the cephalad and caudal regions
  - Kyphosis in between

Normal Spine Alignment and Spinal Deformity

- Sagittal plane
  - Varying reports on normal values for acceptable kyphosis or lordosis
  - Cervical spine: 40 degrees +/- 9.7 degrees

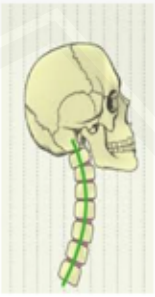

Normal Spine Alignment and Spinal Deformity

- Sagittal plane
  - Normal thoracic kyphosis
  - Range of 20-50 degrees
  - Tends to increase with age
  - Apex between T6 and T8

Normal Spine Alignment and Spinal Deformity

- Sagittal plane
  - Normal lumbar lordosis
  - Range from 30-80 degrees
  - Lordosis primarily occurs at L4-S1
    - 40% L5-S1
  - Wedging of intervertebral discs (80%)
  - Shape of vertebral bodies (20%)

Normal Spine Alignment and Spinal Deformity

- Sagittal balance
  - C7 vertebral body usually in alignment with S1
  - Positive correlation between thoracic kyphosis and lumbar lordosis
  - Plumb line from center of C7 vertebral body lies within 2cm of sacral promontory
  - As individual ages, line can move forward

Normal Spine Alignment and Spinal Deformity

- Sagittal balance
  - Most reliable predictor of clinical symptoms
  - Radiographic markers provide objective evaluation

Normal Spine Alignment and Spinal Deformity

- Sagittal balance
  - Sagittal vertical axis (SVA)
  - Chin-Brow vertical angle
  - C7 plumb line
  - Kyphosis tilt angle
  - Pelvic incidence
  - Pelvic tilt
  - Sacral Slope
  - Spino-pelvic angle
- Separate lecture on radiologic findings

Normal Spine Alignment and Spinal Deformity

- Overall behavior of spine
  - Rigid pieces of bone
  - Semirigid discs and ligaments
  - Semifluid nucleus pulposis
  - Flexible rod

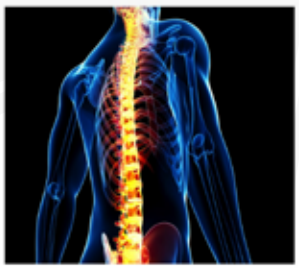

Normal Spine Alignment and Spinal Deformity

- Anatomical distinctions
  - Hyperlordosis – "swayback"
  - Kyphosis – typically greater than 50 degrees
  - Scoliosis – curve in coronal plane, usually C or S-shaped
- Clinical distinctions
  - Infantile
  - Juvenile
  - Adolescent
  - Adult

Normal Spine Alignment and Spinal Deformity

- Lordosis
  - Osteoporosis
  - Obesity
  - Kyphosis
  - Achondroplasia
  - Spondylolisthesis
- Kyphosis
  - Scheuermann's disease
  - Arthritis
  - Osteoporosis/fractures
  - Spinal Bifida
  - Postural Kyphosis
  - Congential

Normal Spine Alignment and Spinal Deformity

- Structural Scoliosis
  - Idiopathic
    - 80%
    - As name implies, unclear etiology
    - Age of onset divisions
  - Congenital
    - Abnormal formation during embryonic development
      - Most common presentation is hemivertebra
  - Acquired
    - Disease related – cerebral palsy, muscular dystrophy, Duchenne's muscular dystrophy

Normal Spine Alignment and Spinal Deformity

- Idiopathic Scoliosis
  - Infantile
    - Least common
    - <3 years
    - Males>females
  - Juvenile
    - 4-10 years
    - Males = females
  - Adolescent
    - Most common
    - >10 years
    - Males=females, however females progress much more frequently

Normal Spine Alignment and Spinal Deformity

- Adolescent Idiopathic Scoliosis
  - 10-18 years
  - >10 degree cobb angle
  - Right thoracic curve most common
  - 10:1 female ratio for curves greater than 30 degrees
  - Unknown pathophysiology
  - Likely genetic component
  - Prevalence 1-2%
  - If Cobb angle <20 degrees, 10-20% will progress

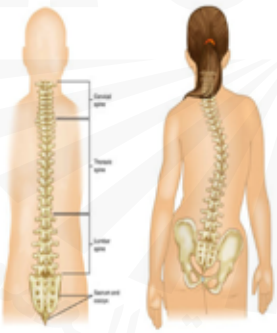

Normal Spine Alignment and Spinal Deformity

- Adolescent Idiopathic Scoliosis
  - King-Moe Classification
    - 5 types describing thoracic curve
  - Lenke Classification
    - Based on PA, Lateral, and Supine bending films
      - Identification of primary curve
      - Assign lumbar modifier
      - Assign sagittal modifier
  - Dr. Mhaidli to further discuss



Normal Spine Alignment and Spinal Deformity

- Adult Spinal Deformity
  - Mean age 60 years
  - Equal male/female distribution
  - Worldwide prevalence is not well established, estimated between 2.5 —25%

Normal Spine Alignment and Spinal Deformity

- Adult Spinal Deformity
  - Asymmetric degeneration of discs and/or joints
    - Scoliosis – coronal plane
    - Kyphosis/lordosis – sagittal plane
  - Factors associated with ASD
    - osteoporosis
    - degenerative disc disease
    - instability
    - pre-existing scoliosis

Normal Spine Alignment and Spinal Deformity

- Adult Spinal Deformity
  - Idiopathic (residual)
    - Follows classic curve patterns
    - Involves more vertebral segments
    - Primarily in thoracic spine
    - Larger curves
  - Degenerative (de novo)
    - Lack classic patterns
    - Fewer segments
    - More often in lumbar spine
    - Smaller magnitude
  - Dr. Hah to discuss further

Normal Spine Alignment and Spinal Deformity

- Summary
- "Normal spine alignment" has wide range of variability
- Multiplanar approach
- Three dimensional construct
- Fundamental goals of treatment for spinal deformity
  - Reduce or realign spinal curvature
  - Decrease cosmetic effect of curvature
  - Decrease pain and increase function
  - Maintain and protect organs

Normal Spine Alignment and Spinal Deformity

- References

- Bono CM, Garvin SR, Tornetta P, Einhorn TA. Spine. Lipincott Williams & Wilkins. P. 175.
- Diebo BG, Varghese JJ, Lafage R, Schwab FJ, Lafage V. Sagittal Alignment of the Spine: What do you Need to Know? Clin Neurol Neurosurg. 2015 Dec;139:295-301.
- Roussouly P, Nnadi C. Sagittal Plane Deformity: An overview of interpretation and Management. Eur Spine J. 2010: 19:1824-1836
- Good C, Auerback JD, O'Leary PT, Schuler TC. Adult Spine Deformity. Curr Rev Musculoskelet Med. 2011: 4:159-167
- Ailon T, Smith JS, Chaffrey CI, Lanke LG, Brodke D, Harrop JS, Fehlings M, Ames CP. Degenerative Spinal Deformity. Neurosurgery. 2015 Oct . 77: S75-91.
- Ailon T, Chaffrey CI, Lanke LG, Harrop JS, Smith JS. Progressive Spinal Kyphosis in the Aging Population. Neurosurgery. 2015 Oct; 77 S164-72
- Lenke LG, Edwards CC2nd, Bridwell KH. The Lenke Classification of Adolescent Idiopathic Scolioisis: How it Organizes Curve Patterns as a Template to Perform Selective Fusions of the Spine. 2003 Oct. Spine. 15;28:S199-207

BIOMECHANICS OF THE DEFORMED SPINE

Biomechanics of the Deformed Spine

- Spinal deformities result from one or more unstable segments
- Pathologic stressors to a normal spine
- Non-pathologic stressors to deformed spine
- Often more than one type

Biomechanics of the Deformed Spine

- Consider forces on the spine by evaluating component vectors
- Vector: force oriented in a fixed and defined direction in three dimensional space
- When a vector acts on a lever, creates a bending moment

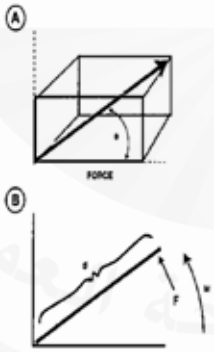

Biomechanics of the Deformed Spine

- Bending moment
  - Torque applied by a circular force
  - Bending moment applied to a point causes rotation around an axis
  - Bending moment=Force of lever arm x distance

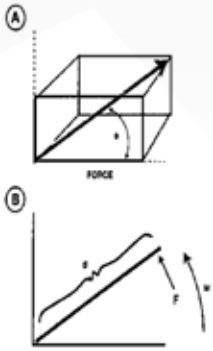

Biomechanics of the Deformed Spine

- Motion segment
  - Two adjacent vertebrae
  - Intervertebral disc
  - Zygapophsyseal joint
  - Allows for movement in
    - Flexion-extension
    - Lateral Flexion
    - Axial Rotation

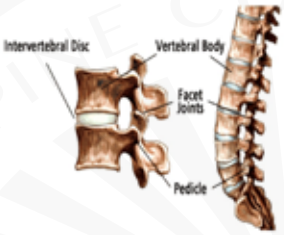

Biomechanics of the Deformed Spine

- Motion segment
  - Anterior column
    - Anterior longitudinal ligamen
    - Anterior 2/3 of vertebral body
  - Middle column
    - Posterior longitudinal ligament
    - Posterior 1/3 of vertebral body and annulus
  - Posterior column
    - Pedicles
    - Facets
    - Ligamentum flavum
    - Spinous process

Biomechanics of the Deformed Spine

- Overall movements of the spine
  - Sum of small motions within each motion segment

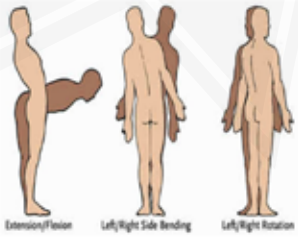

Biomechanics of the Deformed Spine

- Force vectors in three dimensional space
- Three axes of the spine: long axis, coronal axis, translational axis
- Two types of movements – rotation and translation
- Six fundamental segmental movements of the spine

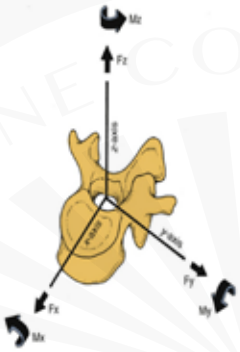

Biomechanics of the Deformed Spine

- Rotational Deformation
  - Apply a bending moment on a spinal segment
  - Angular deformation
  - Can occur along one of both of the axially oriented axes (coronal or sagittal)
  - Deformities can occur at the level of the vertebral body, or the disc space

Biomechanics of the Deformed Spine

- Rotational Deformation
  - Kyphosis – flexion rotation deformation
  - Lordosis – extension rotation deformation
  - Scoliosis – lateral bending deformation
  - Rotatory deformation along the long axis
  - Combination

Biomechanics of the Deformed Spine

- Translational Deformation
  - Shearing
    - Fracture dislocation or spodylolisthesis
  - Compression
    - Burst Fractures
  - Distraction
    - Uncommon (spinal traction, implant-induced)

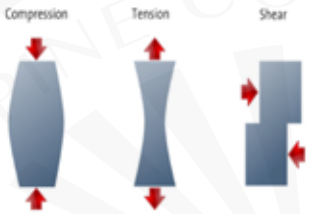

Biomechanics of the Deformed Spine

- Three main categories of spinal deformity
  - Sagittal
  - Coronal
  - Axial
- Coupling phenomenon
  - Deformity that occurs on one axis often produces another motion along or around another

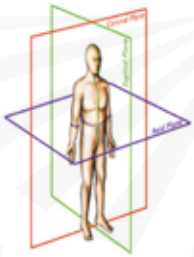

Biomechanics of the Deformed Spine

- Coronal Plane
  - Cobb Angle
  - Measured from the rostral and caudal vertebrae with greatest curve
    - Some inter-rater variability
  - As Cobb angle increases
    - Increased moment arm applied
    - Greater bending moment

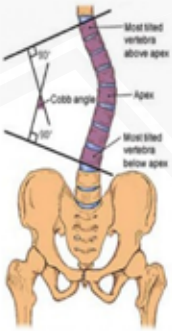

Biomechanics of the Deformed Spine

- Sagittal plane
  - C7 vertebral body usually in alignment with S1
  - Positive correlation between thoracic kyphosis and lumbar lordosis
  - Plumb line from center of C7 vertebral body lies within 2cm of sacral promontory
  - As individual ages, line can move forward

Biomechanics of the Deformed Spine

- Sagittal plane
  - Cervical lordosis
  - Thoracic kyphosis
  - Lumbar lordosis
- Negative Sagittal Balance
  - Lumbar hyperlordosis
  - Axis is posterior to the sacrum
- Positive Sagittal Balance
  - Flat-back syndrome
  - Kyphosis
  - Axis is anterior to the sacrum

Biomechanics of the Deformed Spine

- Site specific considerations
  - Upper cervical spine
    - High degree of mobility
    - Deformities in all planes
  - Lower cervical spine
    - Coronal plane deformity less common
    - Sagittal plane more common
      - Degenerative loss of disc height and reduction in height of vertebral bodies
      - Moment arm increases, promotes further deformity

Biomechanics of the Deformed Spine

- Site specific considerations
  - Cervicothoracic junction
    - Shift from mobile cervical spine to less mobile thoracic spine
    - Biomechanics change significantly
  - Thoracic spine
    - Larger verterbal bodies anchored by the rib cage
      - Coupling: Scoliosis associated with rotation
      - Scoliotic curves rotate the spinous processes toward the concave side of curve

Biomechanics of the Deformed Spine

- Site specific considerations
  - Lumbar spine
    - Many have translational component in addition to rotational component
    - Anterolisthesis
    - Can alter sagittal balance

Biomechanics of the Deformed Spine

- Summary
- Spinal deformities result from one or more unstable segments
- Consider forces on the spine by evaluating component vectors
- Sagittal, coronal, axial planes
- Translation and rotation
- Coupling effect

Biomechanics of the Deformed Spine

- References

- Schlenk RP, Kowalski RJ, Benzel EC. Biomechanics of Spinal Deformity. Neurosurg Focus. 2003: Vol 14, Art 2
- Le Heuc JC, Saddiki R, Franke J, Rigal J, Aunoble S. Equilibrium of the Human Body and the Gravity Line: the Basics. 2011: Eur Spine J 20:5558-5563
- Diebo BG, Varghese JJ, Lafage R, Schwab FJ, Lafage V. Sagittal Alignment of the Spine: What do you Need to Know? Clin Neurol Neurosurg. 2015 Dec;139:295-301.
- Abel MF, Shaffery CI, et al: Pediatric spinal deformities, in Benzel EC (ed): Spine Surgery: Techniques, Complication Avoidance, and Management. New York: Churchill Livingstone, 1999, pp 565-610
- Stokes IAF. Three-Dimensional Terminology of Spinal Deformity: A Report Presented to the Scoliosis Research Society by The Scoliosis Research Society Working Group on 3-D Terminology of Spinal Deformity. Spine. 1994: Jan. Vol 19, Issue 2

ADOLESCENT IDIOPATHIC SCOLIOSIS: NATURAL HISTORY AND CLASSIFICATION

Adolescent idiopathic scoliosis

Epidemiology

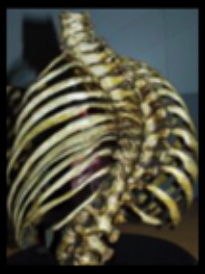

Scoliosis (curve greater than 10°) affects about 2 - 3% of the United States population (about 6 million people). require active treatment.

Adolescent idiopathic scoliosis

Natural History

All treatments must alter natural history in a positive way

Adolescent idiopathic scoliosis

Natural History

- Curve progression
- Back Pain
- Pulmonary Function
- Mortality
- Psychological effects of scoliosis

Adolescent idiopathic scoliosis

Natural History

- Curve progression
- Back Pain
- Pulmonary Function
- Mortality
- Psychological effects of scoliosis

Adolescent idiopathic scoliosis

Curve progression

Most treatment decisions are generally made on the basis of curve progression

Adolescent idiopathic scoliosis

Curve progression

Six factors have been determined to influence the probability of progression in the skeletally immature patient.

Adolescent idiopathic scoliosis

In the immature patient, the risk of progression is related primarily to :

- Curve-specific factors: *Two are curve-related parameters*
- Growth potential: *Four factors are related to growth*

Adolescent idiopathic scoliosis

Curve-specific factors

Curve patterns

1) Thoracic.
2) Thoraco-lumbar.
4) Lumbar.
5) Doublemajor

Adolescent idiopathic scoliosis

Curve-specific factors

The curve-specific factors are that double curve patterns have a greater tendency to progress than single curve patterns

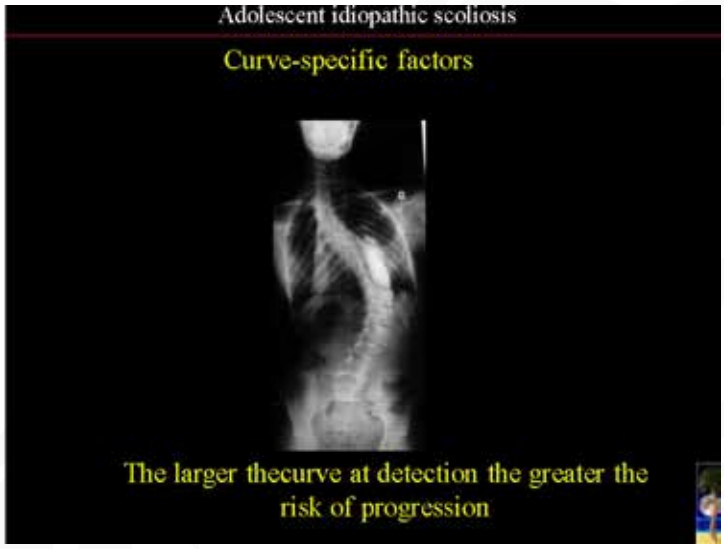
Adolescent idiopathic scoliosis
Curve-specific factors
The larger thecurve at detection the greater the risk of progression

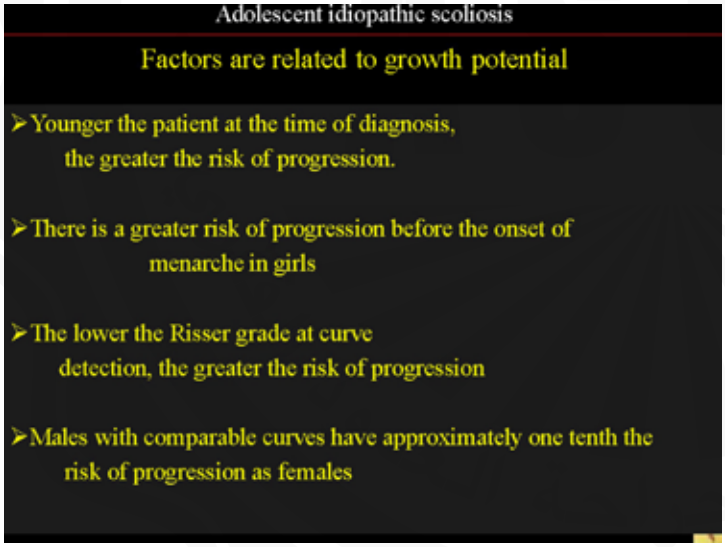
Adolescent idiopathic scoliosis
Factors are related to growth potential
➢Younger the patient at the time of diagnosis, the greater the risk of progression.
➢There is a greater risk of progression before the onset of menarche in girls
➢The lower the Risser grade at curve detection, the greater the risk of progression
➢Males with comparable curves have approximately one tenth the risk of progression as females

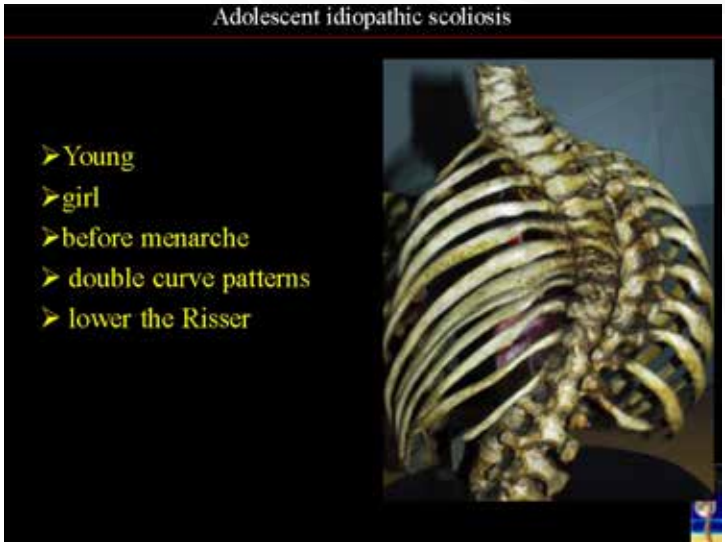
Adolescent idiopathic scoliosis
➢Young
➢girl
➢before menarche
➢ double curve patterns
➢ lower the Risser

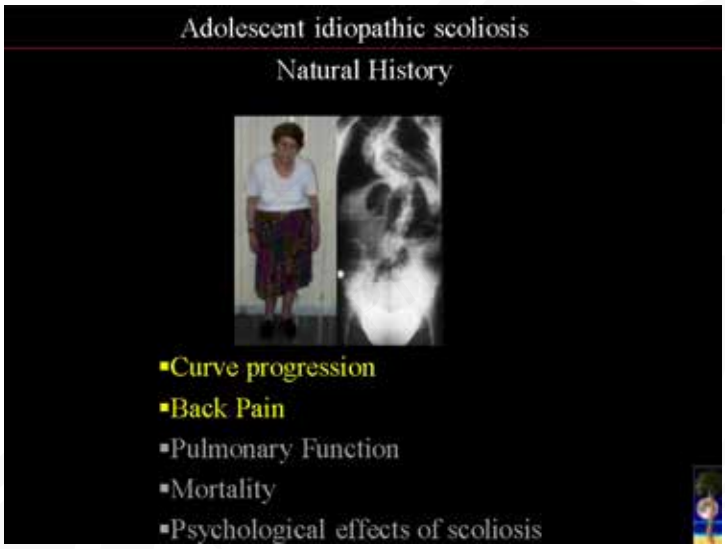
Adolescent idiopathic scoliosis
Natural History
▪Curve progression
▪Back Pain
▪Pulmonary Function
▪Mortality
▪Psychological effects of scoliosis

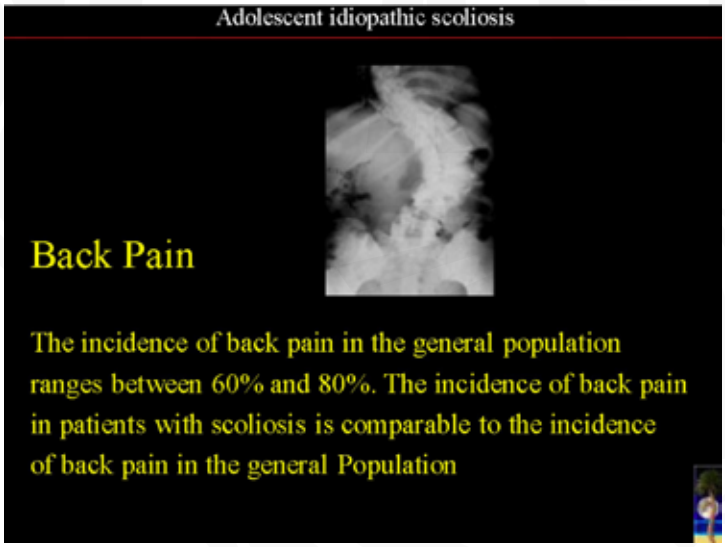
Adolescent idiopathic scoliosis
Back Pain
The incidence of back pain in the general population ranges between 60% and 80%. The incidence of back pain in patients with scoliosis is comparable to the incidence of back pain in the general Population

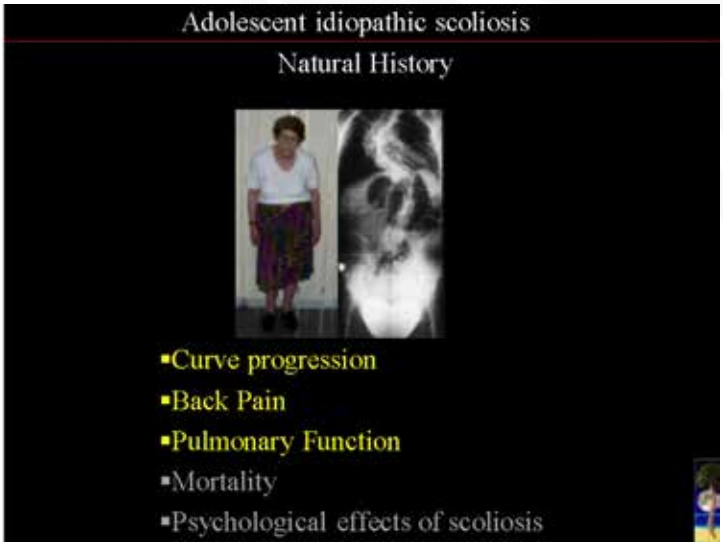
Adolescent idiopathic scoliosis
Natural History
▪Curve progression
▪Back Pain
▪Pulmonary Function
▪Mortality
▪Psychological effects of scoliosis

Adolescent idiopathic scoliosis

Pulmonary Function

Findings in pulmonary function studies in patients with untreated AIS demonstrate that only in patients with thoracic curves is there a direct correlation between decreased pulmonary function and increasing curve severity

The pattern of pulmonary disease in affected patients is, uniformly, restrictive lung **disease.**.

Adolescent idiopathic scoliosis

Pulmonary Function

Results in most studies show that significant limitations of forced vital capacity (FVC) in nonsmokers do not occur until the curve approaches 100–120°. However, the presence of thoracic hypokyphosis increases the loss of pulmonary function

.

Adolescent idiopathic scoliosis

Natural History

- Curve progression
- Back Pain
- Pulmonary Function
- Mortality
- Psychological effects of scoliosis

Adolescent idiopathic scoliosis

Mortality

The mortality rate for AIS is comparable to that of the general populationIn AIS, only patients with high-angle thoracic curves of more than 100° are at increased risk of deat pulmonale and right ventricular failure.

Visscher W, Lonstein JE, Hoffman DA, et al. Reproductive outcomes in scoliosis patients. Spine 1988

Adolescent idiopathic scoliosis

Mortality

In the Iowa 40- year long-term study, the mortality rate was 15%, and in only one case was cor pulmonale secondary to scoliosis implicated as the cause of death.

Adolescent idiopathic scoliosis

Natural History

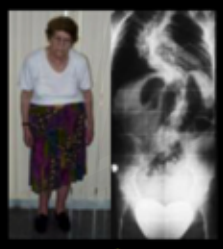

- Curve progression
- Back Pain
- Pulmonary Function
- Mortality
- Psychological effects of scoliosis

Adolescent idiopathic scoliosis

Psychosocial Effects

Psychological effects of scoliosis appear to be better tolerated b
middle-aged patients than by teenagers patient's cosmetic appea

This limitation is often expressed as
buying clothing to try to hide the deformity

Weinstein SL, Zavala DC, Ponseti IV. Idiopathic scoliosis: Long-term follow-up and prognosis in untreated patients. J Bone Joint Surg [Am] 1981

Adolescent idiopathic scoliosis

Classification

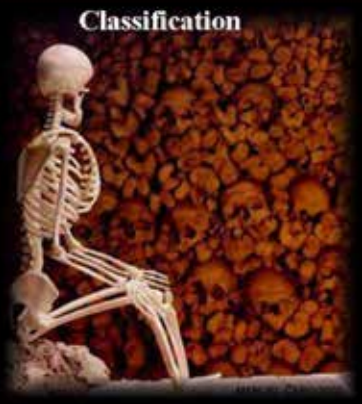

The purpose of a classification in A.S. is to provide prognosis regarding the natural history of the deformity
and to provide a guide for the optimal treatment of the deformity

Adolescent idiopathic scoliosis

Classification by the location of the deformity

Schulthess 1905

1) Cervico-thoracic.
2) Thoracic.
3) Thoraco-lumbar.
4) Lumbar.
5) Double.

The limitations of this Classification system are that it provides little guidance for treatment.

Adolescent idiopathic scoliosis

Terminology Committee of the Scoliosis Research Society in 1969.

The classification was etiological and divided disorders of the spine into categories including

- Idiopathic
- Congenital
- Neuromuscular
- Mesenchymal
- Traumatic

Goldstein LA, Waugh TR. Classification and terminology of scoliosis. ClinOrthop 1973;93:10–22

Adolescent idiopathic scoliosis

Terminology Committee of the Scoliosis Research Society in 1969.

The classification was etiological and divided disorders of the spine into categories including

- Idiopathic
- Congenital
- Neuromuscular
- Mesenchymal
- Traumatic

this classification is useful to lend insight into diagnosis and associated comorbidities but it provides little guidance for treatment.

Adolescent idiopathic scoliosis

CLASIFICACION

HA King 1983



In 1983, King et al introduced a classification system that was intended to provide guidance for treatment of the deformity

Adolescent idiopathic scoliosis
King classification
King classification has significant limitations,including applicability to current segmental instrumentation systems,and recognition of deformity in the sagittal plane.
Halm H,, et al. Sagittal plane correction in 'Kingclassified' Acta Orthop Belg 1995

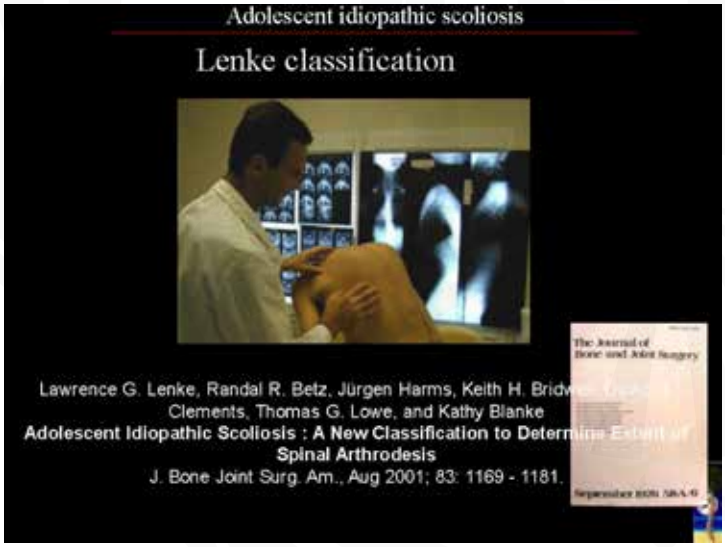
Adolescent idiopathic scoliosis
Lenke classification
Lawrence G. Lenke, Randal R. Betz, Jürgen Harms, Keith H. Bridwell, David
Clements, Thomas G. Lowe, and Kathy Blanke
Adolescent Idiopathic Scoliosis : A New Classification to Determine Extent of Spinal Arthrodesis
J. Bone Joint Surg. Am., Aug 2001; 83: 1169 - 1181.

Adolescent idiopathic scoliosis
2001 Lenke classification
The Lenke classification
provides a standardized and useful framework for determining
the extent of spinal arthrodesis in deformity by evaluating curves
in both coronal as well sagittal plane alignment
Lawrence G. Lenke, Randal R. Betz, J. Bone Joint Surg Am, Aug 2001.

Adolescent idiopathic scoliosis

The Lenke classification system is designed to allow surgeons to plan operative treatment based on this curve classification

Adolescent idiopathic scoliosis

Lenke classification

The general principle of the system is that the major curve and structural minor curves should be fused and that nonstructural minor curves may be allowed to correct spontaneously following fusion of the structural curves.

Adolescent idiopathic scoliosis

Description of 6 Lenke Curve Types

Curve type				
1	Nonstructural	Structural	Nonstructural	Main thoracic 51%
2	Structural	Structural	Nonstructural	Double thoracic 20%
3	Nonstructural	Structural	Structural	Double major 11%
4	Structural	Structural	Structural	Triple major 3%
5	Nonstructural	Nonstructural	Structural	Thoracolumbar/lumbar 12%
6	Nonstructural	Structural	Structural	Tho/lumbar–main thoracic 3%

The type 1 (single thoracic) curve is the most common

Adolescent idiopathic scoliosis

Lenke classification

New two-dimensional classification of adolescent idiopathic

- Coronal plane First the specific curve type (1-6)
- Sagittal plane (+ N,-)
- Lumbar spine modifier (A, B, or C)

Adolescent idiopathic scoliosis

Lenke classification

- Coronal plane First the specific curve type (1-6)

CURVE TYPE				
Type	Proximal Thoracic	Main Thoracic	Thoracolumbar/Lumbar	Description
1	Non-Structural	Structural (Major)*	Non-Structural	Main Thoracic (MT)
2	Structural	Structural (Major)*	Non-Structural	Double Thoracic (DT)
3	Non-Structural	Structural (Major)*	Structural	Double Major (DM)
4	Structural	Structural (Major)*	Structural (Major)*	Triple Major (TM)[2]
5	Non-Structural	Non-Structural	Structural (Major)*	Thoracolumbar/Lumbar (TL/L)
6	Non-Structural	Structural	Structural (Major)*	Thoracolumbar/Lumbar-Main Thoracic (TL/L-MT)

Adolescent idiopathic scoliosis

Lenke classification

•Sagittal plane (+ N,-)

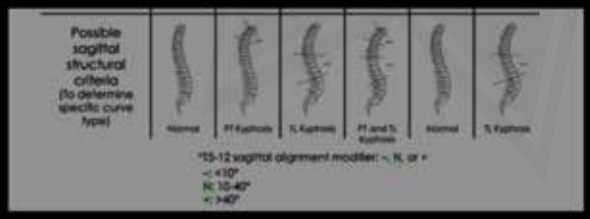

Adolescent idiopathic scoliosis

Lenke classification

Thoracic Sagittal Profile T5-T12	
- (Hypo)	< 10°
N (Normal)	10° - 40°
+ (Hyper)	> 40°

Thoracic Sagittal Modifier (-, N, +)

Adolescent idiopathic scoliosis

Lenke classification

Lumbar spine modifier (A, B, or C)

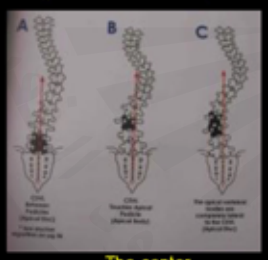

. The center sacral vertical line is extended in a cephalad direction, and the most cephalad lumbar or thoracic vertebra most closely bisected by the line is considered the stable vertebra.

Adolescent idiopathic scoliosis

Lenke classification.

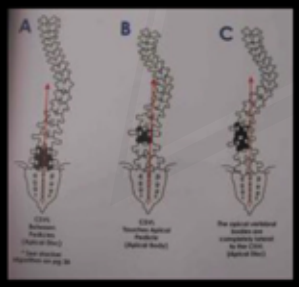

Three types of lumbar deformity were defined on the basis of the relationship of the center sacral vertical line to the lumbar curve as noted on the coronal radiograph

Adolescent idiopathic scoliosis

Lenke classification.

Criterios de curvas estructuradas

*Major = Largest Cobb measurement, always structural
Minor = All other curves with structural criteria applied
†Type 4 - MT or TL/L can be major curve

Structural curves, described by their location, lack normal flexibility and are termed as major (if they have the largest Cobb measurement) or minor. Minor curves can be structural or nonstructural.

Adolescent idiopathic scoliosis

Lenke classification.

Criterios de curvas estructuradas

*Major = Largest Cobb measurement, always structural
Minor = All other curves with structural criteria applied
†Type 4 - MT or TL/L can be major curve

STRUCTURAL CRITERIA
(Minor Curves)

Proximal Thoracic	- Side Bending Cobb ≥ 25° - T2-T5 Kyphosis ≥ +20°
Main Thoracic	- Side Bending Cobb ≥ 25° - T10-L2 Kyphosis ≥ +20°
Thoracolumbar/Lumbar	- Side Bending Cobb ≥ 25° - T10-L2 Kyphosis ≥ +20°

Adolescent idiopathic scoliosis

Lenke classification.

Criterios de curvas estructuradas

STRUCTURAL CRITERIA
(Minor Curves)

Proximal Thoracic	- Side Bending Cobb ≥ 25° - T2-T5 Kyphosis ≥ +20°
Main Thoracic	- Side Bending Cobb ≥ 25° - T10-L2 Kyphosis ≥ +20°
Thoracolumbar/Lumbar	- Side Bending Cobb ≥ 25° - T10-L2 Kyphosis ≥ +20°

On the basis of this classification, we propose that spinal arthrodesis include only the major curve and structural minor curves.

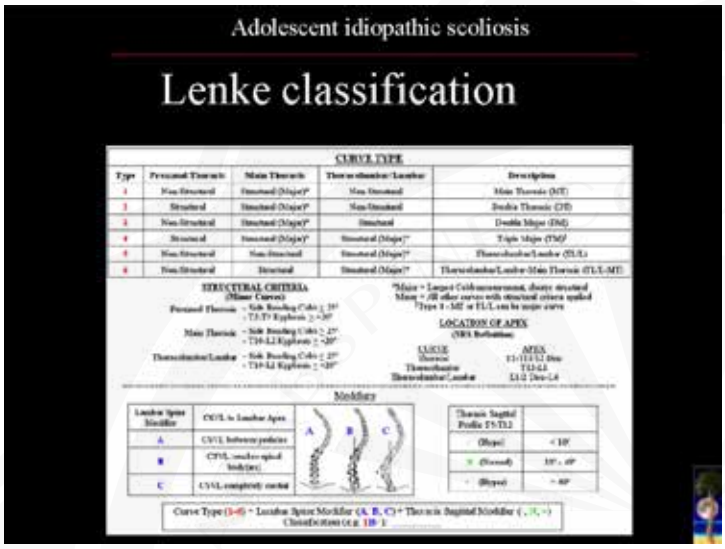
Adolescent idiopathic scoliosis
Lenke classification
CURVE TYPE
STRUCTURAL CRITERIA
LOCATION OF APEX
Modifiers

ADOLESCENT IDIOPATHIC SCOLIOSIS
This system provided for analysis of all AIS curves
and addressed coronal and sagittal plane deformities. Evaluation requires
upright long-cassette coronal and lateral radiographs as well as side-bending

ADULT SCOLIOSIS: NATURAL HISTORY AND CLASSIFICATION

Adult Scoliosis

"Spinal deformity in a skeletally mature patient with a Cobb angle of more than 10° in the coronal plane"

Aebi, Eur Spine J, 2005

Adult Scoliosis

- Prevalence varies widely but is high (1.4 – 68%)
- Increasing

Robin et al, Spine, 1982
Schwab et al, Spine, 2005

- Increases with age

Kobayashi et al, Spine, 2006

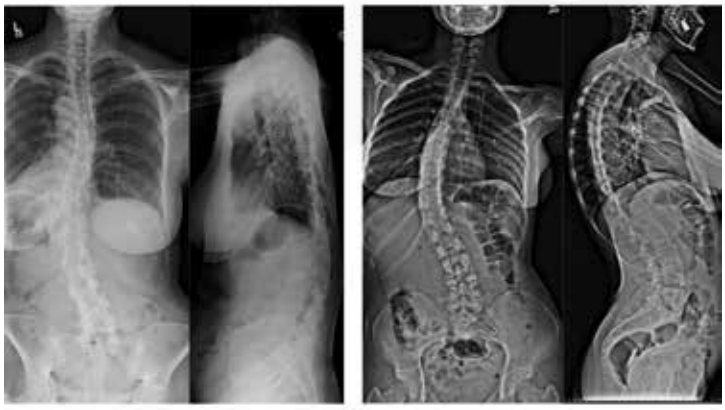

Aebi, Eur Spine J, 2005

Adult Idiopathic Scoliosis

- Pathophysiology- multifactorial
- Goal of treatment- prevent progression of deformity

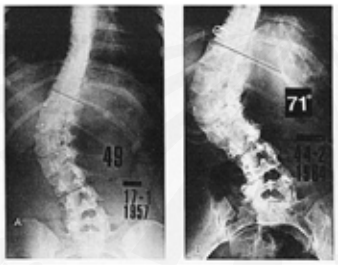

Ascani et al, Spine, 1986

Natural History: Idiopathic

Nachemson, Acta Orth, 1968
Nilsonne et al, Acta Orth, 1968
Fowles, Clin Orthop, 1978
Ascani et al, Spine, 1986

Weinstein et al, JBJS 1981
Weinstein et al, JBJBS 1983
Weinstein et al, JAMA, 2003

Adult Degenerative Scoliosis

- Asymmetric disc degeneration, rotatory subluxation, spondylolisthesis
- Self-perpetuates
- Stenosis

Natural History "De Novo" Scoliosis

- Radiographic?
- HRQOL?
- Treatment?

Radiographic

- 46% increased ≥4°
- 20% pain complaints required treatment

Robin et al, Spine, 1982

- 41 patients 10 year follow-up, 73% progressed
- Risk factors?

Pritchett and Bortel, Spine, 1993

Risk Factors

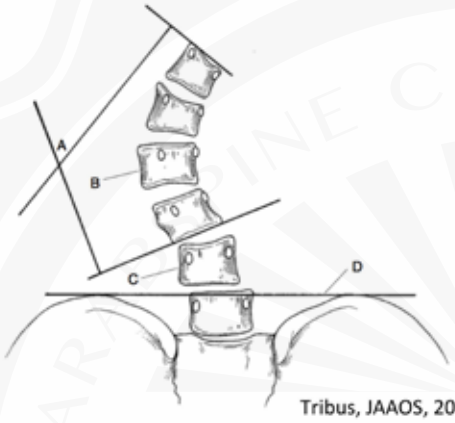

Tribus, JAAOS, 2003

- Pain and disability drive treatment decisions

Bess et al, Spine, 2009

- Back pain
- Neurogenic claudication and/or radicular pain

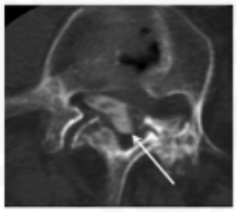

- Neurologic dysfunction
- Curve progression
- Cosmesis

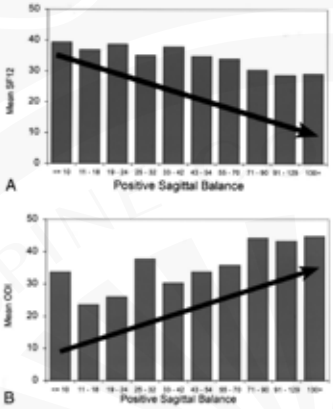

Glassman et al, Spine, 2005

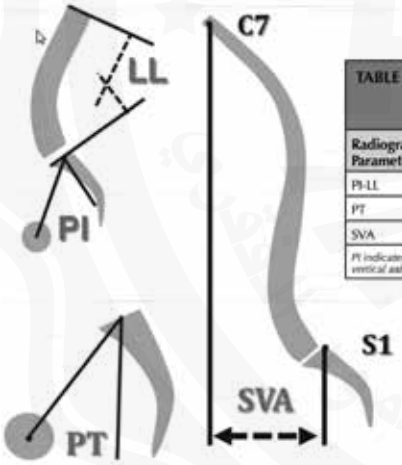

TABLE 1. Radiographic Parameter Thresholds Predictive of an Oswestry Disability Index Score of 40

Radiographical Parameter	Radiographical Threshold	r
PI-LL	11°	0.45
PT	22°	0.38
SVA	46 mm	0.47

PI indicates pelvic incidence; LL, lumbar lordosis; PT, pelvic tilt; SVA, sagittal vertical axis.

Schwab et al, Spine, 2012

Lafage, Spine, 2009

Classification

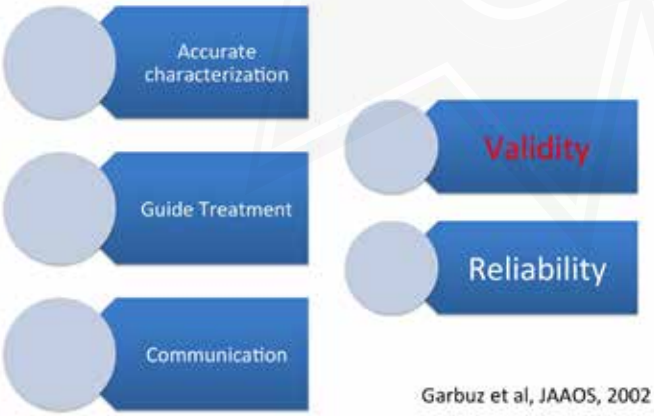

Garbuz et al, JAAOS, 2002

Primary curve types
- Single thoracic (ST)
- Double thoracic (DT)
- Double major (DM)
- Triple major (TM)
- Thoracolumbar (TL)
- Lumber "de novo"/idiopathic (L)
- Primary sagittal plane deformity (SP)

Adult spinal deformity modifiers

Regional sagittal modifier (include only if outside normal range as listed)
- (PT) Proximal thoracic (T2–T5): ≥ +20°
- (MT) Main thoracic (T5–T12): ≥ +50°
- (TL) Thoracolumbar (T10–L2): ≥ +20°
- (L) Lumbar (T12–S1): ≥ −40°

Lumber degenerative modifier (include only if present)
- (DDD) ↓ disc height and facet arthropathy based on x-ray include lowest involved level between L1 and S1
- (LIS) listhesis (rotational, lateral antero, retro) ≥3 mm include lowest level between L1 and L5
- (JCT) junctional L5–S1 curve ≥10° (intersection angle superior endplates L5 and S1)

Global balance modifier (include only if imbalance present)
- (SB) sagittal C7 plumb ≥5 cm anterior or posterior to sacral promontory
- (CB) coronal C7 plumb ≥3 cm right or left of CSVL

SRS definition of regions
- Thoracic: apex T2–T11–T12 disc
- Thoracolumbar: apex T12–L1
- Lumbar: apex L1–L2 disc–L4

Criteria for specific major curve types

1. Thoracic curves
   - Curve ≥40°
   - Apical vertebral body lateral to C7 plumbline
   - T1 rib or clavicle angle ≥10° upper thoracic curves
2. Thoracolumbar and lumbar curves
   - Curve ≥30°
   - Apical vertebral body lateral to CSVL
3. Primary sagittal plane deformity
   - No major coronal curve
   - One or more regional sagittal measurements (PT, MT, TL, L) outside normal range

Lowe et al, Spine, 2006

Schwab Classification

- Curve type
  - I: Thoracic only
  - II: Upper thoracic major (T4-8)
  - III: Lower thoracic major (T9-10)
  - IV: Thoracolumbar (T11-L1)
  - V: Lumbar (L2-4)
- Lordosis modifier (A, B, C)
- Subluxation modifier (0, +, ++)

Schwab, Spine, 2006

Schwab Classification

- IV, V curves – lumbar lordosis and subluxation mattered
- Type I, II, III mostly idiopathic

- Higher surgical rate
  - Less lumbar lordosis
  - Higher subluxation
- Excellent reliability

Schwab et al, Spine, 2006

SRS-Schwab Classification

4 Coronal curves type

- T **Thoracic only** — With lumbar curve < 30°
- L **TL/lumbar only** — With thoracic curve <30°
- D **Double curve** — With at least one T and one TL/L, both >30°
- N **No coronal curve** — All coronal curves <30°

3 Sagittal modifiers

PI minus LL
- 0 : within 10°
- +: moderate 10°–20°
- ++ : marked >20°

Global alignment
- 0 : SVA < 4cm
- + : SVA 4 to 9.5cm
- ++ : SVA > 9.5cm

Pelvic tilt
- 0 : PT<20°
- + : PT 20°–30°
- ++ : PT>30°

Schwab et al, Spine, 2012

SRS-Schwab

- Validated (reliable)
  Schwab et al Spine 2012
- Relevant and responsive to clinical outcomes
  Smith et al Spine 2013
- TL and sagittal deformity worst disability
  Terran et al Neurosurgery 2013

Non-operative Treatment

- Aerobic exercise, Physical therapy, Medication, ESI, Metabolic bone disease, Orthoses, TENS, chiropractic, acupuncture

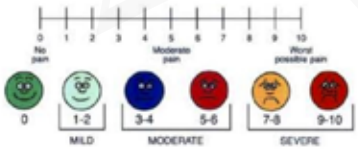

- HRQOL do not significantly improve
  Smith et al, Neurosurgery, 2015

Operative

- Careful patient selection, pre-operative planning, discussion of risks and benefits
- Regional, global, spinopelvic parameters
- Address stenosis

- Decompression
- Short segment
- Long segment
- Anterior/Posterior/ Circumferential
- Osteotomy

Outcomes?

- Smith et al, Neurosurgery, 2015
  - Significant improvements in ODI, SF-36, SRS
  - At least minimally clinical important difference threshold

- Yadla et al, Neurosurg Focus, 2010
  - 16 pt reduction in ODI
  - 23 pt decrease in SRS-30

Smith et al, Neurosurgery, 2015

Complications

- 20-52.2%

- Pseudarthrosis, wound infection, paresthesias, radiculopathy, CSF fistula, PE/DVT, MI, hardware failure, drug reaction, UTI, compression fracture, ARDS, high rate of revision, proximal junctional kyphosis

ISSG: Smith et al, JNS, 2016

- 291 patients
- 28.2% revision
- 270 perioperative complications in 52.2%
  - 145 minor
  - 125 major
- Implant related, radiographic, neurologic, operative, cardiopulmonary, infection
- Age, obesity, comorbidities, revision, osteotomy

- Aebi M: The adult scoliosis. **Eur Spine J** 14:925–948, 2005.
- Garbuz DS, Masri BA, Esdaile J, Duncan CP: Classification systems in orthopaedics. **J Am Acad Orthop Surg** 10:290–297, 2002.
- Glassman SD, Berven S, Bridwell K, Horton W, Dimar JR: Correlation of radi- ographic parameters and clinical symptoms in adult scoliosis. **Spine** 30:682–688, 2005.
- Lafage V, Schwab F, Patel A, et al. Pelvic tilt and truncal inclina- tion: two key radiographic parameters in the setting of adults with spinal deformity. *Spine (Phila Pa 1976)* 2009;34:E599– 606.
- Lowe T, Berven SH, Schwab FJ, Bridwell KH: The SRS classification for adult spinal deformity: Building on the King/Moe and Lenke classification systems. **Spine** 31:S119–S125, 2006.
- Robin GC, Span Y, Steinberg R, Makin M, Menczel J: Scoliosis in the elderly: A follow-up study . *Spine* 1982;7:355- 359.
- Schwab F, Dubey A, Gamez L, et al. Adult scoliosis: prevalence, SF-36, and nutritional parameters in an elderly volunteer population. *Spine (Phila Pa 1976)* 2005;30:1082–5.
- Schwab F, Farcy JP, Bridwell K, Berven S, Glassman S, Harrast J, Horton W: A clinical impact classification of scoliosis in the adult. **Spine** 31:2109–2114, 2006.
- Schwab F, Ungar B, Blondel B, et al. Scoliosis Research Society- Schwab adult spinal deformity classification: a validation study. **Spine** 2012;37:1077–82.

ADULT KYPHOSIS

- Sagittal balance is the balance between the normal sagittal curves of the spine to center the head on the pelvis with the least energy expenditure.

- Sagittal vertical axis (plumb line):

  -From center of C7 downwards.

  -Normally pass within 0.5 cm from the postero-superior aspect of S1.

  -Offset >2.5-4 cm ant. Or post. is abnormal.

- Sacropelvic parameters:

- Pelvic incidence (PI): (50°-60°)
- Sacral slope (SS)
- Pelvic tilt angle (PT)

"PI = SS+PT"

" Lumbar lordosis is greatly related to PI"

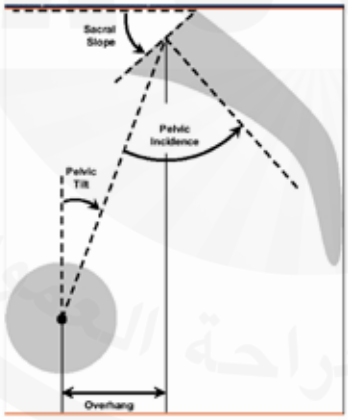

- Several authors have proposed a formula for the prediction of lumbar lordosis based on the pelvic incidence.

- The ideal lumbar lordosis based on the formula described by Legaye et al.: LL = ((PI × 0.5481 + 12.7) × 1.087 + 21.61).

- The ideal lumbar lordosis based on the formula described by Schwab et al.: LL = PI + 9.

- There are two types of spinal imbalance in the sagittal plane:

Type 1: segmental or regional imbalance in the sagittal plane of the spine but still has a balanced spine.

Type 2: global imbalance whereby the plumb line falls >5 cm in front of the L5-S1 disc.

Etiology

- Multi-level degenerative disc disease.
- Ankylosing spondylitis.
- Scheuermann disease.
- Iatrogenic flat back.
- Post-laminectomy kyphosis.
- Adjacent segment disease.
- Traumatic lesions (fractures).
- Destructive lesions (Tumors, infections).

Ankylosing Spondylitis :

Systemic chronic autoimmune spondyloarthropathy characterized by:

- HLA-B27 histocompatability complex positive (90%).
- RF negative (seronegative).
- Primarily affect axial spine.

Epidemiology:

- 4:1 male:female.
- Affects ~0.2% of Caucasian population.
- Usually presents in 3rd decade of life.
- Fewer than 10% of HLA-B27 positive patients have symptoms of AS.

Systemic manifestations:

- Acute anterior uveitis & iritis.
- Heart disease (cardiac conduction abnormalities).
- Pulmonary fibrosis.
- Renal amyloidosis.
- Ascending aortic conditions (aortitis, stenosis, regurgitation).

Orthopaedic manifestations:

- Bilateral sacroiliitis.
- Progressive spinal kyphotic deformity.
- Spine fractures.
- Large-joint arthritis (hip and shoulder).

Symptoms:

- Lumbosacral pain and stiffness: present in most patients and worse in morning.
- Neck and upper thoracic pain: occurs later in life.
- Acute pain should raise suspicion for fracture.
- Loss of horizontal gaze.
- Shortness of breath caused by costovertebral joint involvement, leading to reduced chest expansion.

Physical examination:

- Limitation of chest wall expansion: < 2cm of expansion is more specific than HLA-B27 for making diagnosis.
- Decreased spine motion: Schober test.
- Kyphotic spine deformity.

- Chin-brow-to-vertical angle (CBVA): useful for preoperative planning. Correction of this angle correlates with improved surgical outcomes.
- Hip flexion contracture.
- Sacroiliac provocative tests (Faber test): flexion abduction external rotation of the ipsilateral hip causes pain.

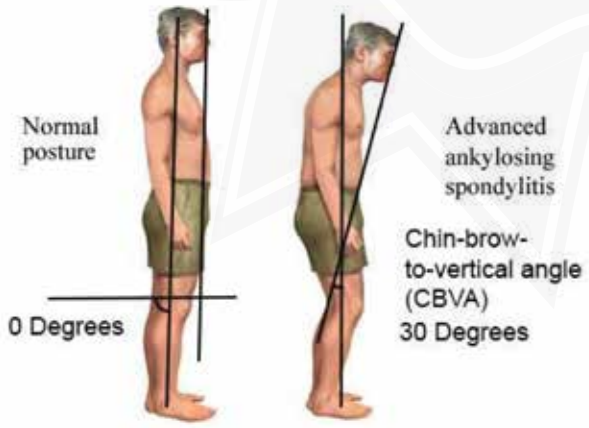

Radiographs:

Standing full-length AP and lateral views of spine.

- Squaring of vertebrae with vertical or marginal syndesmophytes.
- Late vertebral scalloping (bamboo spine).
- Negative in 50% of cases with spine fractures.
- Chin-brow to vertical angle.

Pelvis & lower extremity (Ferguson pelvic tilt view).

- Bilateral symmetric sacroiliac erosion:
  - Earliest radiographic sign is erosion of iliac side of sacroiliac joint.
  - Joint space narrowing.
  - Ankylosis.

R
20 cm

Fracture in Ankylosing spondylitis

A fracture of the spine in ankylosing spondylitis resembles a fracture of an osteoporotic tubular bone

- Most common site is **the cervico thoracic** junction followed by the cervical spine.
- Fractures usually occur **through the bodies** and less common through the **intervertebral disc**. It is usually **transverse**.
- Fractures run through **all the stabilizing structures** and ossified ligaments.
- It extends posteriorly to the **lamina** and may affect **multiple levels**.
- **Unstable** and very liable for **translation**. With high incidence of **neurological compromise.**
- Usually needs **anteroposterior stabilization**.



Scheuermann disease:

- Thoracic or thoracolumbar hyperkyphosis due to wedged vertebrae developing during adolescence

- Apprentice's kyphosis: detected mainly in youngsters involved in heavy labor
- Juvenile kyphosis
- Osteochondritis deformans juvenilis dorsi

- Incidence: 1-8 %
- Boys> Girls (2:1 – 7:1)

- Classical juvenile kyphosis, Type I
  - Typical wedging occurs usually in the thoracic spine but it may also cross the thoracolumbar junction & reach into the upper lumbar spine

- Lumbar "atypical" juvenile kyphosis, Type II
  - Occurs only in the lumbar spine up to the thoracolumbar junction
  - Endplate irregularities, disc narrowing, and increased sagittal diameter of the vertebral bodies without significant wedging

Diagnostic Criteria (Type I)

- Sorensen: wedging of > 5° in 3 consecutive vertebrae with endplate irregularities on a lateral radiograph
- Bradford:
  - Irregular vertebral endplates
  - Narrowing of the intervertebral disc space
  - One or more vertebrae wedged 5° or more in thoracic or thoracolumbar region
  - An increase of normal kyphosis beyond 40° (increased thoracic or thoracolumbar kyphosis)

Schmorl's nodes are often associated but are not a pathognomonic sign

Clinical Presentation

- History
  - Cardinal symptoms
    - Back pain
    - Cosmetic disturbance (progressive)
  - Presents around puberty as a prominence (increased rounding) of the thoracic or thoracolumbar spine
  - During adolescence: pain in the region of the kyphosis (apex/ intersacpular area)
    - During exercise
    - Prolonged sitting
  - In later adulthood: secondary cervical & lumbar hyperlordosis (facet joint stresses) → pain also in cervical and/or lumbar region
  - Family history

- Physical Examination
  - Rigid Hyperkyphosis (thoracic or TL)
    - Erect: increased thoracic kyphosis with sloping shoulders
    - Accompanied by compensatory hyperlordosis of the cervical and/or lumbar spine
    - Balanced in the coronal plane (mild 2ry scoliosis with minimal/ no rotation may be present)
    - Assess rigidity: Ask the patient to lift the head & extend the spine in the prone position
    - Remains noticeable with spine hyperextension
  - Muscles painful on palpation
  - Hamstring tightness (increased pelvic tilt related to the lumbar hyperlordosis)

  - Adam's forward bend test
    - Slight truncal asymmetry associated with mild scoliosis
    - Abrupt posterior angulation of thoracic spine
  - Neurological examination (findings v. rare)
    - Spastic paraparesis: cord compression from the severe angular deformities
    - Herniated disks at the apex of the deformity

- Distinguish juvenile kyphosis from idiopathic roundback. In the latter:
  - Hyperkyphosis is harmonic also in flexion
  - It corrects well in extension

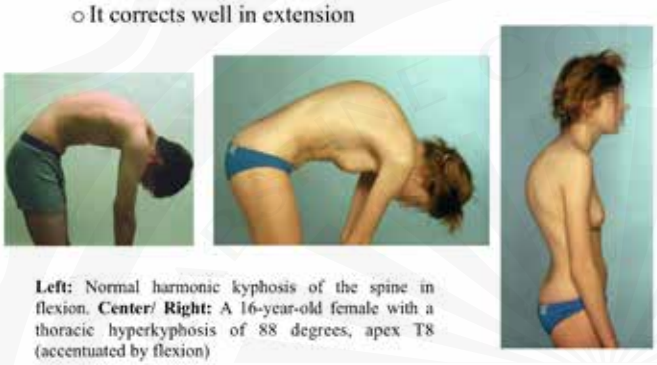

Left: Normal harmonic kyphosis of the spine in flexion. **Center/ Right:** A 16-year-old female with a thoracic hyperkyphosis of 88 degrees, apex T8 (accentuated by flexion)

Idiopathic thoracic hyperkyphosis ("roundback") in a 19-year-old male. Thoracic kyphosis is increased but harmonic in flexion. The patient suffers from thoracic back pain during prolonged standing and sitting. He is neurologically intact

On the standing lateral radiograph the thoracic kyphosis measures 66 degrees. There are no structural vertebral changes. On the supine extension radiograph, the kyphosis has corrected to 26 degrees. There are no pathologic changes on MRI.

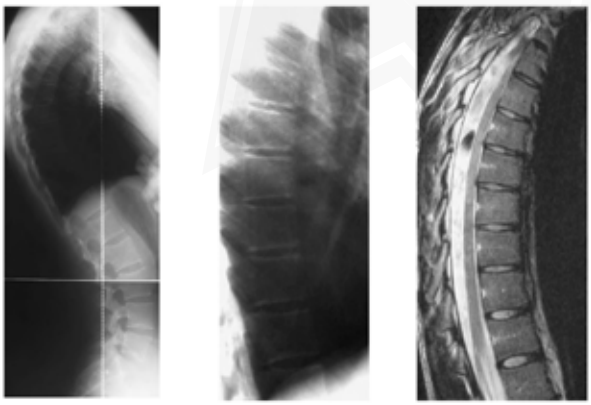

A 20-year-old male with a low thoracic hyperkyphosis of 79 degrees, apex T10

- Lumbar Scheuermann's disease
  - Progressive low back pain
    - Precludes involvement in athletic activity
    - More common
  - Prone to develop lumbar spinal stenosis
  - Radiating pain into the buttocks & lower extremities
  - Pain that awakens from sleep
  - Significant loss of the normal lumbar lordosis (flat back)
  - Flattened lumbar region is rigid
  - No scoliosis
  - Neurological examination normal

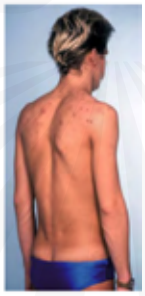

Diagnostic Studies

- Standard Radiographs
  - Juvenile kyphosis is diagnosed on standard radiographs
  - Plain lateral & PA radiographs of the whole spine with the patient in the standing position
  - Lateral projection: sharp hyperkyphosis of the thoracic spine with compensatory lumbar hyperlordosis

- Vertebrae around the apex of the thoracic kyphosis show typical radiographic changes
  - Irregularity of the endplates
  - Wedging of vertebral bodies
  - Increased length of vertebral bodies
  - Loss of disc space height
  - Schmorl's nodes (not pathognomonic)

- Thoracic kyphosis and lumbar lordosis are measured according to Cobb
- PA radiograph is checked for 2ry scoliosis
- Sagittal and frontal spinal balance is assessed

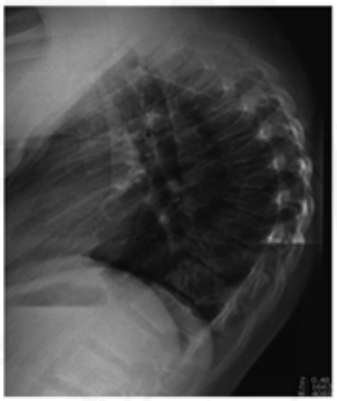

- Extension films of the kyphotic area with the patient in the supine position with a sandbag under the apex of the deformity to assess flexibility of the deformity
- The skeletal age & the remaining spinal growth determined from a radiograph of:
  - The hand and wrist
  - The pelvis (Risser sign)
  - For assessment of the risk of progression & treatment decision-making

- MRI
  - Wedge shape of the vertebral bodies
  - Premature degeneration of intervertebral discs
  - Schmorl's nodes
  - Spinal cord compression at the curve apex (in severe cases)

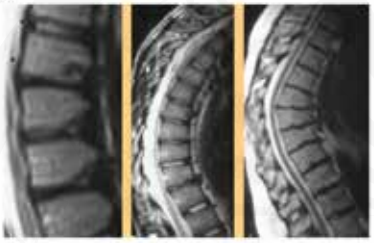

Natural History

- Benign in the majority of cases
- Pain: usually mild & rarely interfered with daily activities or professional career
- Cardiorespiratory problems: only in very severe deformities (kyphosis >100°)
- In kyphosis >70°: cosmetic impairment is considerable & clinical symptoms are more common → psychological distress
- Curve progression is not observed after the end of growth
- Neurological problems are rare and is usually correlated with a sharp-angled kyphosis

Treatment

Non operative:

- Exercise
  - Influences pain but not kyphosis
  - Strengthening paraspinal muscles.
  - Stretching abdominal & chest muscles.
- Bracing

- **Bracing :**
  - Indications:
    - Mobile kyphotic deformity >45°
    - Substantial remaining growth (>1 year)
  - Bracing and/or casting become ineffective once the patient's Risser sign is 4 or 5
  - Brace treatment is not effective for a shorter duration than 18 months

Operative Treatment

- Only absolute indication for surgery is neurological compromise
- Relative indications:
  - Kyphotic deformity >75°
  - Rapidly progressive severe curve
  - Persistent pain unresponsive to non-operative care

- Anterior release?
  - Anterior release is indicated only if bony bridges between the vertebrae are present or in kyphosis >100°

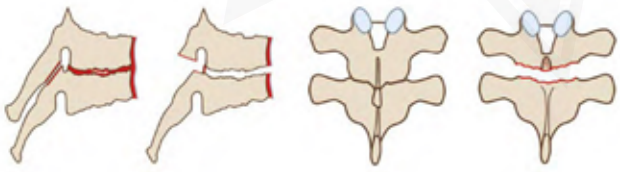

Structural changes to be addressed during surgery: anterior release: stiffness of intervertebral disc & anterior longitudinal ligament; posterior release: overgrowth of the posterior elements

- Levels included in fusion?
  - Proximally from the upper end-vertebra of the kyphosis (usually T2/ T3/ T4) down to the upper lumbar spine including the first lordotic disc space (usually L1/ L2/ L3)
- Target correction?
  - A kyphosis correction of >50% of its initial value should be avoided → risk of imbalance or junctional kyphosis
  - Correction to high "normal" kyphosis range of 40–50° seems to be advisable to avoid postoperative imbalance

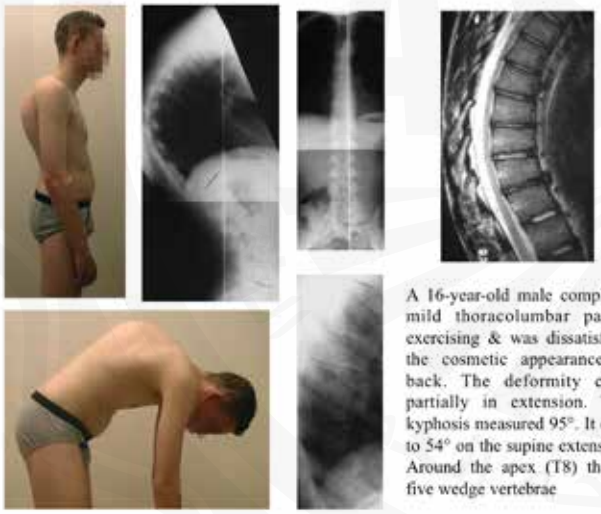

A 16-year-old male complained of mild thoracolumbar pain after exercising & was dissatisfied with the cosmetic appearance of his back. The deformity corrected partially in extension. Thoracic kyphosis measured 95°. It corrected to 54° on the supine extension film. Around the apex (T8) there were five wedge vertebrae

As the deformity was relatively mobile, brace treatment was considered. It was, however, discarded because of the minimal remaining spinal growth left (Risser 4, skeletal age 18 years). A posterior release, instrumentation/ correction using the two-rod cantilever tension band principle, and a posterior fusion fromT2 to L2were performed. On radiographs 6 months after operation, thoracic kyphosis measured 48 degrees

Female patient 13 yrs was dissatisfied with the cosmetic appearance of his back.

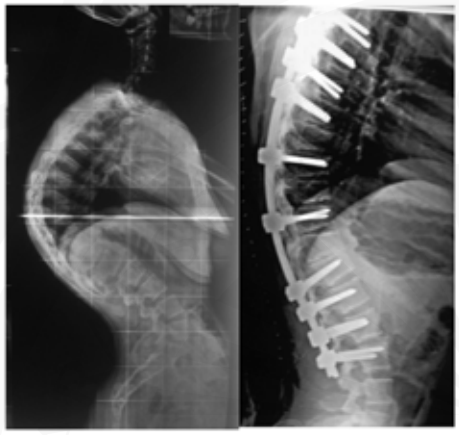

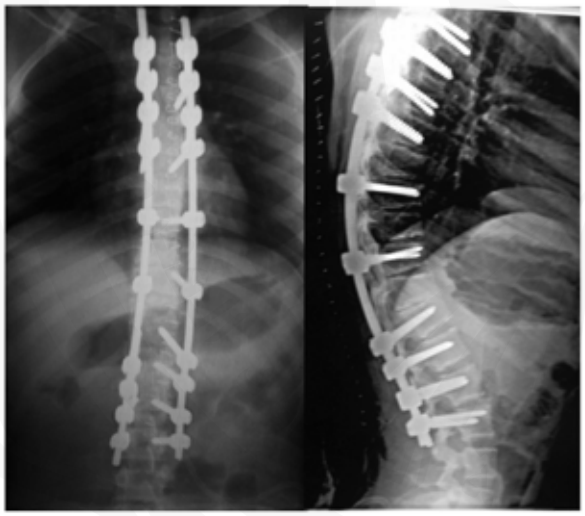

- Combined Anterior/Posterior Approach
  - Very rigid kyphosis (esp. in adults)
  - Through an anterior approach, resection in the area of deformity of:
    - Rib heads
    - Anterior longitudinal ligament,
    - Intervertebral discs down to the posterior longitudinal ligament
    - Cartilaginous vertebral endplates
  - The disc spaces are distracted and filled with bone graft (morcellized rib)
  - Thoracoscopic anterior release

- Postoperative junctional kyphosis

  3 possible mechanisms:

  - Fusion that is too short, distally stopping above the first lordotic disc → distal junctional kyphosis
  - Fusion that is too short proximally & does not include the whole kyphosis on the top → proximal junctional kyphosis & a goose neck appearance.
  - Overcorrection: should not correct the kyphosis to > 50% of its initial value

Iatrogenic flat back:

- Failure to restore the sagittal balance (lumbar lordosis).
- The most important predisposing factor of adjacent segment degeneration.
- Radiological parameter that most highly correlates with pain and disability is the balance between pelvic incidence and lumbar lordosis.

- Kumar et al, in 2000 showed that a lower incidence of adjacent level change was demonstrated in patients with a normal C7 plumb line alignment with normal sacral inclination, following lumbar spinal fusion.
- Marco Senteler et al, in 2014 reported that the rate of revision surgery for ASD was 24.4 % if PI-LL < 15° and 87.2 % if PI-LL ≥ 15°
- Yasuchika Aoki et al, in 2015 reported that greater PI-LL was significantly associated with worse post-operative VAS for LBP.

Female patient 80yrs

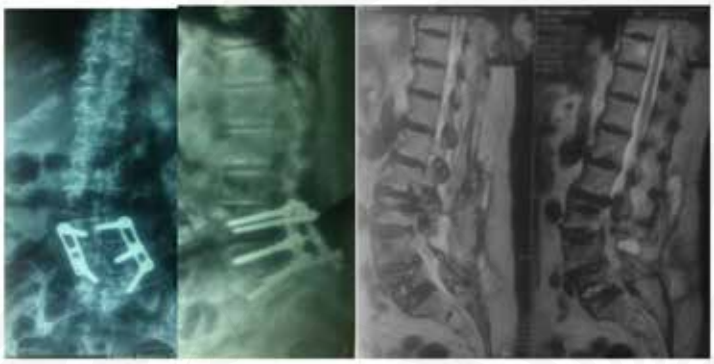

Female patient 78yrs

Sagittal imbalance cascade

Sagittal imbalance can be compensated by pelvic retroversion to maintain erect posture, resulting in a decreased sacral slope and increased pelvic tilt.

↓

This will put the femoral heads forward and the sacrum and the spine backwards

↓

The consequence of backward rotation of the pelvis is extension of the hips.

↓

The extension reserve will limit the amount of pelvic retroversion possible.

↓

This change may result in back muscle fatigue and exhaustion, with back pain in standing posture.

When pelvis backward rotation overpasses, the only solution to stand with horizontal eyes axes is to bend the knees in order to keep the gravity line between the two feet.

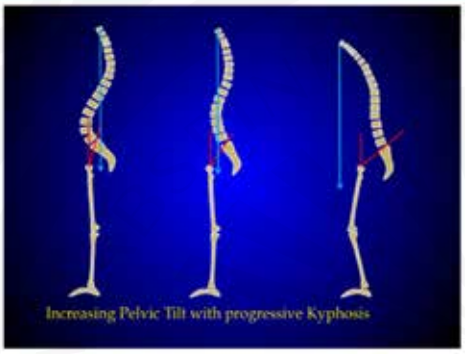

Post traumatic kyphosis

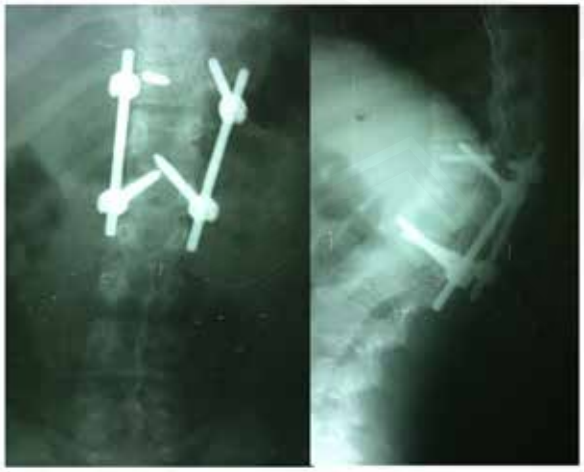

Age related hyperkyphosis

RISK FACTORS:

- Vertebral osteoporotic compression fractures.
- Degenerative Disc Disease.
- Spinal extensor muscle weakness.
- Age-related deficits in the somatosensory, visual, and vestibular systems likely contribute to the loss of upright postural control.
- Calcification and ossification of the anterior longitudinal ligament.

Complications:

- Mechanical restriction that can limit vital lung capacity.
- Impaired balance and increased risk of falling.
- Limitations in performing daily activities.

- **Bridwell classification of curves:**

  - Totally flexible
  - Partially flexible through mobile segments
  - Totally inflexible (rigid)

Surgical treatment of Flexible curves (Disc based deformities)

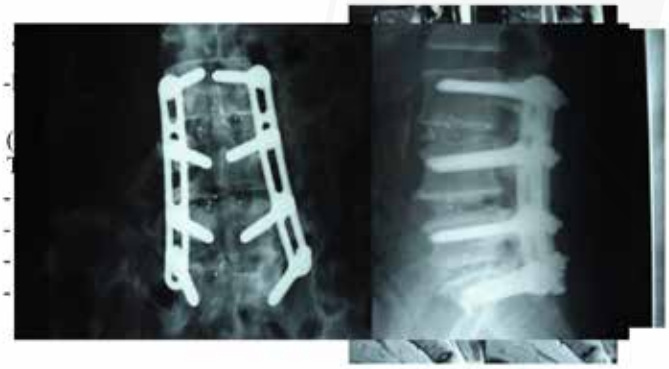

Surgical treatment of Rigid curves (osteotomies)

- Smith Peterson osteotomy.
- Pedicle subtraction osteotomy.
- Partial Pedicle subtraction osteotomy.
- Vertebral Column Resection.

CLINICAL ASSESSMENT IN DEFORMITY PATIENT

ARABSPINE COURSE DIPLOMA
ASCD
الدبلوم العربي لجراحة العمود الفقري

IMAGING IN SPINAL DEFORMITIES

Spine deformities
Core Slide

Imaging of spinal deformity

- Standard X-Rays imaging
  - Ortho PA and Lateral views
  - AP recumbent view of entire spine, cervical to sacral
- Dose reduction strategy
- Pelvic parameters
- Special X-Rays imaging
  - Lateral bending
  - Kiphosis reduction test
  - Oblique views
  - Hang up and traction
  - Stagnara image (planed election view) perpendicular to the true coronal plane of the apical vertebra

Spine deformities
Core Slide

Children

- PA view first exam.
  - From C3 to Hip joints
- LL view
  - From C2 to Hip joints
    - Jaw horizontal
    - Hands on clavicles
- PA view control
  - From C7 to iliac crest
    - Risser test
    - Dysmetria

Adults

- PA view
  - From C2 to Hip joints
- LL view
  - From acoustic foramen to the proximal femur
  - Jaw horizontal
  - Hands on clavicles
  - Sagittal balance

Spine deformities
Core Slide

Measuring the scoliosis

- Cobb angle
- Torsion and rotation
- Metha rib-vertebral angle
- Risser test
- Dysmetria

Spine deformities
Core Slide

Risser test

Spine deformities
Core Slide

Reducing radiation dose strategy

- PA view
- Reduced FOV
- **Lead protection for gonads and mammals**
- **Maximum positioning care to avoid repetitions**

Spine deformities
Core Slide

Special views

- Lateral bending
- AP supine
- Kyphosis reduction test

Spine deformities
Core Slide

Scoliosis

- 80% idiopatic
- congenital/osteogenic scoliosis secondary to vertebral anomalies,
- neuropathic scoliosis (in patients with syringomyelia, tethered cord, Chiari malformations, diastematomyelia, and meningocele/ myelomeningocele)
- neuromuscular scoliosis (in patients with cerebral palsy, spinocerebellar degeneration e.g. Friedreich ataxia, muscular dystrophy, and poliomyelitis).
- Tumours

The distinction between different types of scoliosis is important with respect to treatment and prognosis.

MRI (sedation)
CT (high dose poor information about cord defect)

Spine deformities
Core Slide

Radiographic criteria for identifyng the type of scoliosis

- curve length
- curve form
- location of the lower- end vertebra

can indicate the 3 most common types of scoliosis (idiopathic, neuromuscular/neuropathic, and congenital/ osteogenic).

JOrthSur 2010;18(1):1-5
Abul-Kasim and Ohlin Malmo, Sweden

Spine deformities
Core Slide

Scoliosis red flags:

- Pain
- Left thoracic curve
- Neurologic abnormalities
- kyphosis

Clinical exam plus CT,MR ...
Looking for pathology in the convex side of the curve or at the apex (Stagnara)

Spine deformities
Core Slide

Painful scoliosis

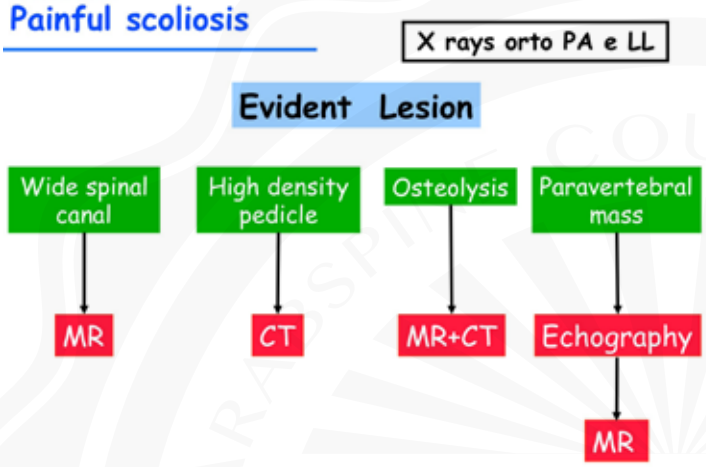

Spine deformities
Core Slide

Painful scoliosis

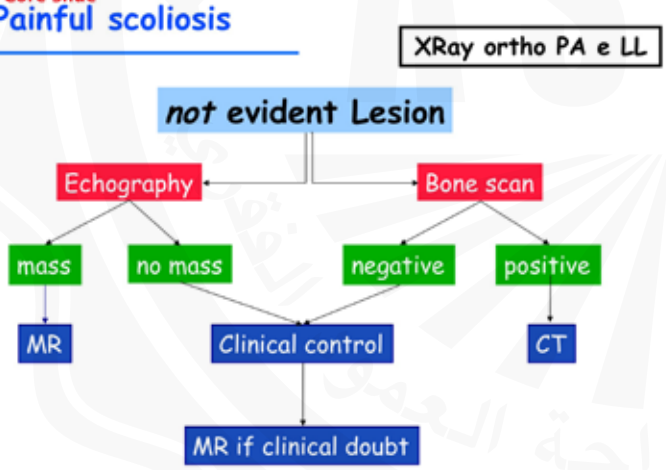

Spine deformities
Core Slide

CT and bone scan: bone assessment

- Total body bone scan 99mTc
  - Painful scoliosis with negative XRay
  - Tumours or infections.
- CT 2D and 3D reformation
  - High dose
  - Morphologic analysis in congenital scoliosis
  - Pedicles morphology and orientation
  - Screws, hooks and bars position

Spine deformities
Core Slide

Magnetic Resonance

- With neurologic symptoms or signs
- Left thoracic scoliosis (siringomielia)
- Tumours
- Hydromyelia, spinal-cord tumors, dysraphism, a tethered cord, diastematomyelia, lipomas, neurofibromas, Chiari malformations

Spine deformities
Core Slide

Key messages

- Different imaging for children and adults
- Dose reduction strategy
- Carefully analize the imaging
- Scoliosis red flags
- Sagittal balance

NEUROMUSCULAR DEFORMITIES: SCOLIOSIS AND KYPHOSIS

Neuromuscular Diseases

- Neurogenic or myogenic pathology that affect fonctionnal status of the patient:
  - Muscular weakness
  - Muscular tone abnomalities
  - Muscular dysfonction
  - Muscular contracture

Neuromuscular Diseases

- Neurogenic diseases
  - Central lesions (Brain)
  - Peripheric lesions
    - Medulla
    - Nerves
    - Nerve/Muscle Junction

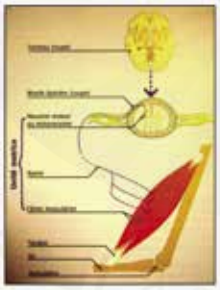

Neuromuscular Diseases

- Neurogenic diseases
  - Central lesions (Brain)= Cerebral Palsy

Neuromuscular Diseases

- Neurogenic diseases
  - Peripheric lesions
    - Medulla (Spinal Muscular Atrophy, Spina Bifida, acute anterior poliomyelitis)
    - Nerves (motor and sensory peripheral neuropathy)
    - Nerve-muscle Junction (Myasthenia)

Neuromuscular Diseases

- Myogenic diseases : Muscular Dystrophies (Congenital Muscular Dystrophies, Duchenne Dystrophie, Ullrich, Steinert, etc.)

Physiopathology

- Normal Biomechanic of the Spine need
  - Shrouds for the spine
  - Good balance position
  - Symmetrical growth
  - Stable pelvic base
  - Spinothoracic complex

Physiopathology

- Causes of spinal deformities
  - Muscle weakness, paralysis
  - Asymmetrical muscle activity
  - Asymmetrical muscle contractures
  - Impact on bone growth

Types of deformity

- The « Pelvic Vertebra »
  - Obliquity in the 3 dimensions
  - Regular or opposite
  - Supra or infra pelvic

Types of deformity

- Kyphoscoliosis
- Lordoscoliosis
- Hyper kyphosis
- Hyper lordosis

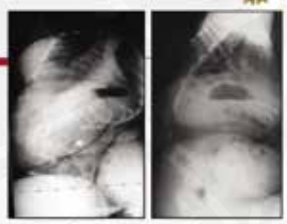

Functionnal evaluation
Ambulation
Standing
Sitting alone
Pelvic obliquity
Head control

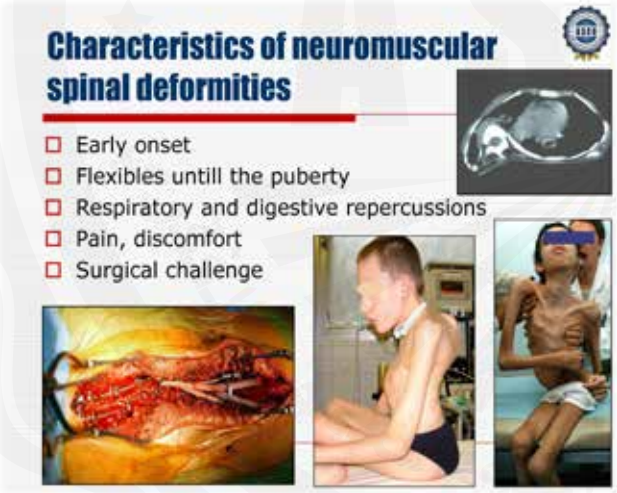
Characteristics of neuromuscular spinal deformities
Early onset
Flexibles untill the puberty
Respiratory and digestive repercussions
Pain, discomfort
Surgical challenge

CONGENITAL MALFORMATIONS ASSOCIATED TO SPINAL DEFORMITIES

Scoliosis surgery

Neurological risk 0.3 – 1.4%
Underestimate associated neural axis abnormalities
Operative risk

Preoperative assessment
(identify associated neural abnormalities)
Intraoperative monitoring

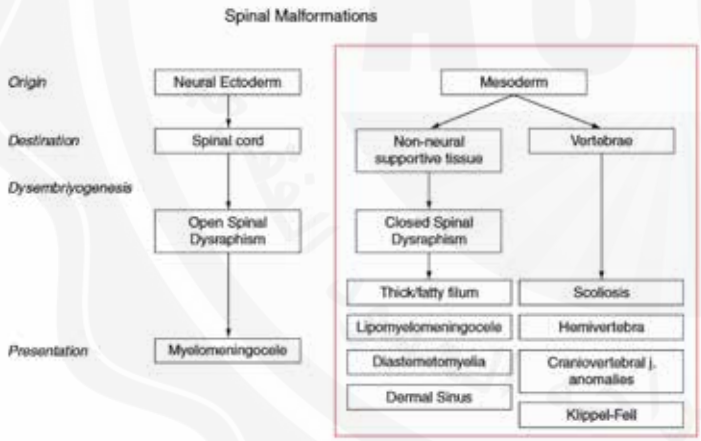

Embryology and spine

- Embryonic development of vertebrae is closely related with that of the spinal cord and the organs of the mesoderm
- High frequency of vertebrae, spinal cord and other organ defects
- Neural and vertebral malformations often coexist
- Congenital versus idiopathic scoliosis

Intraspinal anomalies
Clinical aspects

- Symptomatic at presentation
- Asymptomatic at presentation with risk of symptoms with growth
- Asymptomatic with risk of symptoms during correction of the deformity

Patient's evaluation

- **Physical exam**
  - Trunc, shoulder, pelvis deformity
  - Skin anomalies
  - Peripheral anomalies
  - Cardiac, genitourinary, musculoskeletal ...
- **Neurological assessment**
- **Radiographic assessment**
  - XR, standing XR, Dynamic..
  - CT 3D
  - MRI

Neurological signs

Table 3. Neurological Signs and Symptoms of Occult Spinal Dysraphism

Infants	Toddler	Older Children	Young Adults
Decreased spontaneous leg movement Absent reflexes Leg atrophy Foot asymmetry Decreased urinary stream	Developmental delay (walking) Abnormal gait	Asymmetrical motor/sensory Painless ulcerations Back/leg pain Upper motor neuron signs	Back pain Leg cramping/pain Spasticity Hyperreflexia Bowel/bladder incontinence

Congenital scoliosis

Congenital scoliosis

- Intraspinal anomalies were found in **30-38% of the patients**.
- Mixed and segmentation defects and thoracic hemivertebrae were common in patients with congenital kyphosis.
- Other organic defects were found in 55% of the patients.
- Congenital heart disease was present in 26% of the patients.
- **Magnetic resonance imaging and echocardiography should be part of routine assessment**.

8 y
Deformity
hair patch dorsal
Neuro free

- The most common malformation of spinal cord is diastematomyelia (split cord),
- Diastematomyelia is found in approximately 20% of patients with congenital scoliosis

Idiopathic scoliosis

- The incidence of neurological abnormalities has been reported as high as 20%
- MRI should be requested if abnormal neurological findings (absence of abdominal reflexes)
- The most frequent neuropatholgy anomaly is Arnold chiari malformation with or without syringomyelia followed by tethered cord

Indications for MRI

- patients with scoliosis and abnormal neurological findings
- patients with a left thoracic curve pattern, especially boys
- patients with spinal deformity under 11 years of age
- **patients with scoliosis and surgical indication**.

Indications for MRI

TABLE 1 Indications for Magnetic Resonance Imaging

Pain	Neurological Findings	Atypical Curve Pattern
Back	Clonus	Left thoracic
Neck	Abnormal abdominal reflexes	Short segment (4 to 6 levels)
Radicular	Weakness	Decreased vertebral rotation
Headache	Urinary dysfunction (urinary tract infection)	Absence of thoracic apical segment lordosis
	Hyperreflexia	Rapid progression
	Asymmetric deep tendon reflexes	
	Paresthesias	
	Diminished rectal tone	
	Cavus foot deformity	
	Skin lesions	

SPINE Volume 35, Number 2, pp 182–188
©2010, Lippincott Williams & Wilkins

The Left Thoracic Curve Pattern

A Strong Predictor for Neural Axis Abnormalities in Patients With "Idiopathic" Scoliosis

Liang Wu, PhD,* Yong Qiu, MD,† Bin Wang, MD,† Ze Zhang Zhu, PhD,† and Wei Wei Ma, PhD†

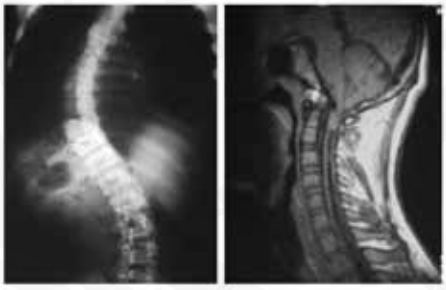

Idiopathic scoliosis and left pattern curve

- Normal neurologic status in a patient with scoliosis can not rule out the presence of neural axis abnormalities.
- There is a striking association between left thoracic scoliosis and neural axis abnormalities.
- Male gender and curve severity are predictable factors for neural axis abnormalities in patients with left thoracic scoliosis.

Chiari malformation

- Chiari type 1
- Most common neural axis abnormalities in pediatric scoliosis

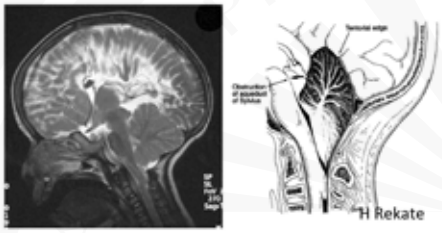

- Scoliosis can improve after decompression of Chiari malformation.
- Early decompression appears to have more favorable results on scoliosis.
- 48% No curve progression after syrinx treatment
- Younger chlidren have better results
- Treat syrinx prior to deformity treatment

Tethered cord

- Low lying conus
- dysplastic filum terminale (hypertrophic, fatty)
- Myelomeningocoele, SCM, dermal sinus tract, lumbo sacral dysgenesia
- Variable symptomatology (according to the age and associated abnormalities)

Tethered cord

- Fixation of the spinal cord
  - Fibrous or fibroadipose filum terminale
  - Tumor
  - Scar formation
  - diastematomyelia
- Spinal cord traction syndrome
- Spinal dysraphism

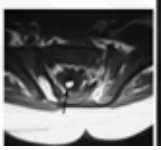

Tethered cord
Signs and symptoms

- Pain in LB and legs (numbness, tingling)
- Sensory changes are patchy (S3,S4,S5)
- Motor weakness diffuse
- Sphincter disturbances
- Deformity of the lower extremities
- scoliosis

SCM

- Type 1 (diastematomyelia)
  - 2 hemicord / 2dural sac
  - Rigid osseous or cartilaginous septum
- Type 2
  - 2 hemicord / 1dural sac
  - No septum

Neurosurgical correction is needed in SCM type 1

- Detect, identify and treat neural abnormalities prior to scoliosis tretament

- Identifying neurogenic factors in the setting of scoliosis prevent neurologic complications and may improve the outcome of the scoliosis treatment.

- Tethered cords due to myelomeningocele adhesions, SCMs, lipomas, dermal sinus tracts, and filum terminale dysgenesis are best treated by releasing the affected cord and offers the best opportunity to stabilize or improve the scoliosis.

- Chiari malformations are often associated with syringomyelia, which in turn may promote scoliosis. Treating the chiari malformation and the syrinx might improve and stabilise the deformity.

- MRI should be undertaken for congenital scoliosis and in idiopathic scoliosis when there are neurological findings, abnormal progression and atypical curve

ROLE OF CAST, BRACE AND REHABILITATION

Role of Casting, Bracing, and Rehabilitation

- Casting, bracing, and rehabilitative efforts depend largely on
  - Type/age of onset
  - Curvature
- Must discuss expectations

Lewis Sayre, MD 1877

Role of Casting, Bracing, and Rehabilitation

- Early onset
  - Congenital
  - Infantile Idiopathic
- Juvenile Idiopathic Scoliosis
- Adolescent Idiopathic Scoliosis
- Scheurmann's Kyphosis
- Adult Spinal Deformity

Lewis Sayre, MD 1877

Role of Casting, Bracing, and Rehabilitation

- Early Onset Scoliosis (<5 years)
  - Casting, bracing may help in some patients
    - allowing growth while slowing progression
    - May delay surgery
  - Depends on flexibility of the curve (bending x-rays)
    - Rigid curves – less indication
  - Anesthesia may be required for casting children.

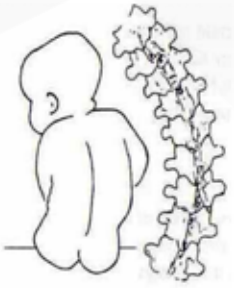

Role of Casting, Bracing, and Rehabilitation

- Early Onset Scoliosis (<5 years)
  - Manipulation, physical therapy have not been shown to influence spinal deformity in EOS patients.

Role of Casting, Bracing, and Rehabilitation

- Congenital
  - Vertebrae not properly formed (most common- hemivertebra)
  - Very early in development
    - first six weeks of embryonic formation.
  - No good evidence for bracing
    - not indicated as primary treatment
      - no effectiveness shown
    - may be used to control supple compensatory curves

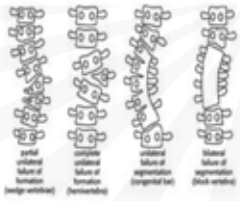

Role of Casting, Bracing, and Rehabilitation

- Infantile Idiopathic Scoliosis
  - Birth to 3 years
- Observation
  - Cobb angle < 30 degrees
  - RVAD (rib vertebrae angle difference) < 20 degrees
    - 90% will resolve spontaneously

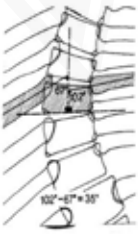

Role of Casting, Bracing, and Rehabilitation

- Infantile Idiopathic Scoliosis
- Casting
  - Cobb angle > 30 degrees
  - RVAD > 20 degrees
  - Serial Mehta casting (derotational)
    - Non-removable brace
    - Reduces non-compliance, difficulties donning
    - flexible curves only
    - young patients – can help decrease curve
    - older patients - adjunctive measure prior to surgery

Role of Casting, Bracing, and Rehabilitation

- Infantile Idiopathic Scoliosis
- Casting
  - In some, can be definitive treatment
  - 2015 Study, University of Virginia
    - 45 pts, mean age 18.8 months
    - Follow up at mean 37.7 months
    - Cobb: 52.7 to 25.6 directly after casting
    - Final follow-up continued to improve to 16.2 derees
    - Rib-vertebral angle difference 32.3-18

Role of Casting, Bracing, and Rehabilitation

- Infantile Idiopathic Scoliosis
- Casting
  - 2009 study, Shriners
  - 55 patients, most with 2 year follow-up
  - Average Cobb angle 52 degrees (range 25-100)
  - Average RVAD 31 degrees
  - All but 6 responded to cast correction
  - 9 still underwent surgery (3 by parent choice)
  - Younger age, <60 degrees, and idiopathic diagnosis do better

Role of Casting, Bracing, and Rehabilitation

- Infantile Idiopathic Scoliosis
- Casting
  - Under 2 years – goal is correction
  - Serial casting under anesthesia (every 2-
  - 3 months)
  - Will likely still need bracing

Role of Casting, Bracing, and Rehabilitation

- Infantile Idiopathic Scoliosis
- Bracing
  - Incompletely corrected curves after casting
  - Late if spine is still flexible
  - Will rarely correct
  - Goal: allow growth and decrease progression prior to surgery
  - Overall similar efficacy
    - Kallabis*
    - Wilmington
    - Boston
    - Milwaukee – less popular

Role of Casting, Bracing, and Rehabilitation

- Juvenile Idiopathic Scoliosis
  - 4-10 years (or puberty onset)
  - High risk of progression
- Observation
  - curves < 20°
  - Follow curve progression

Role of Casting, Bracing, and Rehabilitation

- Juvenile Idiopathic Scoliosis
- Bracing
  - curves 20 - 50°
  - prevent curve progression
  - will likely not correct curve
  - 16-23h/day until skeletal growth completed or surgery
  - Similar efficacy
    - Wilmington
    - Boston *
    - Milwaukee
    - Charleston and Providence: sleeping

Role of Casting, Bracing, and Rehabilitation

- Juvenile Idiopathic Scoliosis
- Casting
  - Serial casting can be used
  - Considered as a full-time brace
  - Less common in juvenile population

Role of Casting, Bracing, and Rehabilitation

- Juvenile Idiopathic Scoliosis
- Traction/Halo
  - For pts with progressive deformity and cannot tolerate bracing
    - Weakness
    - Skin or chest wall intolerance
    - Mental retardation
    - Large or very stiff curves
    - Used as a method of reducing curve prior to surgery

Role of Casting, Bracing, and Rehabilitation

- Adolescent Idiopathic Scoliosis
  - 10 years to maturity
  - Most common
  - High risk of progression
- Observation
  - Curve < 25 degrees and still growing
  - Curve < 50 degrees in skeletally mature patients

Role of Casting, Bracing, and Rehabilitation

- Adolescent Idiopathic Scoliosis
- Bracing
  - Curves between 25 – 40 degrees and not skeletally mature.
  - Goal: Slow down progression
  - Wear until skeletal maturity – goal is to slow or stop progression, not reverse curve

Role of Casting, Bracing, and Rehabilitation

- Adolescent Idiopathic Scoliosis
- Bracing
  - Risser sign commonly used to establish level of bone maturity
  - Amount of calcification in the iliac apophysis
  - Measures ossification anterolaterally to posteromedially
  - Grade 0-5
  - More immature – higher probability of progression

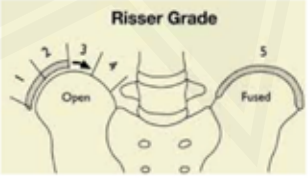

Role of Casting, Bracing, and Rehabilitation

- Adolescent Idiopathic Scoliosis
- Risser 1: 25% iliac apophysis ossification
- Risser 2: 50% iliac apophysis ossification
- Risser 3: 75% iliac apophysis ossification
- Risser 4: 100% ossification, with no fusion to iliac crest
- Risser 5: Iliac apophysis fuses to iliac crest, cessation of growth

Table 2. Probabilities of Progression
Risser grade versus curve magnitude at detection

Risser Sign	Curve Magnitude	
Grade	5-19°	20-29°
0-1	22%	68%
2-4	1.6%	23%

(From Lonstein, J.E., and Carlson, J.M.: The Prediction of Curve Progression in Untreated Idiopathic Scoliosis During Growth. J. Bone and Jt. Surg.,66A:1061-1071,1984).

Role of Casting, Bracing, and Rehabilitation

- Adolescent Idiopathic Scoliosis
- Alternative Treatments
  - Chiropractic medicine, physical therapy, yoga, etc. have little evidence to support use
  - Can be utilized for core strengthening, symptom relief
  - Not for treatment of curvature

Role of Casting, Bracing, and Rehabilitation

- Scheuermann's Kyphosis
  - Asymmetrical growth of vertebrae
  - Angular and rigid kyphosis
  - Back pain primary symptoms in teens, can improve into adulthood

Role of Casting, Bracing, and Rehabilitation

- Scheuermann's Kyphosis
  - 55-80 degrees and skeletally immature
    - brace with exercise program
    - Bracing full time (20 hours/day)
    - Consider part time in last year of immaturity
    - Continue for 18 months post maturity
  - >80 degrees: Consider surgical intervention

Role of Casting, Bracing, and Rehabilitation

- Adult Spinal Deformity
- Observation
  - Coronal curves < 30 degrees
- Bracing – limited role
  - may slow progression or increase comfort

Role of Casting, Bracing, and Rehabilitation

- Adult Spinal Deformity
- Symptom management
  - oral medications
    - NSAIDS, TCAs
  - physical therapy: core strengthening, low impact cardiovascular activities
  - corticosteroid injections or radiofrequency ablation – target facet joints
  - Nerve root blocks and epidural injections for radicular pain

Role of Casting, Bracing, and Rehabilitation

- Summary
- In select cases, bracing can provide correction (infantile idiopathic < 2 years)
- In all others, goal is to prevent or decrease progression
- Many different bracing options available; all with similar efficacy
- Consider casting as a non-removable brace
- Rehabilitation and interventional procedures can be considered for strengthening and pain control, however not for curative treatment of deformity
- Discussion of expectations is crucial

Role of Casting, Bracing, and Rehabilitation

- References

- Bunnell, W. P. The natural history of idiopathic scoliosis before skeletal maturity. Spine, 11:773-776, 1986
- Cuccurullo, SJ. Physical Medicine and Rehabilitation Board Review. Demos Medical, 2009
- Hassanzadeh H, Nandyala SV, Puvanesarajah V, Manning BT, Jain A, Hammerberg KW. Serial Mehta Cast Utilization in Infantile Idiopathic Scoliosis: Evaluation of Radiographic Predictors. J Pediatr Orthop. 2015 Nov 17
- Karol, L. A. Effectiveness of bracing in male patients with idiopathic scoliosis. Spine, 26(18): 2001-2005, 2001.
- Sanders JO, D'Astous J, Fitzgerald M, Khoury JG, Kishan S, Sturm PF. Derotational casting for progressive infantile scoliosis. Journal of Pediatric Orthopaedics 2009 Sep;29(6):581-7.
- Korovessis, P.; Kyrkos, C.; Piperos, G.; Soucacos, P.N.: Effects of thoracolumbosacral orthosis on spinal deformities, trunk asymmetry, and frontal lower rib cage in adolescent idiopathic scoliosis. Spine, 25(16):2064-2071, 2000
- Rowe, DE. The Scoliosis Research Society Brace Manual. 2003. www.srs.org
- Richards BS, Katz DE. Bracing for Scheuermann's Kyphosis. 2009. www.srs.org
- Miller, J. A.; Nachemson, A. L.; and Schultz, A. B.: Effectiveness of braces in mild idiopathic scoliosis. Spine, 9:632-635, 1984.
- Rigo M. Patient evaluation in idiopathic scoliosis: Radiographic assessment, trunk deformity and back asymmetry. Physiother Theory Pract 2011. Jan;27(1):7-25

PRE-OP ASSESSMENT

Clinical Evaluation

- History
- Exam

History: Questions

- Pain:
  - Standing?
  - Walking?
  - Legs?
  - Back?
  - Falling forward?

History: Questions

- Pain:

Stenosis or deformity?

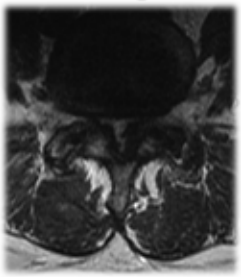

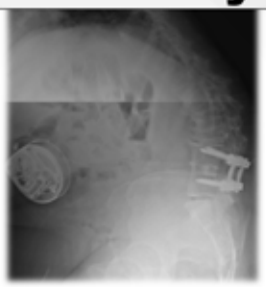

Exam

- Look
  - Posture
  - Where?
  - Straighten?
  - Lay down?
  - Hips?

Exam

- Look
  - Posture
  - Where?
  - Straighten?
  - Lay down?
  - Hips?

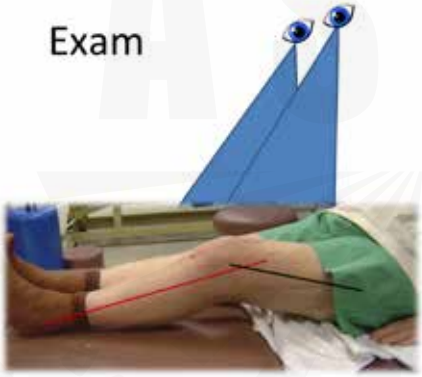

±contracture

X-rays

- Spot views

Not enough

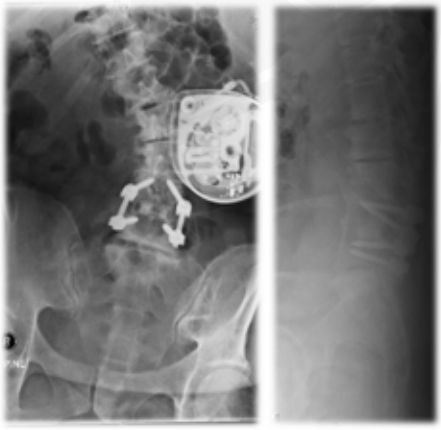

X-rays

- Long films

"Scoliosis views"

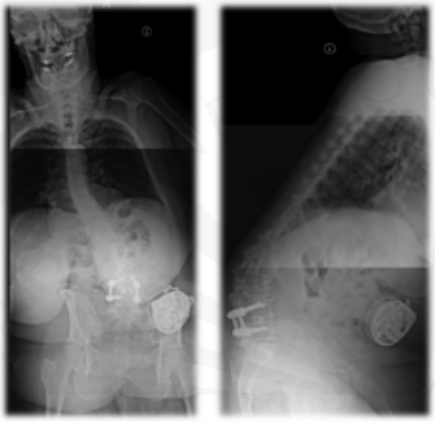

X-rays

- Long films

"Scoliosis views"

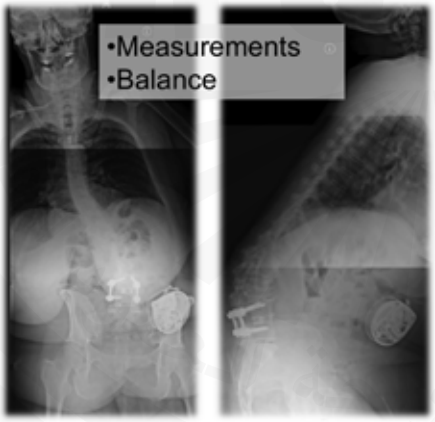

AP View

•Cobb angle

AP View

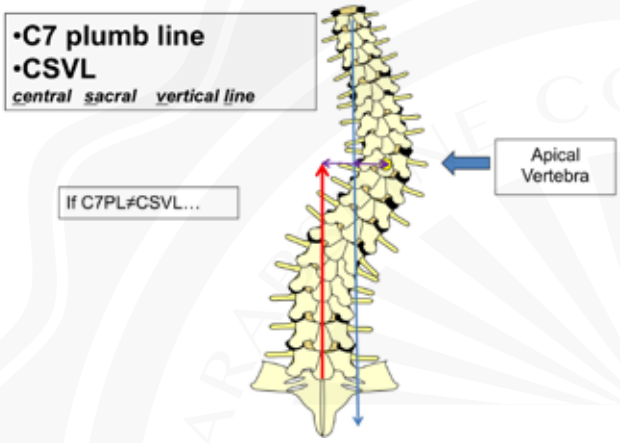

AP View

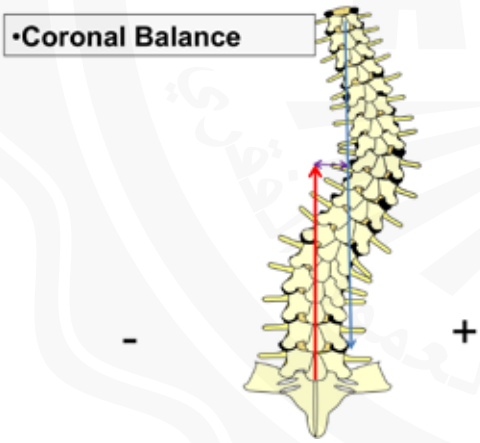

AP View

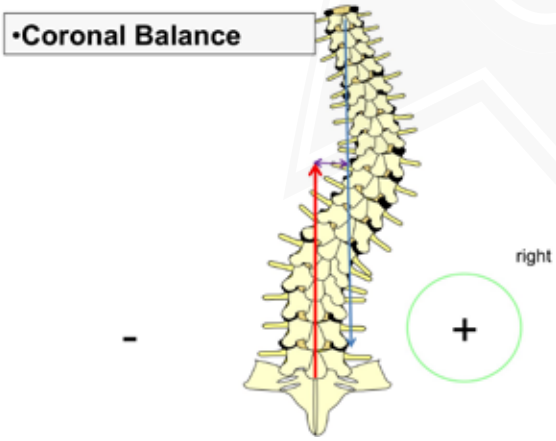

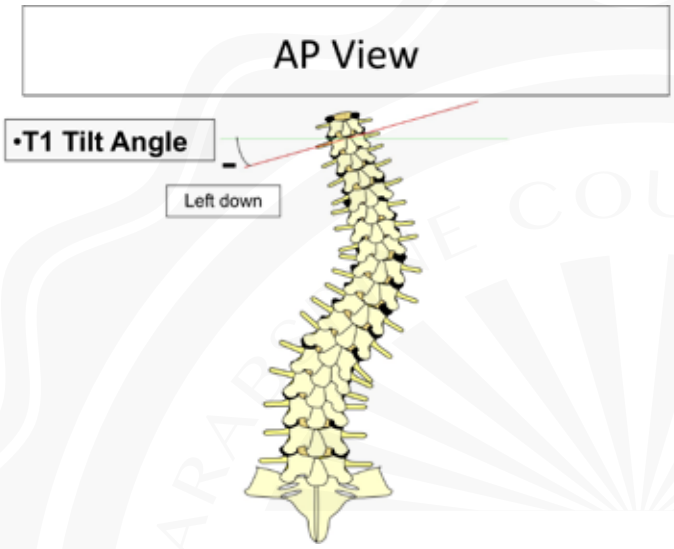
AP View
•T1 Tilt Angle
-
Left down

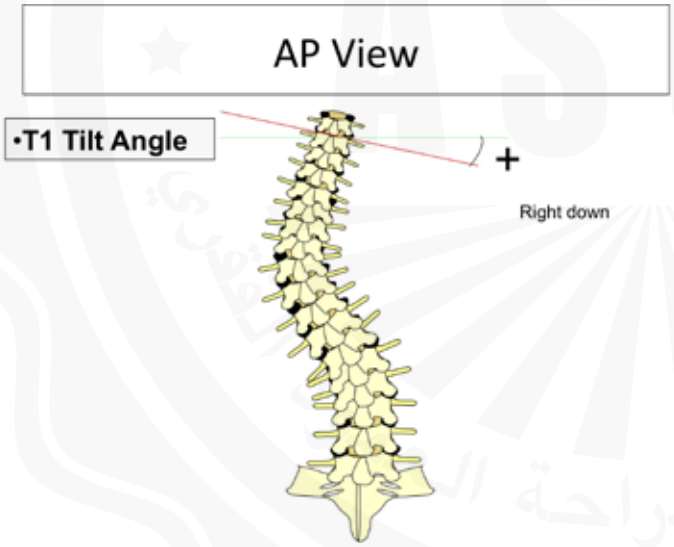
AP View
•T1 Tilt Angle
+
Right down

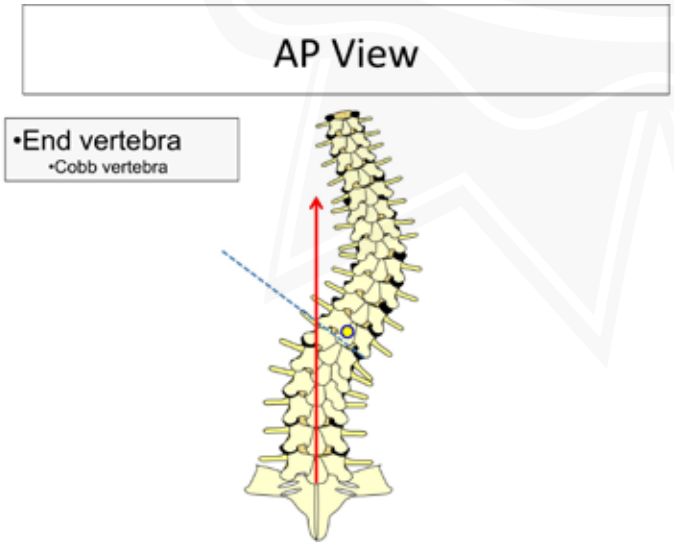
AP View
•End vertebra
•Cobb vertebra

AP View

- End vertebra
- Neutral vertebra
  - No rotation

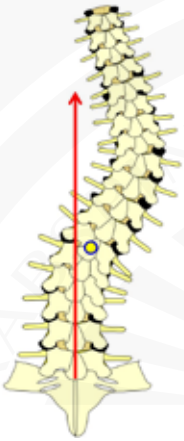

AP View

- End vertebra
- Neutral vertebra
- Stable vertebra
  - 1st bisected by CSVL

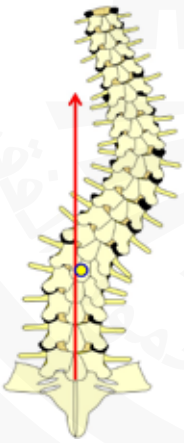

Lateral View

- Thoracic Cobb
  - T2 –T12

Lateral View

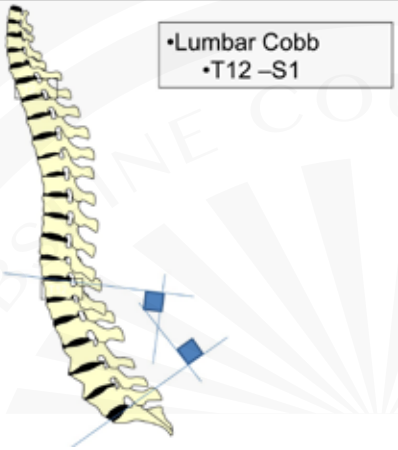

Lateral View

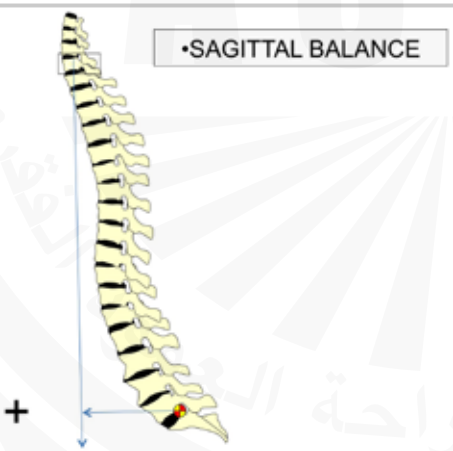

Lateral View

Pelvic Parameters

•Pelvic Incidence

Pelvic Parameters

•Pelvic Incidence

Pelvic Parameters

•Pelvic Tilt

Pelvic Parameters

•Sacral Slope

Pelvic Parameters

•Relationship
•PI=PT+SS

Pelvic Parameters

•Lumbosacral Angle

Relevance:
Isthmic
Spondylolisthesis

Using Radiograph Parameters: Classification

Type	Description	Etiology
I	1° deg scoli, apex L2,3,4	Disc degeneration
II	Progressive idiopathic	From AIS
III a	2° adult scoli	Because of pelvis/LLD
III b	From compression fx	From compression fx

Aebi. The adult scoliosis. Eur Spine J. 2005

Using Radiograph Parameters: Classification

Type	Description	Etiology
I	1° deg scoli, apex L2,3,4	Disc degeneration
II	Progressive idiopathic	From AIS
III a	2° adult scoli	Because of pelvis/LLD
III b	From compression fx	From compression fx

Simple. Helpful?

Aebi. The adult scoliosis. Eur Spine J. 2005

Using Radiograph Parameters: Classification

Lowe et al. SRS Classification for Adult Deformity. Spine. 2006

Using Radiograph Parameters: Classification

Lowe et al. SRS Classification for Adult Deformity. Spine. 2006

Schwab Classification

Schwab et al. New Adult Deformity Classification. Spine. 2007

Schwab Classification



Schwab et al. New Adult Deformity Classification. Spine. 2007

Summary

- Look, listen, learn
  - Examine your patients



Summary

- Look, listen, learn
- Study the radiographs
  - Measure
  - Measure
  - Measure

Summary

- Look, listen, learn
- Study the radiographs
- Classify
  - Plan tx





POSITIONING / BLOOD SAVING

Deformity – Module 4
Positioning / Blood Saving

Breckenridge, Colorado
Rocky Mountain
"Champagne Powder"

Disclosures
David A. Wong MD, MSc, FRCS(C)

- Research Support
  - Mesoblast
- Consultant
  - United Healthcare
- Stock
  - Denver Integrated Imaging
  - Huron Shores LLC
- Royalties
  - Lippincott

Outline
"Positioning / Blood Saving"

- Prone Position
  - Avoiding coagulopathy
- Cell Saver
  - Parameters / Cost
- Blood Conservation Meds
  - Tranaxemic Acid
- Transfusion
  - Parameters / Cost
    - Intra Op/ Post Op

British Journal of Anaesthesia 100 (2): 165–83 (2008)
doi:10.1093/bja/aem380

Anaesthesia in the prone position

H. Edgcombe[1], K. Carter[1] and S. Yarrow[2]*

- Analysis multiple OR frames
- Discuss Several Issues/Complications
  - Cardiac Index(stroke volume) ↓24%
    - Anesthesia Considerations
  - Perioperative Blindness
    - Intra occular pressure-direct/indirect
    - Posterior Ischemic Optic Neuropathy (PION)
    - American Society of Anesthesiologists
      - Practice Advisory 2006 (revised 2012)

Prone Position
Cardiac Index ↓ 24%

- Intra-op Hypotension
- Anesthesia Options-Meds
  - Phenylephrine
    - Vasoconstriction
      - No effect stroke volume
      - Potential negative peripheral circulation
      - **Acidosis → coagulopathy**
  - Ephedrine /Dopamine=***Best***
    - Cardiac stimulant

Peri-Operative Blindness

ASA Practice Advisory 2012

- High Risk
  - Surgery > 6.5 hrs
  - Blood loss > 45%
  - Prone (spine surgery)
- Operative Management
  - Avoid direct eye pressure
  - Arterial line
  - BP within 24% baseline
    - 84 mm systolic minimum
  - Hct > 28%/Hb > 9.4

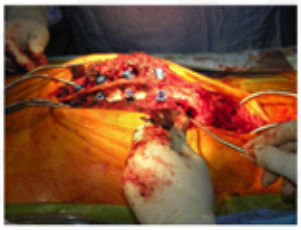



ELSEVIER

THE SPINE JOURNAL

Clinical Study

Effect of the degree of reverse Trendelenburg position on intraocular pressure during prone spine surgery: a randomized controlled trial

Timothy W. Carey, DO, CPT, MC*, K. Aaron Shaw, DO, CPT, MC*, Marissa L. Weber, MD, CPT, MC*, John O. DeVine, MD, COL, MC*

10° incline

Fig. 1. Depiction of three table inclination groups.

Cell Saver

SPINE Volume 29, Number 14, pp 1580–1584
©2004, Lippincott Williams & Wilkins, Inc.

The Cell Saver in Adult Lumbar Fusion Surgery

A Cost-Benefit Outcomes Study

Charles A. Reitman, MD,* William C. Watters, III, MD,† and Walter R. Sassard, MD†

- Liang J, Shen J, Chua S, et al. Does intraoperative cell salvage system effectively decrease the need for allogeneic transfusions in scoliotic patients undergoing posterior spinal fusion? A prospective randomized study. Eur Spine J. 2015;24(2):270-275.

Blood Conservation Medications

- **Tranexamic Acid (TXA)**
- Epsilon-aminocaproic acid (EACA) –Amicar
- Aprotinin (trasylol)

- Concerns
  - DVT / PE
  - MI
  - CVA

ELSEVIER

The Spine Journal 15 (2015) 752–761

THE SPINE JOURNAL

Review Article

Efficacy of tranexamic acid on surgical bleeding in spine surgery: a meta-analysis

Thomas Cheriyan, MD*, Stephen P. Maier, II, BS, Kristina Bianco, BA, Kseniya Slobodyanyuk, BA, Rachel N. Rattenni, BA, Virginie Lafage, PhD, Frank J. Schwab, MD, Baron S. Lonner, MD, Thomas J. Errico, MD

Division of Spine Surgery, Department of Orthopaedic Surgery, Hospital for Joint Diseases, New York Langone Medical Center, 306 East, 15th St, New York, NY 10003, USA

Received 4 April 2014; revised 17 November 2014; accepted 8 January 2015

- Antifibrinolytic
- Lysine analog
- Inhibits activation of plasminogen
- 11 RCT's analyzed

Spine

SPINE Volume 40, Number 8, pp E443-E449
©2015, Wolters Kluwer Health, Inc. All rights reserved.

RANDOMIZED TRIAL

Antifibrinolytics Reduce Blood Loss in Adult Spinal Deformity Surgery

A Prospective, Randomized Controlled Trial

Austin Peters, MD,*† Kushagra Verma, MD, MS,*‡ Kseniya Slobodyanyuk, MD,* Thomas Cheriyan, MD,* Christian Hoelscher, MD,* Frank Schwab, MD,* Baron Lonner, MD,* Tessa Huncke, MD,* Virginie Lafage, PhD,* and Thomas Errico, MD*

- RCT
  - TXA/EACA/Placebo
    - 19/ 19/ 13 patients
  - Both antifibrinolytic arms trend to reduced EBL
    - Not statistically significant
      - Insufficient power

Transfusion Risk/ Complications

- HIV 1:1,930,000
- Hep B 1:137,000
- Hep C 1:1,000,000
- HTLV-1 1:641,000
- Death 1:1,000,000

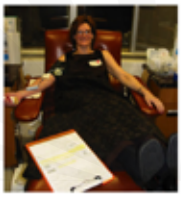

- Stramer SL ed. Blood Safety in the New Millenium. American Association of Blood Banks. Bethesda, Maryland 2001.

Transfusion Cost

- Lab Costs (Hb, T&C etc.)
  - $133 / 117€ /489 AED
- Autologous Unit
  - $175 / 153€ / 643 AED
- Bank Unit Blood
  - $393 / 345€ / 1443 AED
- Cell Saver
  - Bowl only
    - $195 / 171 € /716 AED
  - Complete processing
    - $874 / 766 € / 3210 AED

"The labs are back."

Thank You

- WHO Surgical Checklist
  - Chair- Atul Gawande MD
  - Reduce medical errors
  - Promote team communication
- Sign In / *Briefing*
  - Prior to Induction
- Time Out
  - Prior to Skin Incision
- Sign Out / Debrief
  - Prior to Drape Removal

PLANNING & STRATEGY IN DEFORMITY CORRECTION

- Proper history taking and clinical assessment to exclude causes of postural deformity as

- Limb length inequality.
- Irritative lesions.

Short leg deformity Sciatic list

- **Three fundamental treatment options exist for idiopathic scoliosis:**

  -Observation
  -Bracing and casting
  -Surgery

Level of Maturity

- Onset of menarche
- Growth spurts
  - Peak height velocity (PHV)
  - Peak growth age (PGA)
- Skeletal maturity

- Peak height velocity (PHV) = maximum growth rate.
  - Female: Peak growth age: 10-14yrs.
  - Male: Peak growth age: 12-16yrs.
  - Crankshaft unlikely to occur after PGA.
- Menarche
  - Risk of progression higher before than after.

- Skeletal Maturity
  - Most commonly used markers in scoliosis:
    - Iliac apophysis (Risser).
    - Pelvis: triradiate cartilage.
  - Risser I occurs after PHV in 85%.
  - Girls: little remaining growth at stage IV.
  - Boys: substantial growth (curve progression) remaining between stage IV-V.
  - Triradiate cartilage fusion correlates with PHV.

Risser's sign

- The iliac apophysis first appears laterally and grows medially
- The iliac crest is divided into quadrants, and the stage of maturity is designated as the number of ossified quadrants
- **Risser I** <25% ossification
- **Risser II** 50% ossification
- **Risser III** 75% ossification
- **Risser IV** completion of ossification
- **Risser V** the apophysis has fused with the iliac crest / complete skeletal maturity has occurred.

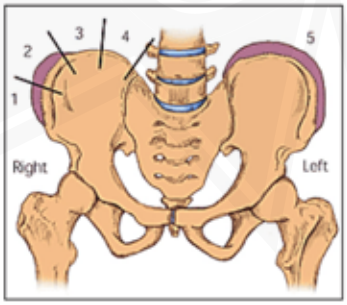

- Little et al. showed that peak height velocity and 2/3 of pubertal growth occurs before the first signs of iliac apophysis ossification.

- Nault and Dimeglio proposed that Risser Stage 0 be subdivided into open triradiate cartilage and closed triradiate cartilage (occurs at approximately twelve years in girls and fourteen years in boys) in order to make Risser stage 0 more useful.

Girls		Boys	
Risser	Age	Risser	Age
1	13.8	1	15.2
2	14.3	2	15.2
3	14.7	3	16.3
4	16.0	4	16.3
5	16.1	5	18.0

Lippman- Cobb method:

- Measuring the degree of scoliotic curvature.
- 2 angles are formed by the intersection of two sets of lines.
- The first set of lines, one drawn tangent to the superior surface of the upper end-vertebra and the other tangent to the inferior surface of the lower end-vertebra, intersects to form angle *(a)*.
- The intersection of the other set of lines, each drawn perpendicular to the tangential lines, forms angle *(b)*.
- These angles are equal, and either may serve as the measurement of the degree of scoliosis.

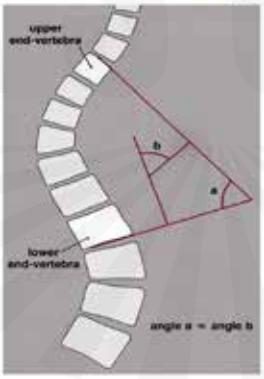

- Follow up every 6 months should be done during period of observation (curves < 20° before maturity and < 40° after maturity).

- Cessation of growth, Risser 5, and an interval of 2 years post-menarche are commonly used as criteria for making the decision to stop brace wearing.

- According to the apex of the curve:
- AboveT6: Milwaukee brace (cervicothoracolumbosacral).
- BelowT6: Boston brace (thoracolumbosacral).

Milwaukee brace

- Follow up occurs every 4-6 months, with in-brace radiographic evaluation and appropriate fitting adjustment made when necessary.

Boston brace

Aim of surgery:

- Production of a solid arthrodesis.
- Optimal three-dimensional correction / coronal and sagittal balance.
- Fusing the minimum number of vertebral levels.
- All structural curves should be included in the fusion.
- Costoplasty may be done for correction of rib hump.

- Standing antero-posterior view of the entire spine to demonstrate lateral deviation of spine. Good quality radiograph will show C7 to the femoral head and the entire rib cage.
- Antero-posterior radiographs obtained with the patient bending laterally to each side for evaluation of the flexible and structural components of the curve and amount of reduction.
- MRI in some cases to demonstrate abnormalities of nerve roots/ spinal cord, compression and displacement of thecal sac and tethering of cord ,specially, in male patients with left thoracic curve or presence of any neurological deficits or painful deformity.

T1 tilt angle

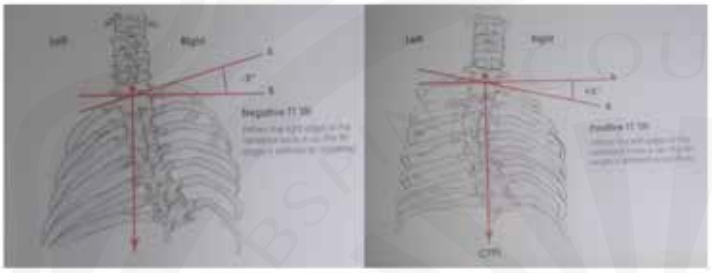

Clavicle angle

Radiographic shoulder height

Types of surgery

- Posterior instrumentation and fusion:

Type 1 (main thoracic): from neutral vertebra (see both pedicles equally/ spinous process in mid-line) proximally to stable vertebra (most proximal vertebra where central sacral vertical line falls equidistant between the pedicles) or stable minus one vertebra distally.

Type 2 (double thoracic): fusion begins at either T-2 or T-3, and distally, the LIV is the same as for type 1 curve. It is important to evaluate the clinical shoulder balance in these patients.

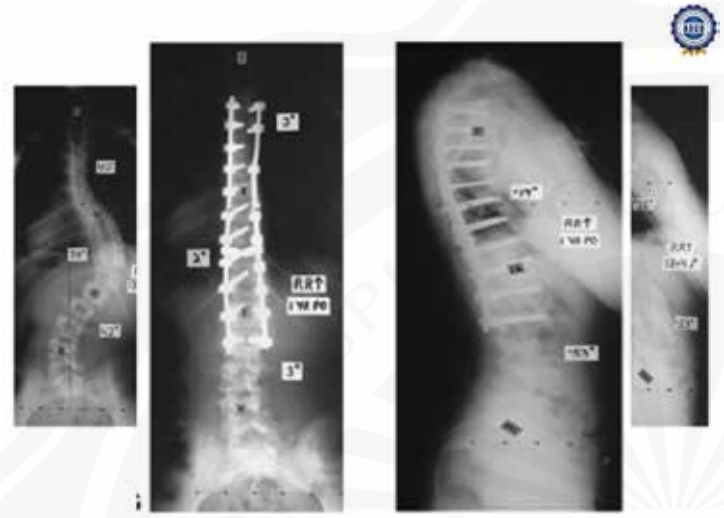

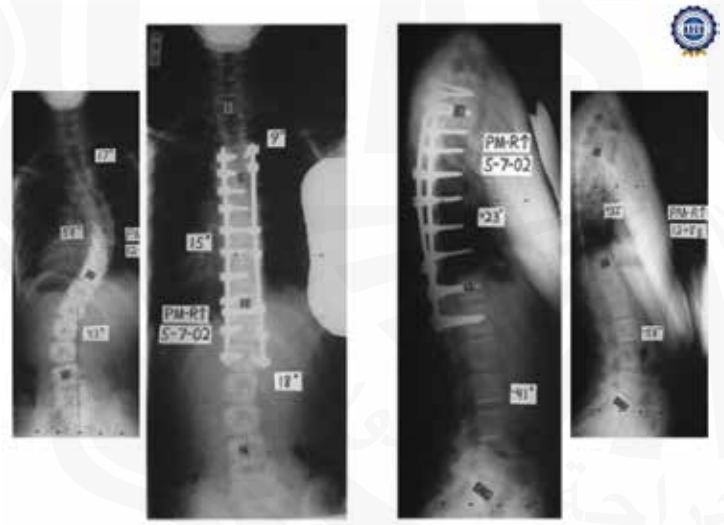
PM-RT
5-7-02

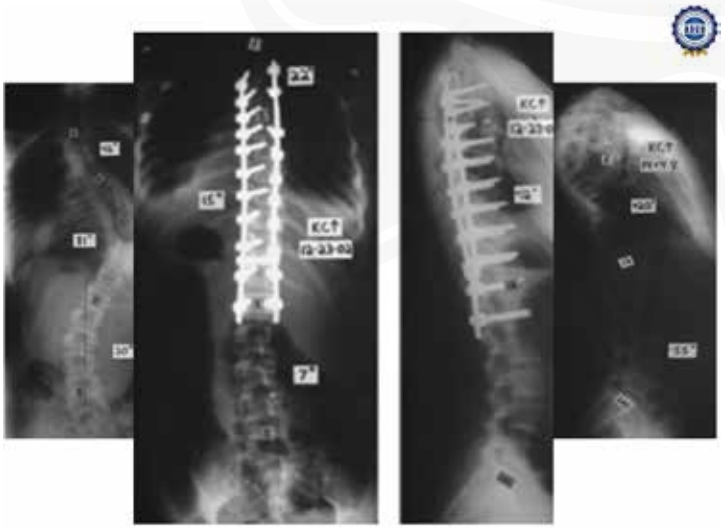

- Type 3 (double major):

If the apex of the TL/L curve is on or lower than L2 and L4 has a rotation of 1 degree or greater according to Nash-Moe classification, the fusion should be extended to L4.

If the apex of the TL/L curve is on or higher than L1-2 and if L4 has a rotation of 1.5 degrees and lower, L3 should be selected as the LIV.

The goal is complete horizontalization, centralization, and neutralization of the LIV (Most proximal lumbar vertebra touched by the CSVL).

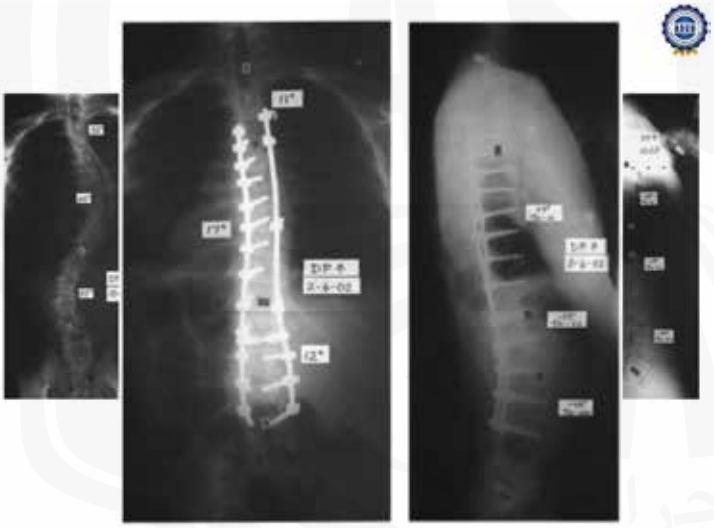

- Type 4 (triple major): fusion of all curves following the same roles.

- Type 5 (T/L & lumbar): Posterior or anterior instrumentation & fusion.

- Type 6 (T/L & lumbar- main thoracic): as type 3.

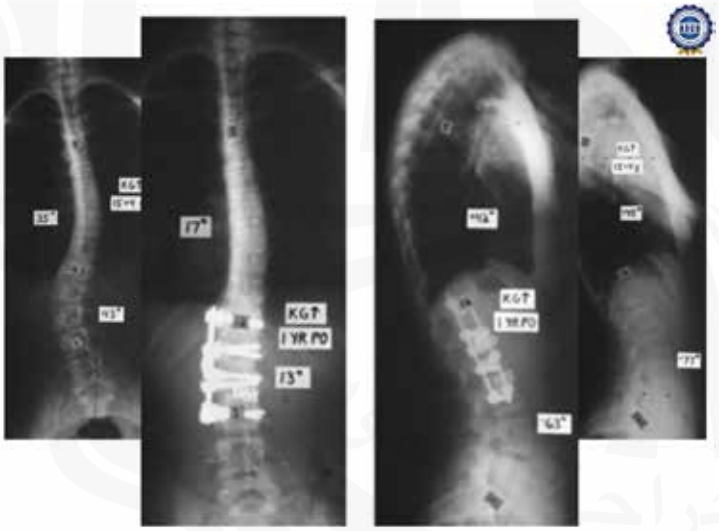

- Combined anterior release and fusion followed by posterior spinal fusion:

Decrease the retsraining structures effect on reduction of the curve through:

- multiple anterior discectomies of the intervertebral discs of the apical segments
- osteotomies of the apical vertebrae
- excision of the heads of the ribs.
- division of the anterior longitudinal ligment and discs annulii.

Indications:

- Anterior release:
  - rigid curves > 60 °
  - curve correction in bending views < 50%.
- Anterior Osteotomies:
  - rigid curves > 90º.

- It may be done through open or thoracoscope technique.

How to prove value of anterior release

- Try correction before release.
- Use standardized force.
- Do the desired release.
- Retry the correction with the same force.

- Thoracoscopic release in prone position.
- Ti cables with 35N force.

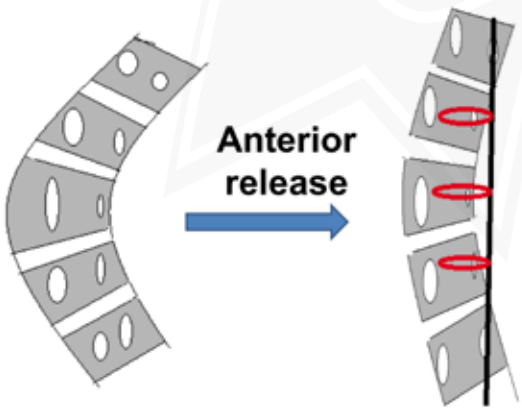

Operative setup:

- Implants: hooks/sublaminar wires and pedicle screws which allow greater correction power in the coronal, sagittal, and axial planes over hybrid constructs.
- Facet osteotomies and cartilage denuding to improve fusion rate.
- Autogenous bone graft (iliac crest).
- Intra operative wake up test.
- MEP and SSEP.

- Correction technique:
  - Rod derotation maneuvers.
  - Direct apical vertebral derotation.
  - In situ bending (coronal or sagittal translation).
  - Compression & distraction.

- Female 10 yrs with curve 15°
  Observation
- Female 18 yrs with curve 20°
  Observation
- Male 11 yrs with curve 25° with 5° progression 6 months later
  Bracing
- Female 10 yrs with curve 35°
  Bracing
- Female 13 yrs with curve 45°
  PSF

- Male 19 yrs with curve 55°

  PSF

- Female 14 yrs with curve 80° correctible to 55° on bending views

  Ant.release followed by PSF

- Female 13 yrs with thoracolumbar curve 60°

  PSF or ant.instrumentation and fusion

- Female 6 yrs with curve 40° increased after 2 yrs of bracing to 55°

  Growing rods

- Female 14 yrs with curve 100° rigid with associated severe kyphosis

  Vertebral column resection

Female patient, 16 years old, curve 55°

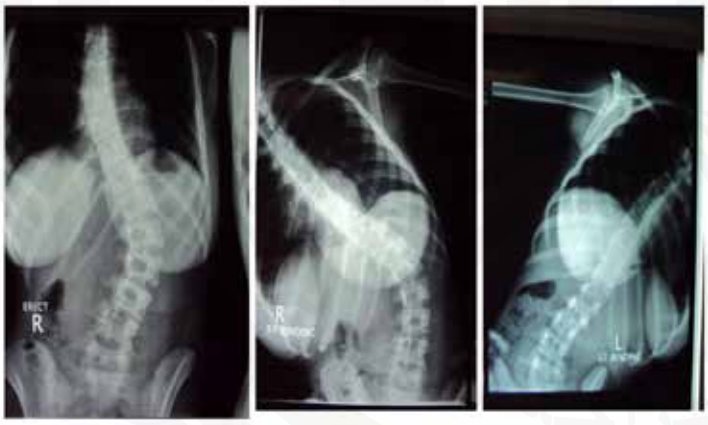

Female patient, 15 years old

Female patient, 20 years old

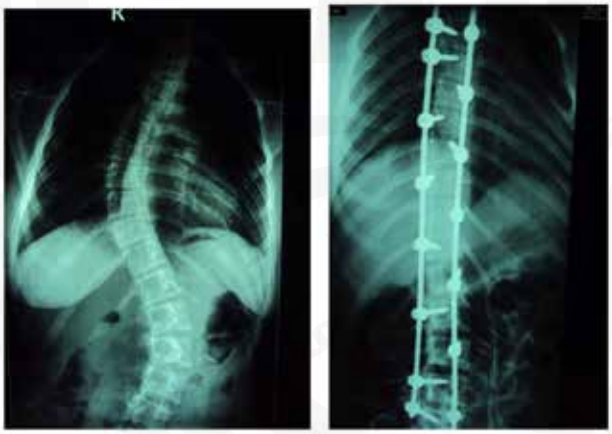

Male patient ,19 years old, cobb angle 61°

Female patient ,18 years old, AIS curve 45°

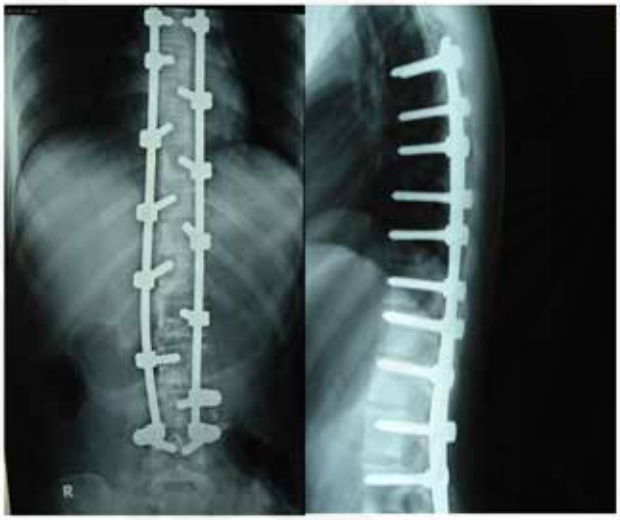

Female patient ,17 years old

After anterior release and 2 wks of traction

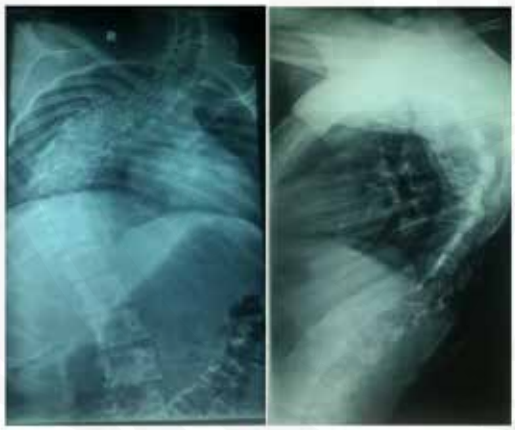

Infantile idiopathic scoliosis

- Determine the curve prognosis based on Mehta's RVAD.
- Non-progressive curves → observation.
  - <25° Cobb angle.
  - <20° RVAD.
- Reevaluate in 4-6 months (repeat clinical & radiographic examinations).
- Resolution → follow at 1-2 year interval.
- Followed to maturity (no recurrence in adolescent growth spurt).

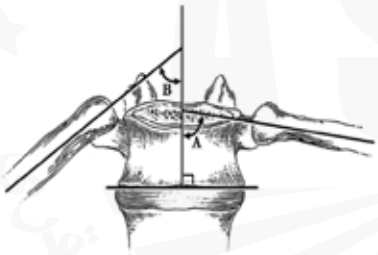

RVAD=A-B

- Mehta rib vertebral angle difference > 20° or overlap of the head of the rib over the vertebra = progressive infantile scoliosis.

- Curves at presentation :
  - 20 -35° Cobb angle
  - >20 °RVAD
- Chance of progression:
  - Reevaluate at 4-6 months
  - Treatment if either the Cobb angle or the RVAD increase by 5-10°
- Conservative treatment of choice for the progressive curve is serial casting (under GA) followed by a Milwaukee brace to maintain correction
- Progressive curves despite bracing →operative management

- Juvenile Idiopathic Scoliosis generally, do not resolve spontaneously.

– Surgery is recommended for progressive curves of >45-50°

– Bracing may be used to slow progression of the curve (delay surgery until more growth completed).

- Expected Loss of Growth (fusion)
  - Growth/ spinal segment/ year
    - 5-10 years: 0.05 cm
    - 10-16 years: 0.11 cm
  - Winter's formula
    - Determining the amount of potential shortening after spinal fusion.
    - Shortening in cm = 0.07 x the number of segments fused x the number of years of remaining growth.
    - 5yrs old; fusion from T5-L1: 0.07 cm × 8 segments × 11 years = 6.16 cm.
    - Inform the family of the estimated shortening.

- Instrumentation with Limited Fusion
  - In children younger than 8 years of age.
  - Spine exposed only at the ends of the curve & performing end fusions at the sites of insertion of pediatric hooks or screws.
  - A rod is inserted under the fascia & attached to the hooks or screws.
  - The rod lengthened (distraction) every 6 to 12 months & replaced as additional length is needed.
  - Allows for continued growth of the spine & delay of formal spinal fusion.

- Alternative: combine with localized anterior fusion of the apical vertebrae
  - Localized anterior fusion stops progression of the curve & growth of the apical vertebrae.
  - Lessens any increase in deformity caused by continued vertebral rotation.

Congenital scoliosis

- Unilateral unsegmented bar: most curves exceed 50° by 10 years of age.
- Fully segmented hemivertebra: Lower thoracic and thoracolumbar curves deteriorate most rapidly and can exceed 45° at skeletal maturity.
- Unilateral unsegmented bar with contralateral hemivertebrae: most severe & rapidly progressive of all types of congenital scoliosis, most curves exceed 60° by 4 years of age.

Types of surgery include

•In situ fusion: is indicated in progressive scoliosis presenting with a minimal deformity at surgery time, no more than 25°, with a limited area of no more than 5 vertebrae because correction possibilities are limited.

•Convex hemiepiphysiodesis: good results if the curve is less than 30°. During surgery, the correction of the curve is partially obtained, the remaining correction being achieved slowly, the correction limit is up to 20-25°.

- Excision of the hemivertebra: the best treatment method in comparison to in situ fusion and hemiepiphysiodesis. It may be performed by an anterior or posterior approach.

Nine years old male with D8 hemivertebra → GH

Excision with anterior fusion

Brace with follow up

Convex hemiepiphysiodesis

Postoperative

After removal of posterior implant

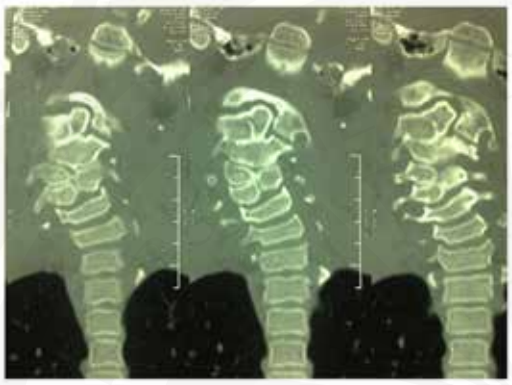

Double hemivertebra

Diastematomyelia with unsegmented bar

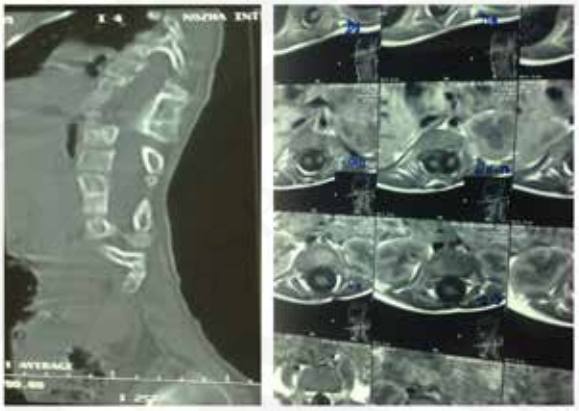

Difficulties and limitations in congenital scoliosis

- X-rays are sometimes not very informative.
- Cervicodorsal area always needs CT scan.
- MRI is sometimes difficult to be interpretted with scoliotic deformity.

- Missed intraspinal anomaly may lead to neurologic deficit
- Anaesthetic difficulties due to difficult intubation and associated visceral anomalies.
- Difficult decompression with small field.
- Difficulties in fixation (small pedicles and small spinal canal).

- Growth potential.
- Compensatory curve may turn structural.
- Skin problems from high profile of fixation tools

Mid-dorsal hemivertebra with hypoplasia of clavicle

IOM IN DEFORMITY SURGERY

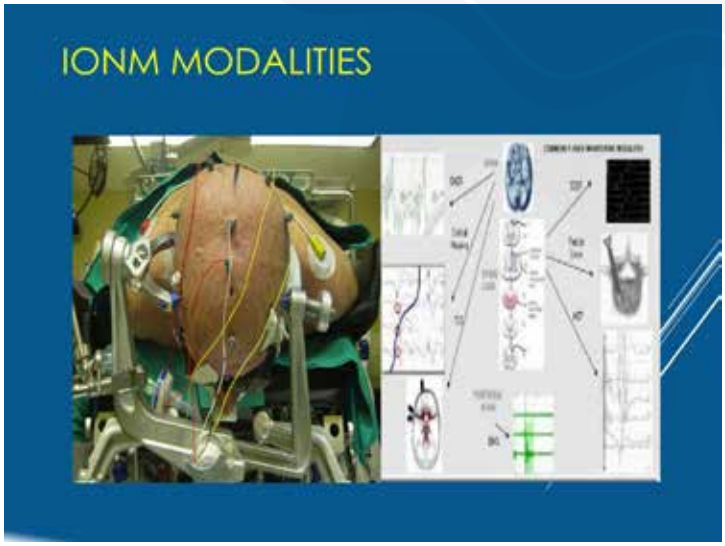

WHAT MONITORING MODALITIES ARE AVAILABLE?

There are a variety of different modalities we can use in spine surgery:

- SSEP
- TCeMEP
- D-WAVE
- SEMG / TEMG
- Direct Nerve Stimulation
- Cord to Cord Stimulation.

SSEP (SOMATOSENSORY EVOKED POTENTIAL)

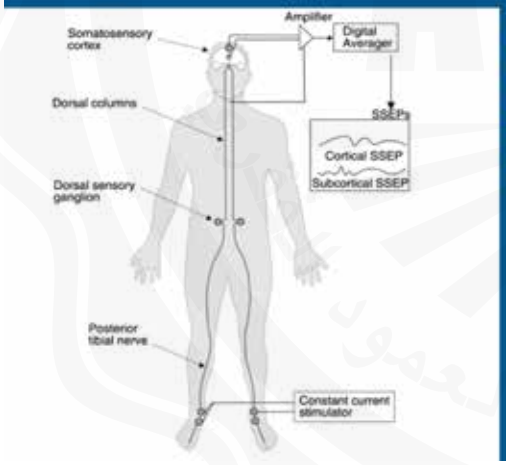

- LOWERS SSEP: WE STIMULATE THE POSTERIOR TIBIAL NERVE (40-60MA)
- UPPERS SSEP: WE STIMULATE THE MEDIAN OR ULNAR NERVE (20-30MA)

These are Somatosensory Evoked Potentials (SSEP) recorded from left and right hand

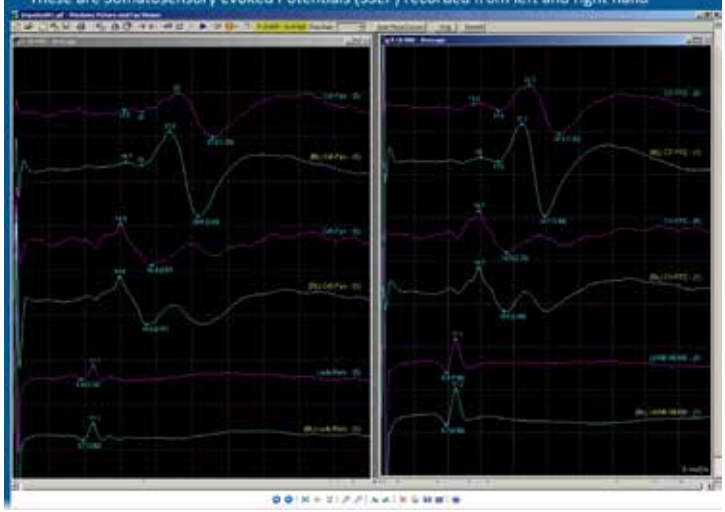

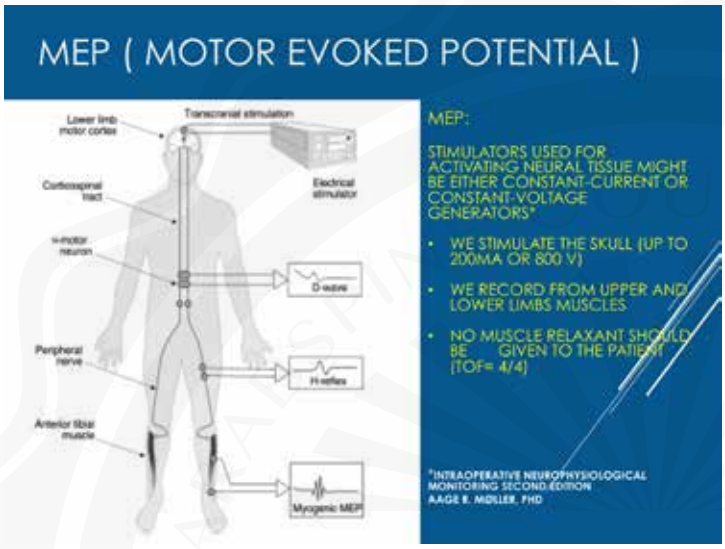

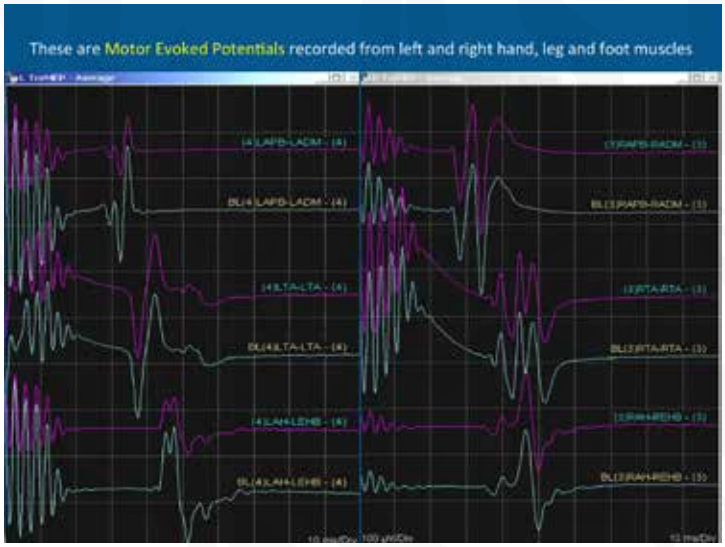

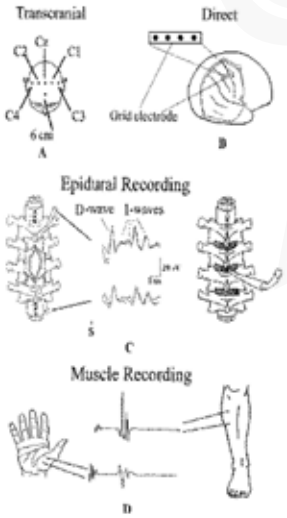

D-Wave Recording

RECORDING OF THE RESPONSE FROM THE SPINAL CORD IN AN OPERATION FOR A SPINAL CORD TUMOR, USING TWO CATHETER ELECTRODES EACH WITH THREE CYLINDER ELECTRODES, ONE PLACED CAUDAL AND ONE PLACED ROSTRAL (FOR CONTROL PURPOSES) TO THE SURGICAL FIELD.
THE TOP RECORDING SHOWS THE RESPONSE THAT APPROACHES THE TUMOR REGION AND THE LOWER RECORDINGS SHOW THE RESPONSE HAVING PASSED THE TUMOR REGION.
THE RIGHT ILLUSTRATION SHOWS PLACEMENT OF AN EPIDURAL ELECTRODE IN AN OPERATION WHERE THE SPINAL CORD WAS NOT EXPOSED.

(ADAPTED FROM: DELETIS V, SHILS JL, EDS. *NEUROPHYSIOLOGY IN NEUROSURGERY.* AMSTERDAM: ACADEMIC PRESS; 2002. AND REF. 52.)*

*INTRAOPERATIVE NEUROPHYSIOLOGICAL MONITORING SECOND EDITION
AAGE R. MØLLER, PHD

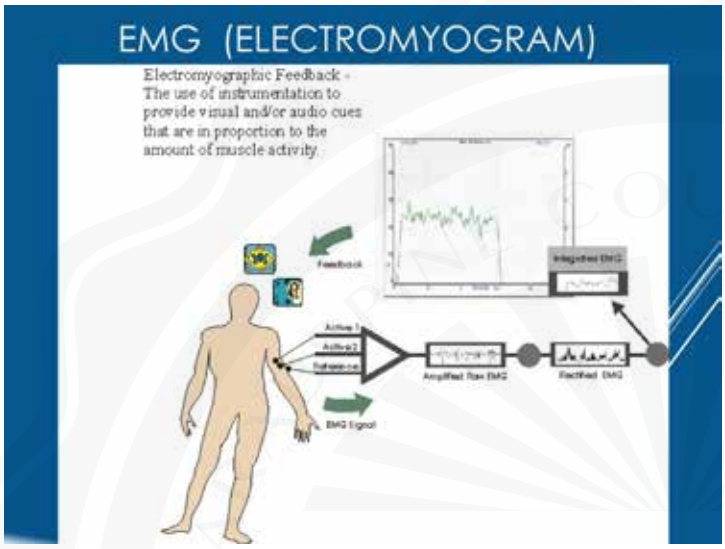
EMG (ELECTROMYOGRAM)
Electromyographic Feedback - The use of instrumentation to provide visual and/or audio cues that are in proportion to the amount of muscle activity.
Feedback
Integrated EMG
Active 1
Active 2
Reference
Amplified Raw EMG
Rectified EMG
EMG Signal

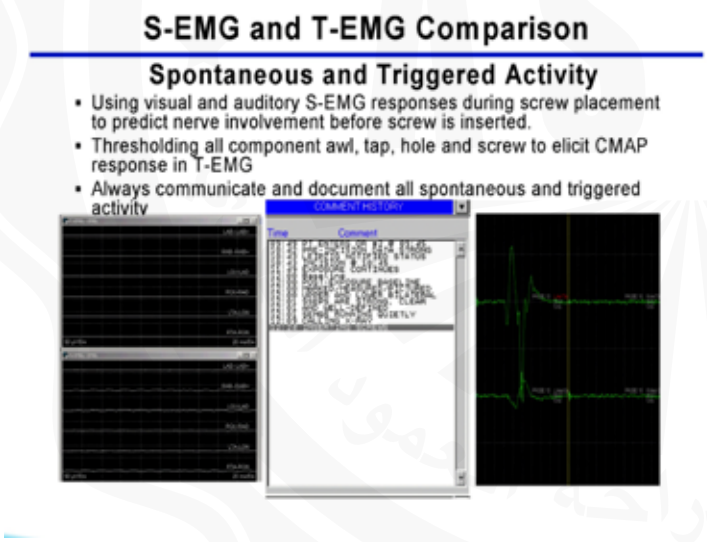
S-EMG and T-EMG Comparison
Spontaneous and Triggered Activity
• Using visual and auditory S-EMG responses during screw placement to predict nerve involvement before screw is inserted.
• Thresholding all component awl, tap, hole and screw to elicit CMAP response in T-EMG
• Always communicate and document all spontaneous and triggered activity
COMMENT HISTORY
Time
Comment

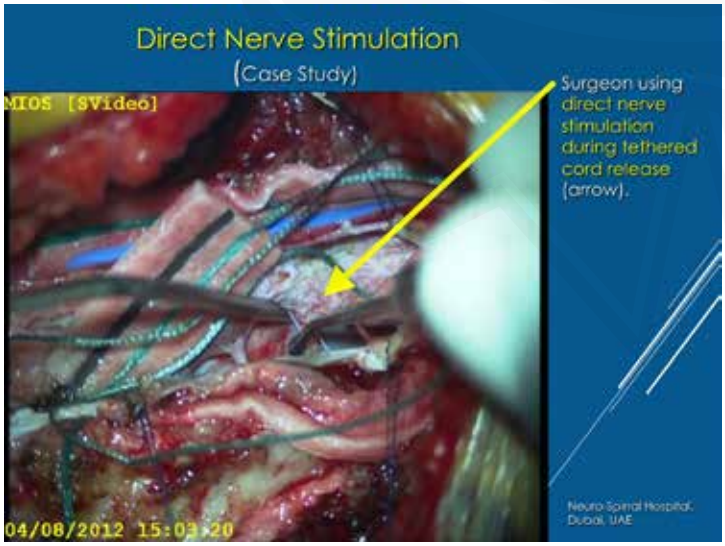
Direct Nerve Stimulation
(Case Study)
MIOS [SVideo]
Surgeon using direct nerve stimulation during tethered cord release (arrow).
04/08/2012 15:03:20
Neuro Spinal Hospital, Dubai, UAE

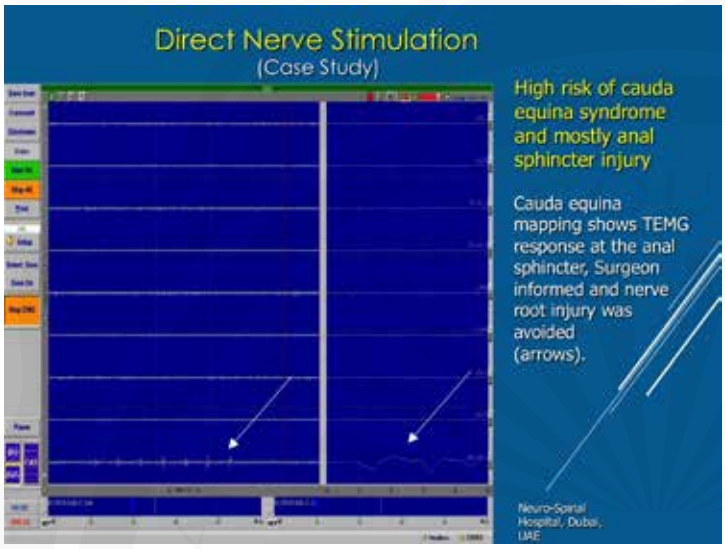
Direct Nerve Stimulation
(Case Study)
High risk of cauda equina syndrome and mostly anal sphincter injury
Cauda equina mapping shows TEMG response at the anal sphincter, Surgeon informed and nerve root injury was avoided (arrows).
Neuro-Spinal Hospital, Dubai, UAE

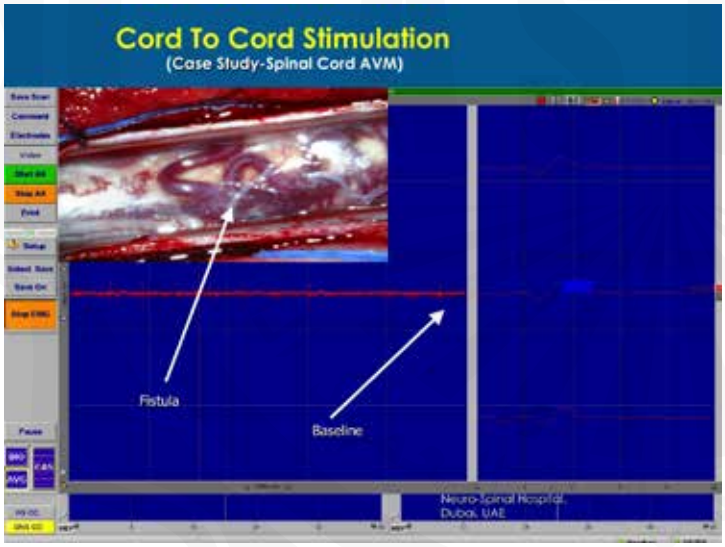
Cord To Cord Stimulation
(Case Study-Spinal Cord AVM)
Fistula
Baseline
Neuro-Spinal Hospital, Dubai, UAE

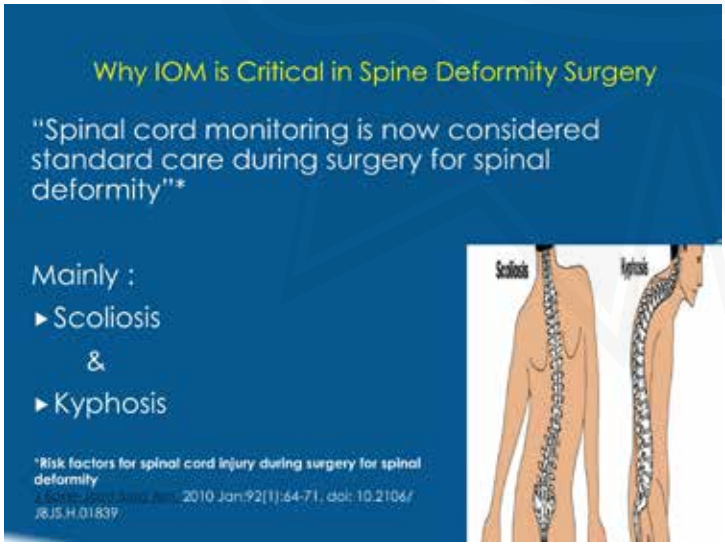
Why IOM is Critical in Spine Deformity Surgery
"Spinal cord monitoring is now considered standard care during surgery for spinal deformity"*
Mainly :
▸ Scoliosis
&
▸ Kyphosis
*Risk factors for spinal cord injury during surgery for spinal deformity
2010 Jan;92(1):64-71, doi: 10.2106/JBJS.H.01839
Scoliosis
Kyphosis

EVENTS THAT NEED MONITORING IN SPINE DEFORMITY SURGERY

In general, there are Several major events:

- Long Spinal cord involvement
- Long surgery time and potential for bleeding/ cord ischemia
- Multi level Instrumentation

And most important:

"The possibility of Spinal cord injury during correction and rotation"*

*"These maneuvers has the potential to stretch or impinge upon the neural elements , resulting in spinal cord injury"

Spine Deformity Surgery
Intraoperative Neurophysiology: A Comprehensive Guide to Monitoring and Mapping
By Mirela V. Simon, MD

NEUROLOGICAL COMPLICATIONS AFTER SPINE AND SPINAL CORD SURGERIES

Statistics and history*:

- In 1975, a review by MacEwen et al. over 7,000 spine surgeries revealed an incidence of neurologic complications of less than 1%.
- The Scoliosis Research Society (SRS) in 1991 reported an incidence of neurological deficit after all forms of spinal surgery around 1.6%.
- The SRS reported that in 2005 the incidence of neurological deficits after surgery for scoliosis was about 1.2% (0.1% complete cord, 0.4% incomplete cord, 0.7% nerve root)

* EUR SPINE J. NOV 2007; 16(SUPPL 2):229-231.

CLINICAL QUESTION

- Does IOM with SSEPs and TceMEPs predict adverse surgical outcomes?

In the Report of the Therapeutics and Technology Assessment Subcommittee
of the American Academy of Neurology (AAN) and the American Clinical Neurophysiology Society*

*the American Academy of Neurology

REPORT CONCLUSION*

- IOM is established as effective to predict an increased risk of the adverse outcomes of paraparesis, paraplegia, and quadriplegia in spinal surgery (4 Class I and 7 Class II studies).

*the American Academy of Neurology

AAN RECOMMENDATION*

- Surgeons and other members of the operating team should be alerted to the increased risk of severe adverse neurologic outcomes in patients with important IOM changes (**Level A**).

Level A = **Established** as effective

*the American Academy of Neurology

"AAN REPORT" HOW IOM CAN HELP?*

- Anesthesiologists and surgeons are able to intervene in a variety of ways when IOM raises warnings:
  - Reduce the degree of distraction
  - Adjust retractors
  - Remove or adjust grafts or hardware
  - Re-implant or unclamp arteries
  - Minimize remaining portion of surgery
  - Check a wake-up test
  - Increase BP and keep MAP above 70

*the American Academy of Neurology

MULTI MODALITIES MONITORING

"Combined somatosensory (SSEP) and motor evoked potential (MEP) monitoring allows the detection of early spinal cord dysfunction in most patients."*

Also we should use: SEMG/TEMG

For instrumentation and nerve root Protection.

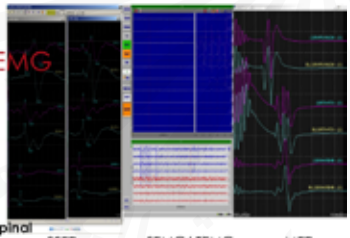

*Risk factors for spinal cord injury during surgery for spinal deformity
J Bone Joint Surg Am. 2010 Jan;92(1):64-71. doi: 10.2106/JBJS.H.01839

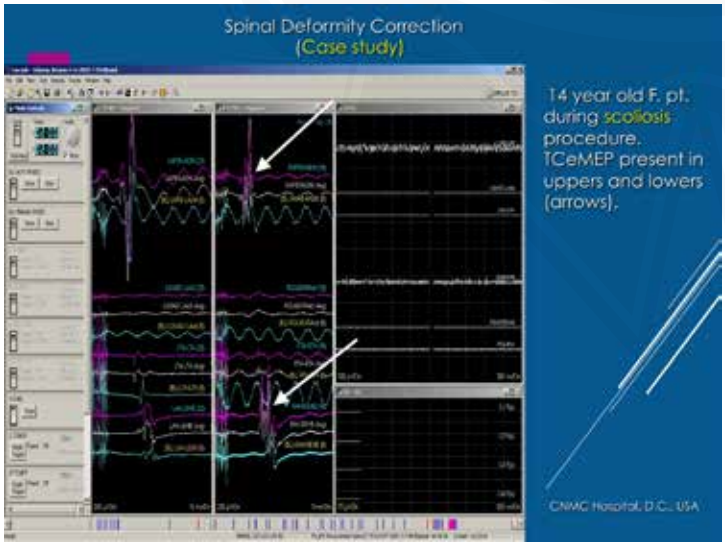

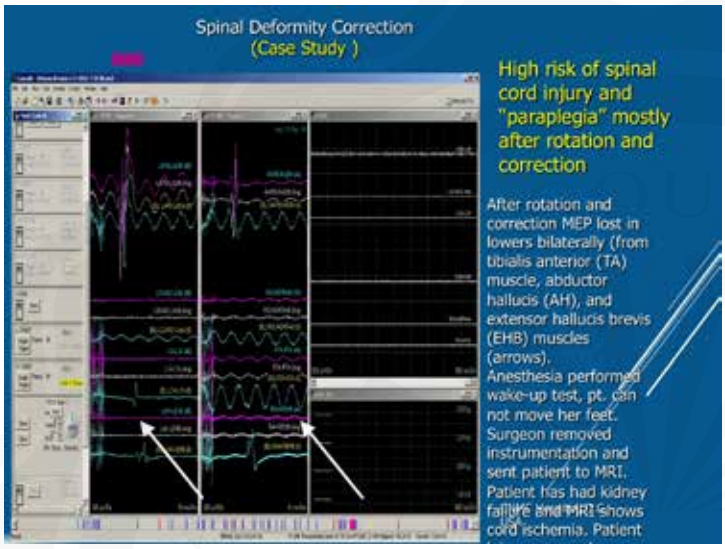

▸Conclusion:

- Spine deformity surgery carry's a high risk of cord injury mainly during correction and rotation.
- IOM is established as effective in predicting adverse surgical outcomes.
- The use of multi modalities IOM is a must to maximize neural protection.

"There has not been a single report in the literature of postoperative paraplegia in spite of intra-operatively preserved MEPs"*

* EUR SPINE J. NOV 2007; 16(SUPPL 2): 229-231

INDICATIONS FOR POSTERIOR AND ANTERIOR APPROACHES

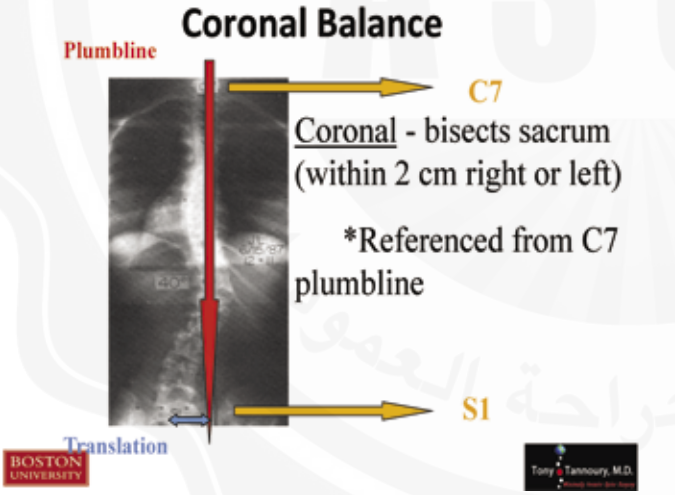

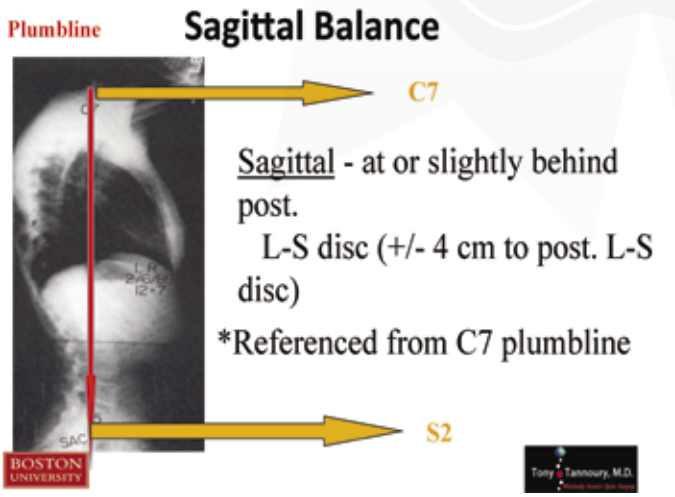

What is a Balanced Spine?
An Economical feature

- No Electrical Potential of posterior erector muscles

What does balance a spine ?
Close Relation between :

Legaye J, Duval-Beaupère G et al
Equilibre Sagittal du Rachis. Relations entre bassin et Courbures rachidiennes sagittales en position debout.
Rachis 1993,215-226

1. Pelvic Parameters
2. Spinal Parameters

The Sagittal Balance

Fundamentals =

Works of Mrs Duval-Beaupère
Rachis 1993, 215-226
Eur.Spine J. 1998, 99-103
Revue du rhumatisme 2004, 105-119
Eur.Spine J. 2006, 415-422

Works of the French scoliosis Group (GES):
Guigui, Marty, Roussouly

ASSESSMENT OF SPINE BALANCE

1- Know -Determine the exact values of spino-pelvic parameters according to PELVIC INCIDENCE!!

2- Evaluate the sagittal alignment of the patient

(3)- Determine the correction angle requested to restore a good sagittal balance

(4)- Select the appropriate surgical technique
- needed angle
- shape of the kyphotic deformity

BOSTON UNIVERSITY

Tony Tannoury, M.D.

Cervical Deformities

Flexible

Fixed

Flexible Deformity

- Anterior Only
- Anterior + Posterior
- Posterior only

80 Yr Old lady, s/p two cervical surgeries

CT Scans

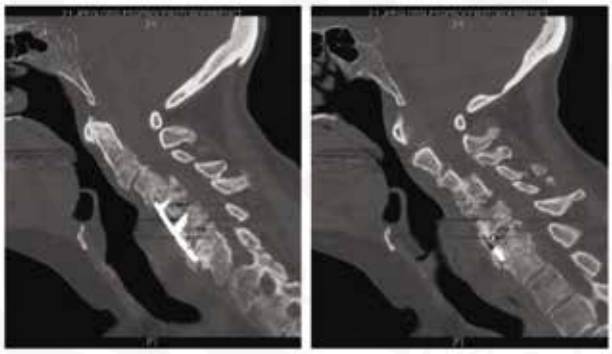

10 weeks post surgery

10 weeks post surgery

Patient

- HPI – 28 male with neck pain and inability to extend neck
- PMH – denies

X-rays

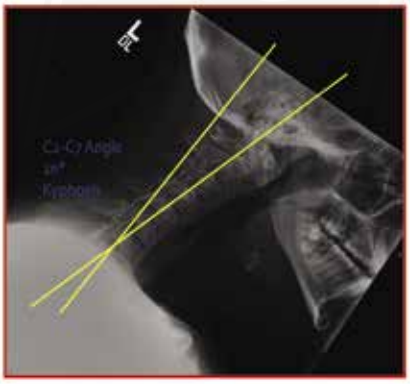

Imaging

- Chin-Brow Angle
- Occiput-to-wall Distance
- Sagittal balance

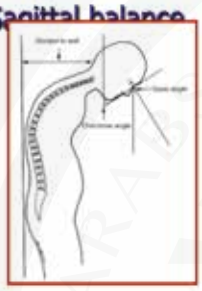

CT Scan

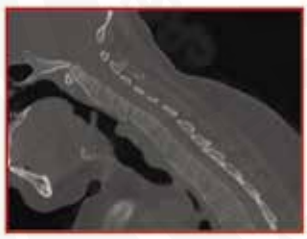

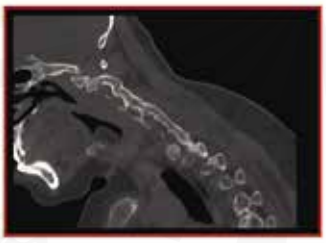

Posterior C7 Substraction OSTEOTOMY

What was done

4 Months Post-Operatively

THORACO-LUMBAR DEFORMITIES

FIRST: KNOW YOUR DISEASE
BOSTON UNIVERSITY
Tony J. Tannoury, M.D.

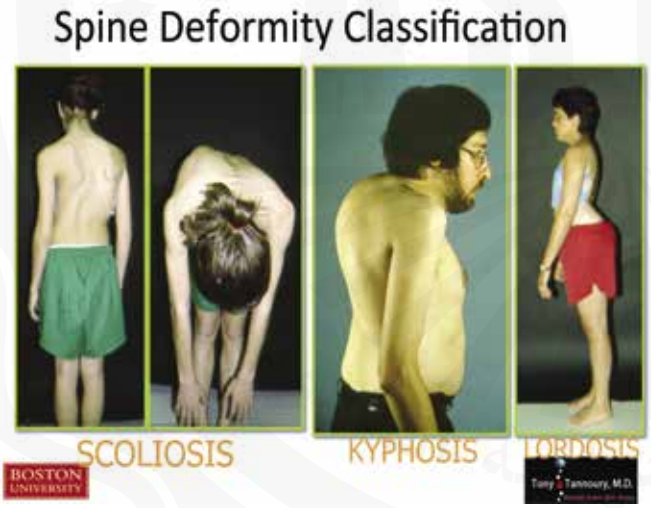
Spine Deformity Classification
SCOLIOSIS
KYPHOSIS
LORDOSIS
BOSTON UNIVERSITY
Tony J. Tannoury, M.D.

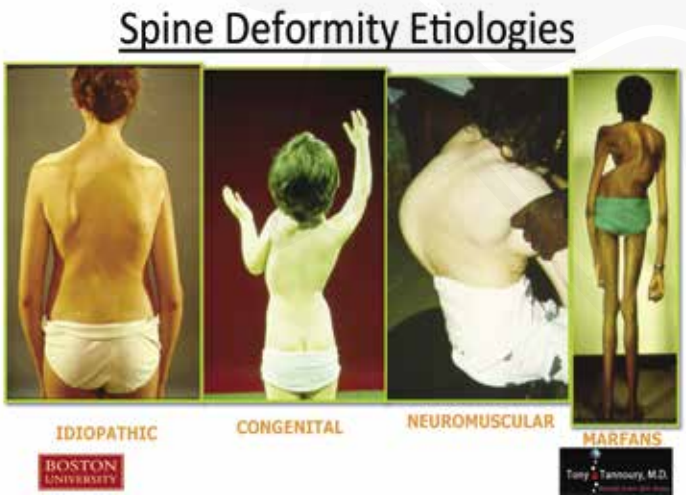
Spine Deformity Etiologies
IDIOPATHIC
CONGENITAL
NEUROMUSCULAR
MARFANS
BOSTON UNIVERSITY
Tony J. Tannoury, M.D.

Spine Deformity Etiologies

- Neurofibromato

BOSTON UNIVERSITY

Scoliosis

IDIOPATHIC MOST COMMON

INFANTILE JUVENILE ADOLESCENT ADULT

BOSTON UNIVERSITY

Tony J. Tannoury, M.D.

DEFINITION - SAGITTAL IMBALANCE (SI) SYNDROME

BOSTON UNIVERSITY

Tony J. Tannoury, M.D.

ETIOLOGY - SI SYNDROME

LIFE IS A KYPHOSING EVENT!!

- Settling of a long fusion done without structural grafting or four-point fixation of the sacrum/pelvis.
- Breakdown below a long fusion.
- Breakdown above a degenerative fusion.
- Post-traumatic kyphosis.

BOSTON UNIVERSITY

Tony Tannoury, M.D.

ETIOLOGY - SI SYNDROME

- Severe degenerative disc disease (loss of anterior column height).
- Systemic.
  - **Osteoporosis.**
  - **Ankylosing spondylitis.**
- Scoliosis fusion plus a spondylo-listhesis fusion.

BOSTON UNIVERSITY

Tony Tannoury, M.D.

Etiology

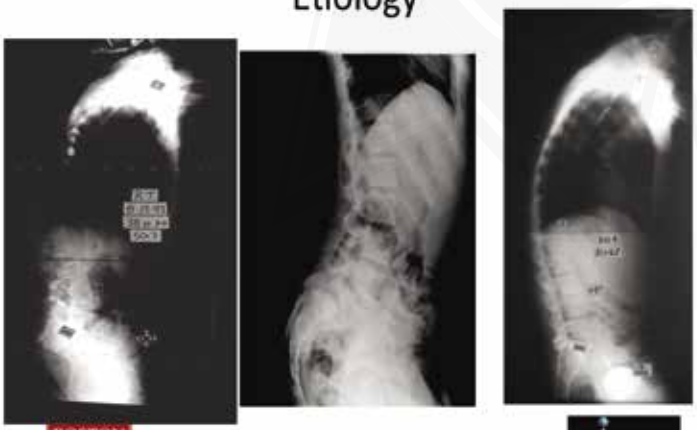

BOSTON UNIVERSITY

Tony Tannoury, M.D.

Etiology

PARTIAL PULLOUT OF S1 SCREWS

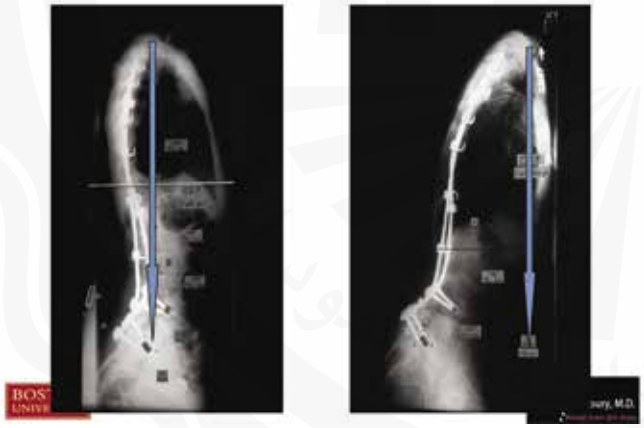

Deformity Treatment in the Early Days

Pediatric coronal deformity correction has become more predictable and safer surgery

But

How about sagittal plane correction and especially when It affects the elderly population

BOSTON UNIVERSITY

Tony Tannoury, M.D.

Adult deformities

- Technical Aspects and Results More Complex and more demanding than Adolescent
- Gratifying Results Obtained in Majority of Patients
-
- ONLY WHEN:
-
- Respect Rx concepts which are:

BOSTON UNIVERSITY

Tony Tannoury, M.D.

GENERAL CONCEPTS:

- ESTABLISH A BALANCED SPINE
- SOUND MECHANICAL FIXATION
- ADDRESS ANY NEUROLOGIC COMPROMISE, CORD OR RADICULAR
- DO NO HARM!!

BOSTON UNIVERSITY

Tony Tannoury, M.D.

Determination by radiographic and clinical factors

BOSTON UNIVERSITY

Tony Tannoury, M.D.

FIXED VS FLEXIBLE - CLINICAL EVALUATION

- Upright stance*/gait
- Prone and push/prone
- Supine (check for hips/Knees flexion contractures)
- *Exam with and without knee flexion

BOSTON UNIVERSITY

Tony Tannoury, M.D.

Knee flexion for sagital imbalance

BOSTON UNIVERSITY

Tony Tannoury, M.D.

Mod. Flexible Coronal/Sagittal Imbalance

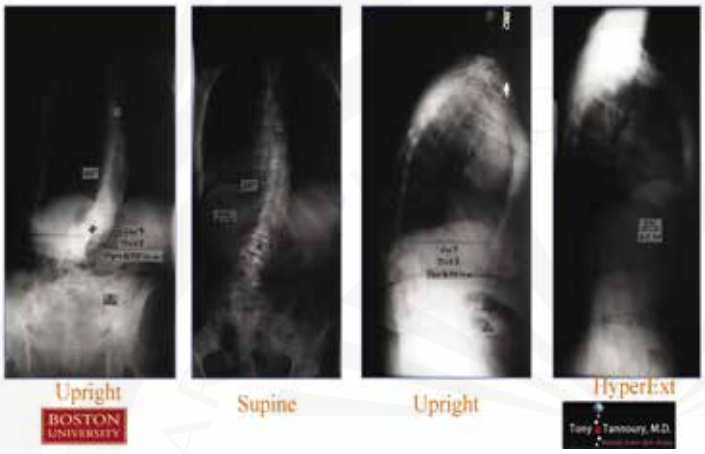

SUPINE HYPEREXTENSION X-RAY

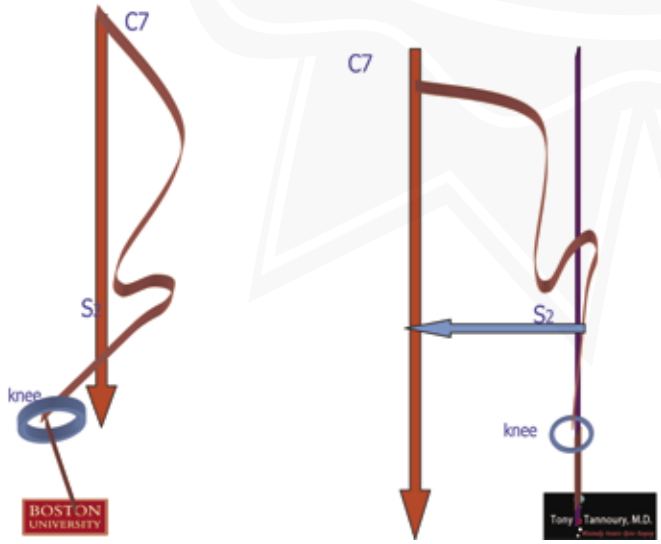

FIXED SAGITTAL INBALANCE

Knees Bent | Knees Straight

FIXED SAGITTAL IMBALANCE (FSI)

3 RADIOGRAPHIC SCENARIOS

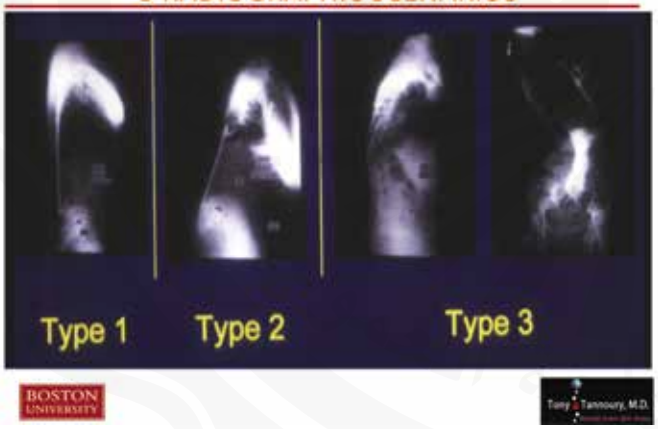

SAGITTAL IMBALANCE: SPECTRUM OF THE DISORDER

- Type I: segmental sagittal deformity
  - Segmental hypolordosis or kyphosis
  - C7 over L5/S1
  - "Triangular" discs below but not severe degenerative disc disease

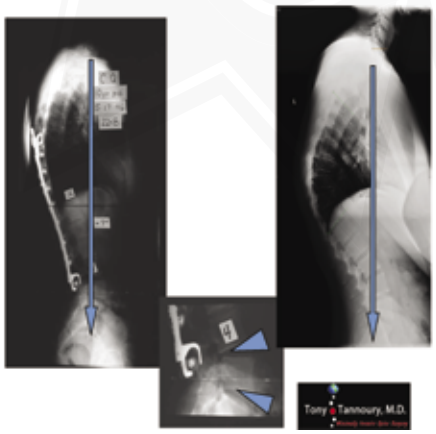

SPECTRUM OF DEFORMITY

- Type II - patient segmentally & globally flat and out of balance.
  - C7 in front of L5/S1.
  - Patient unable to compensate by hyperextending segments below OR above.

BOSTON UNIVERSITY

Type 3

- Global imbalance:
  - Sagittal
  - coronal

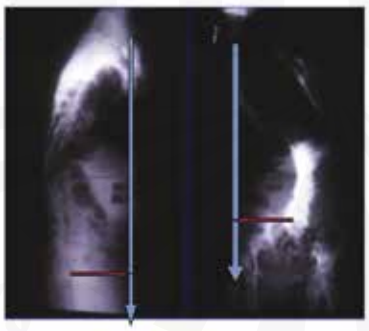

BOSTON UNIVERSITY

Tony Tannoury, M.D.

Type 3 - Degen Scoliosis - 5 previous ORs

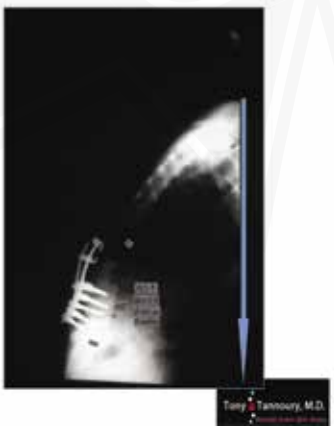

BOSTON UNIVERSITY

Treatment Choice

- Anterior
- Posterior
- Anterior + Posterior

BOSTON UNIVERSITY

Tony Tannoury, M.D.

All pedicular screws constructs have stronger power of correction over hybrid constructs and all hooks constructs

	Screws	Hybrid	Hooks	ANOVA (P)
Correction (deg)	36.65	30	27.5	0.008
% Correction	0.66	0.49	0.51	0

Tony Tannoury, M.D.

Idiopathic Scoliosis
SURGICAL TREATMENT

- Anterior Fusion with Instrumentation
  - Lumbar/Thoracolumbar
  - Thoracic Curves
- Curve Correction: 70-100%
- Fewer Levels Fused
- Becoming less and less utilized with the pedicle screws and post osteotomies

BOSTON UNIVERSITY

Tony Tannoury, M.D.

ANTERIOR

Idiopathic Scoliosis

- Anterior/Posterior Fusion with Instrumentation
  - –Severe Curves >90-100%
  - –Failed Fusions

BOSTON UNIVERSITY

NK 14 Y/O F
S/P ASF+PSF

PRE
POST
PRE
POST

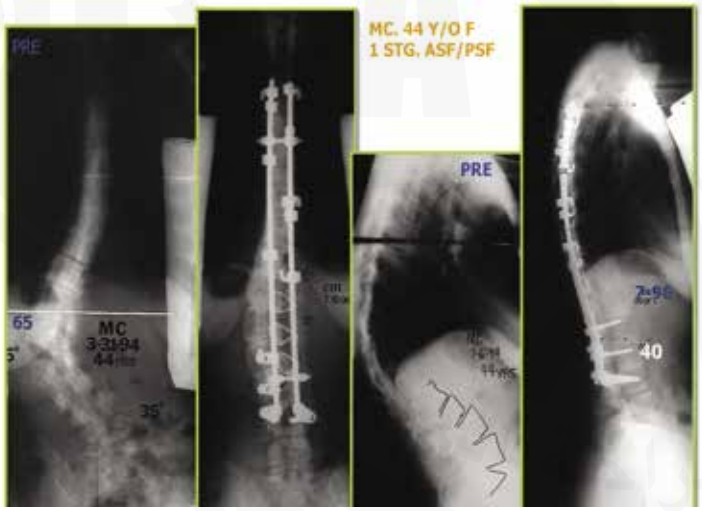
PRE
MC. 44 Y/O F
1 STG. ASF/PSF
PRE
65
MC
40

Video Assisted Thoracoscopic Surgery:
RIBS
SPINE
LUNG
SPINE
SCARS

Video Assisted Thoracoscopic Surgery

- Release Operation for severe stiff curves
- Good Fusion Success
- Fractional Curve Correction Difficult
- Kyphogenic
  - Rigid Deformity in Adult
- Learning Curve Steep

BOSTON UNIVERSITY

Tony Tannoury, M.D.

10+8 girl. Idiopathic Scoliosis
ALL Posterior Pedicle Screw correction

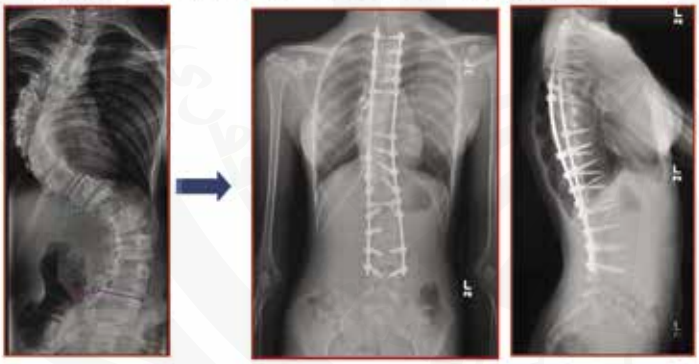

BOSTON UNIVERSITY

Tony Tannoury, M.D.

Kyphosis
ETIOLOGIES

- Postural
- Scheuermann
- Congenital
- Neuromuscular

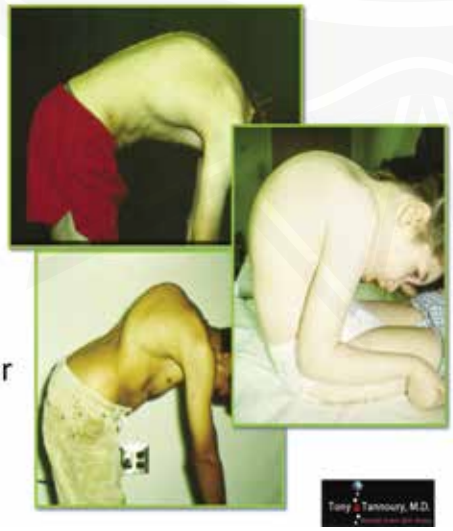

BOSTON UNIVERSITY

Tony Tannoury, M.D.

Scheuermann Kyphosis

- Observe Curve < 50 , with Exercises
- Braces for Curve 60-70
  - Painful
  - Immature Patients
- Surgery for Curves >75 (Immature Patients)
  - Large Curves Unacceptable to Patient

BOSTON UNIVERSITY

Tony Tannoury, M.D.

Scheuermann Kyphosis
OPERATIVE TREATMENT

- Posterior Fusion, Curve < 50 in Ext
- Anterior/Posterior Fusion, >75 in Ext
  - Adults
  - With pedicle screws, Anterior is rarely needed
- VATS
  - Rarely used
  - Allows More Levels Released
  - Minimal Scar
  - Early Recovery

BOSTON UNIVERSITY

Tony Tannoury, M.D.

Kyphosis :Anterior/posterior fusion

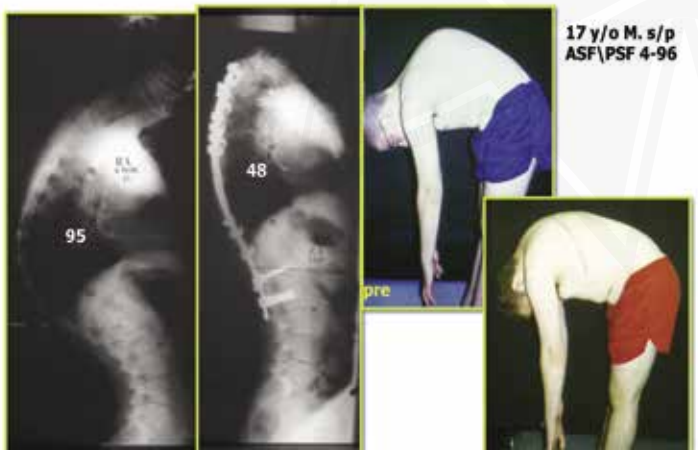

17 y/o M. s/p
ASF\PSF 4-96

All Posterior

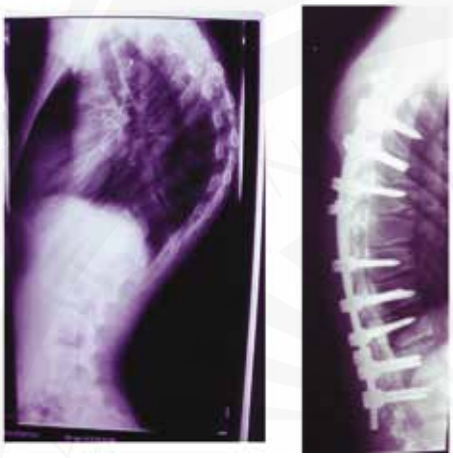

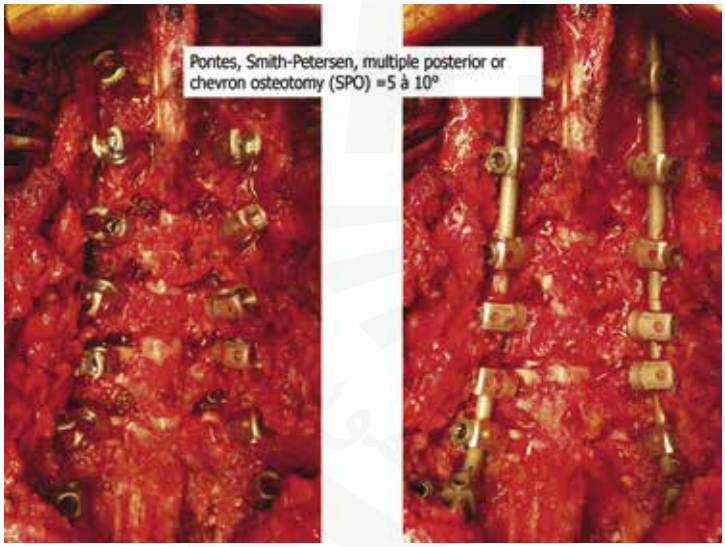

Scheuermann Kyphosis: All Posterior. Wide facetectomies + Multiple Ponte's

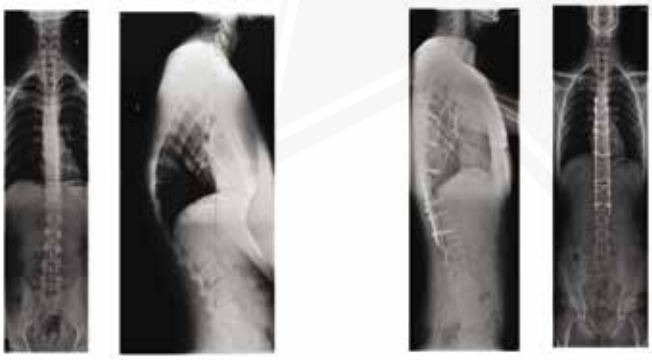

The Introduction of Pedicle Screws and perfecting osteotomies

Less anterior surgeries
More of
ALL Posterior Surgeries

TYPES OF OSTEOTOMIES

- SPO = Smith-Peterson osteotomy
- PSO = Pedicle Subtraction osteotomy
- APO = Combined Ant. and Post. osteotomies
- VCR = Vertebral Column Resection
- Y Osteotomy

BOSTON UNIVERSITY

Tony Tannoury, M.D.

SMITH-PETERSON OSTEOTOMY

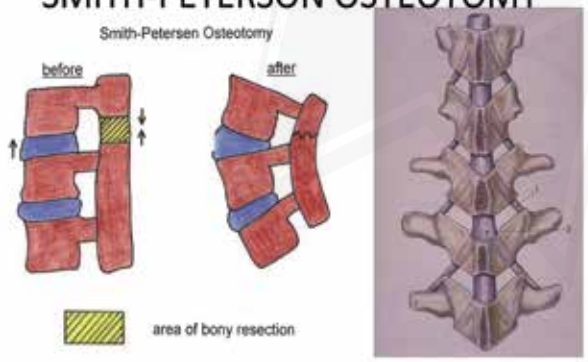

•Opens anterior column, hinges on middle column, closes posterior column

BOSTON UNIVERSITY

Tony Tannoury, M.D.

SPO

- SPO - 1 mm of bone stock resected posteriorly corresponds to 1° of sagittal lordosis correction for ~5-15° maximum correction per level
- Can correct coronal plane imbalance via asymmetric coronal plane osteotomy

BOSTON UNIVERSITY

Tony Tannoury, M.D.

PEDICLE SUBSTRACTION OSTEOTOMY

- Shorten post.
- column
- Shorten middle column
- Hinges on ant. column

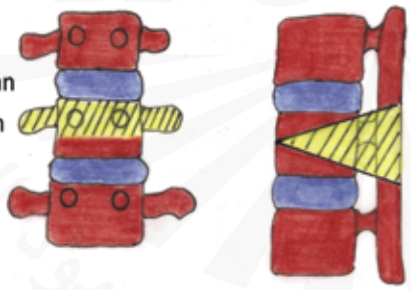

BOSTON UNIVERSITY

Tony Tannoury, M.D.

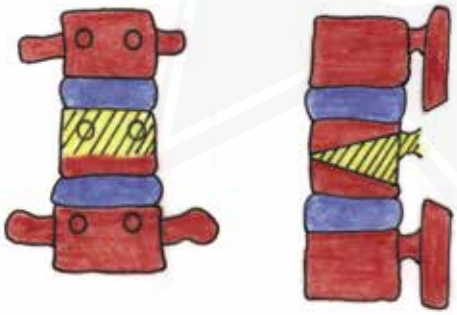

BOSTON UNIVERSITY

Tony Tannoury, M.D.

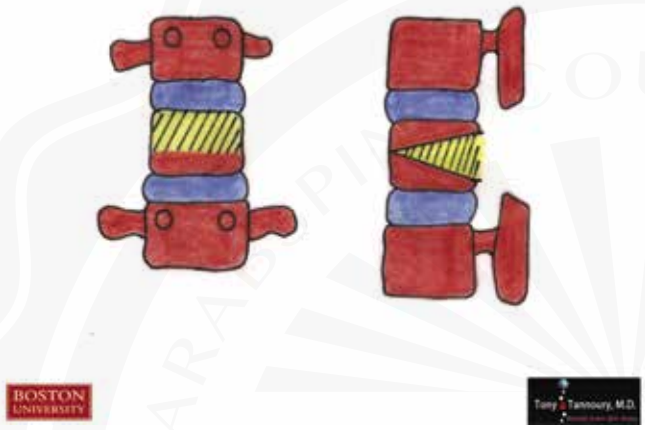
BOSTON UNIVERSITY
Tony J. Tannoury, M.D.

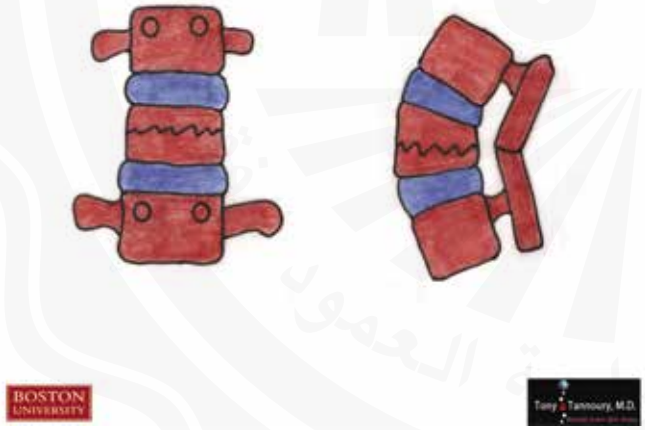
BOSTON UNIVERSITY
Tony J. Tannoury, M.D.

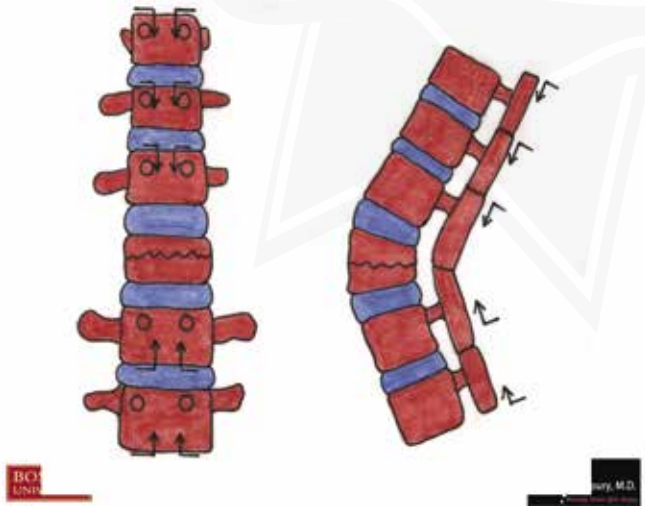

History

- 59 yo F with LBP
- MVA at age 12, multiple abdominal surgeries. Persistent LBP since the MVA
- 1st spine surgery at 30 yrs of age, followed by multiple (13) revisions incl. L3-4 fusion & removal of hardware
- Mobile pseudoarthrosis
- Leg symptoms stable since injury, R EHL 4/5

BOSTON UNIVERSITY

Tony Tannoury, M.D.

14 Spinal Surgeries.

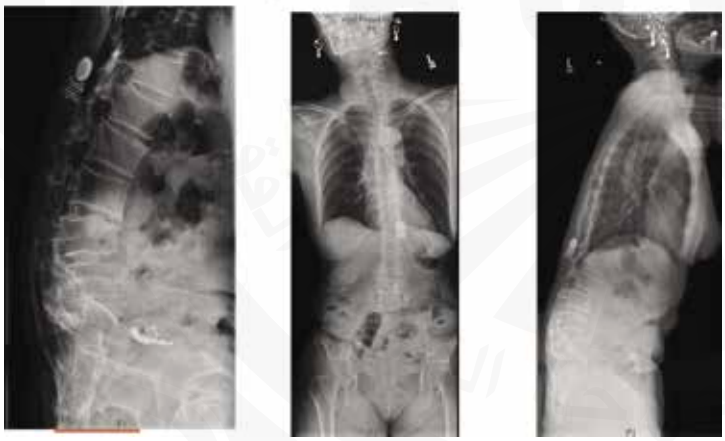

L2, L4 PSO.

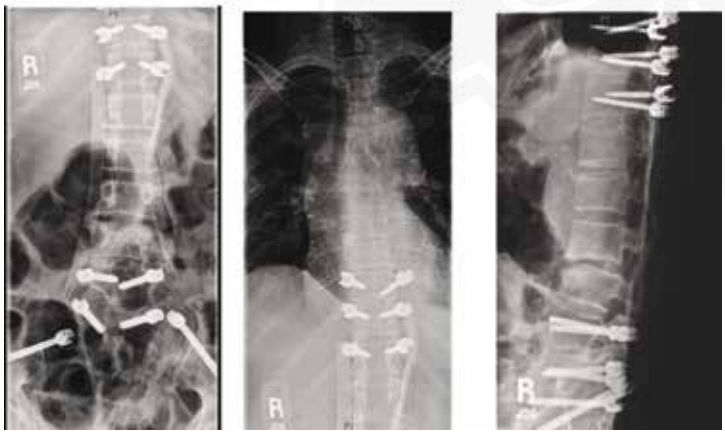

L2, L4 PSO: Smooth curvature
8 months follow up

2 yrs. Post Op.

VCR

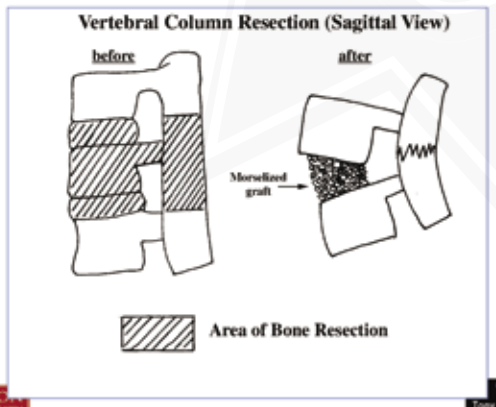

M.A. 44/F with congenital deformity, had Lumbar fusion surgery at 8 y/o!!!

Cc: back pain and deformity

Severe sharp kyphoscoliosis
Thoracic lordosis

X-Rays and CTscans

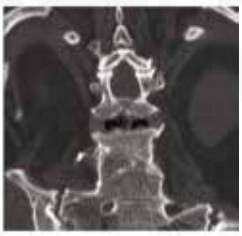

Post-op weakness (1/5) of right quadriceps, bledsoe brace applied; persistent left flank pain

L1, L2, L3 VCRs

Four rod technique

One month post-op: R quadriceps 3/5 strength, sensation intact; Left flank pain resolved spontaneously

3 months post-op: Doing well, wound infection resolved, R quads 4/5, L hypogastric pain resolved

Nicely balanced.

ANT-POST. Osteotomy

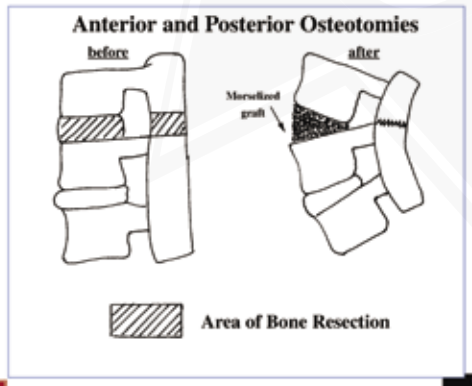

BOSTON UNIVERSITY

Tony Tannoury, M.D.

Y-Osteotomy

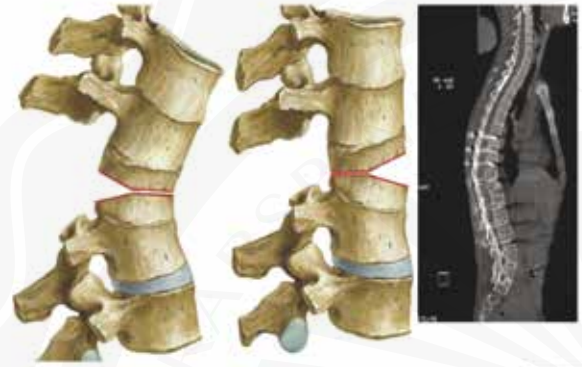

BOSTON UNIVERSITY

Tony J. Tannoury, M.D.

36 yo male

- Severe Thoracolumbar Kyphoscoliosis
- Note severe rotation of the vertebra at the apex of the deformity

BOSTON UNIVERSITY

Tony J. Tannoury, M.D.

T10, T11, T12 & L1 Congenital Fusion

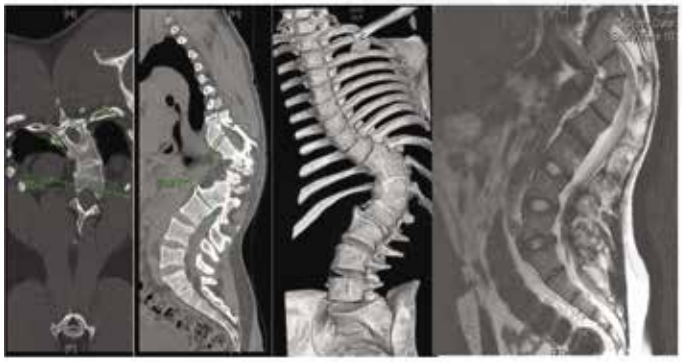

- Cobbs Angle of 45.8
- Kyphosis angle of 104.7
- Fused T10-L1 Vertebrae

BOSTON UNIVERSITY

Tony J. Tannoury, M.D.

Plan

- Corrective osteotomy
  - Correct Sagittal deformity
  - Correct Coronal Deformity

BOSTON UNIVERSITY

Tony Tannoury, M.D.

Osteotomy options

- Three column osteotomy- 'VCR'
- Y-shaped osteotomy performed here

BOSTON UNIVERSITY

Tony Tannoury, M.D.

Post-operative CT-scan

Cobbs angle of 8.5 degrees and local kyphosis of 8.4 degrees

Post-operative CT-scan

CT-scan-pre-op and post-op

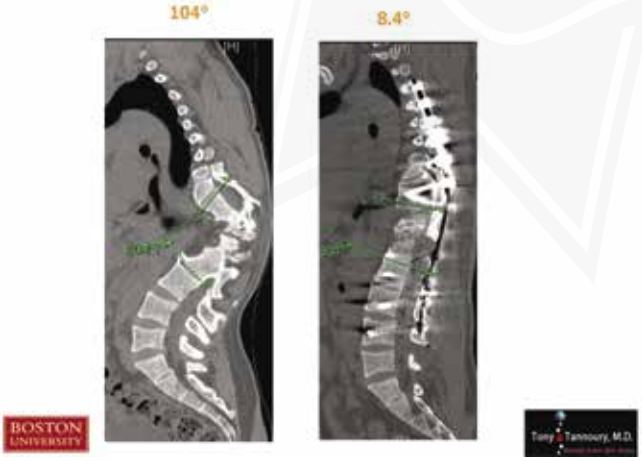

Smooth curve Osteotomy

3 months Follow up

Y-Osteotomy.
Note the anatomical spinal alignment

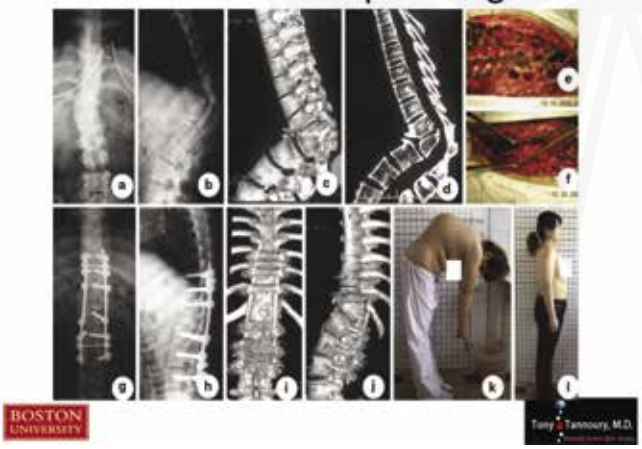

NO NEED for Cage placement

NO NEED to overbend the Rods such as PSO

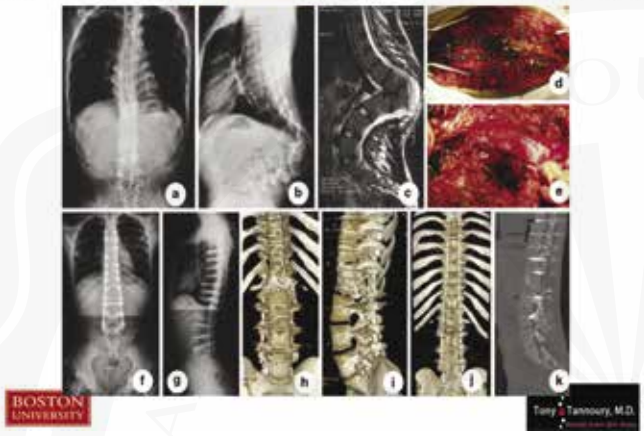

Lumbar deformities
most radical recent shift

- Ankylosed:
  - Osteotomy
- Non Ankylosed:
  - MIS ANT FUSION
  - Posterior MIS fusion

H&P

- 64 years old lady presenting with
- Radicular pains Left >right
- Persistent back pain
- Cosmetic deformity
- Inability to stand straight.
- S/P L5-S1 instrumented fusion In Germany 2013

PE

- Severe Deformity
- Diffuse paraspinal muscle tenderness
- Motors 4/5 in Left EHL
- Sensations reduced diffusely in left lower limb
- Severely restricted mobility due to pain

Radiographs

- Scoliotic deformity from T12-L5
- Cobbs angle of 72 degrees
- Note oblique pelvic take-off
- Coronal imbalance

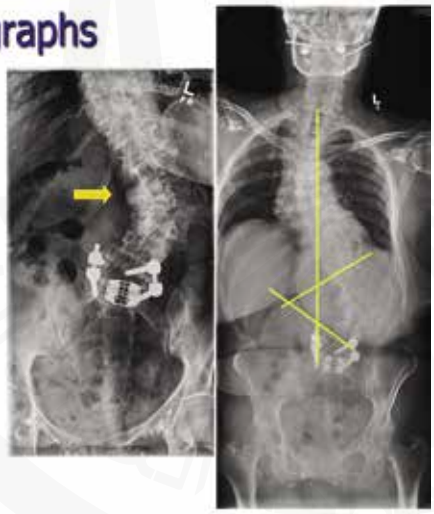

Radiographs

- Kyphotic deformity
- Sagittal imbalance

CT-SCAN

- Degenerative changes from T12 to S1 with oblique pelvic take-off
- Multiple level vacuum disks

MRI

- Severe degenerative changes from T11-S1

Rx Options

- All Posterior
- Anterior and Posterior
- Levels!!

Stage 1 : MIS Anterior

- Anterior Osteotomy L1-2, L2-3
- Anterior interbody cage placement
- Cobb angle reduced to less than 20 degrees
- Lumbar lordosis 65 degrees restored

Stage 2 : posterior

- T10-S1 PSF
- Iliac fixation
- Cobb angle reduced to less than 10 degrees
- Sacro-pelvic balance restored

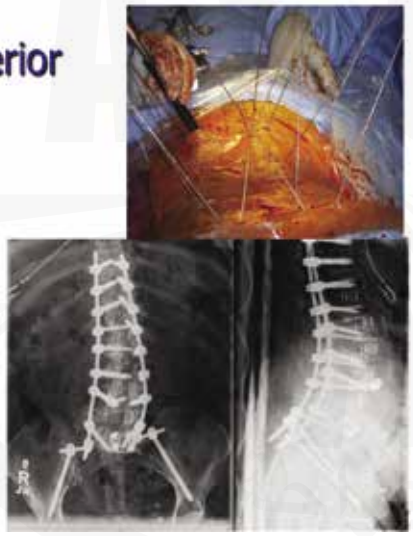

Follow-up x 8 weeks

-Restored Coronal balance
-Patient mobilizing FWB with a Cane

Follow-up x 8 weeks

-Restored Sagittal balance
-Patient mobilizing FWB with a Cane

Summary: TREATMENT SENARIOS/OSTEOTOMIES

- Posterior Smith-Petersen osteotomies only.
- Anterior discectomies along with Smith-Petersen osteotomies.
- Morselized grafting anterior vs. structural grafting.
- If a solid anterior and posterior fusion, separate anterior and posterior osteotomies.
- Pedicle subtraction/posterior 3-column vertebral resection osteotomy.
- Y-Osteotomy

BOSTON UNIVERSITY

Tony Tannoury, M.D.

POSTERIOR APPROACH: PRINCIPLES AND TECHNICAL NOTES THORACO-LUMBAR

Workhorse

Direct access:
- spinous process
- lamina,
- facets
- pedicles
- lateral/posterior vertebral body

- Discectomy
- Laminectomy
- Posterolateral fusion
- PLIF/TLIF
- Costotransversectomy, Lateral extracavitary
- Osteotomy: Ponte, SPO, PSO, BDBO, VCR

Positioning

- Bony prominences, skin protection
- Eyes (consider Mayfield)
- Neutral neck
- Abdomen free
- Flexion if decompression only
- If fusion, need to extend hips

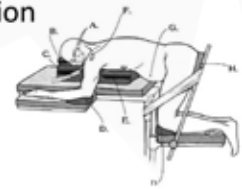

Edgecomb Br J Anes, 2008

- Subperiosteal

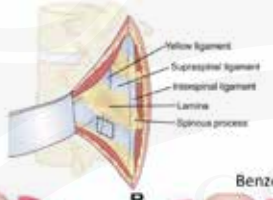

- Wiltse

- Para-midline

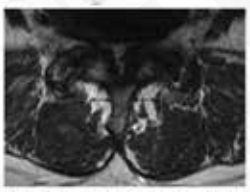

Moghimi et al, Eur Spine J 2016

Localization

- Identify transitional anatomy
- Radiographs mandatory
- Do not disrupt facet capsule or PLC until levels are confirmed
- Spinous process, transverse process, inferolateral facet, sublaminar, count ribs
- Pre-op PMMA, markers

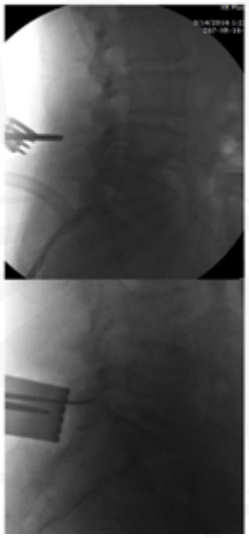

Exposure

- Hypotensive anesthesia, hemodilution
- Cellsaver, resuscitation protocol

- Meticulous dissection and hemostasis
- Limit extent of exposure
- Pack surgical field if not actively working there
- Decorticate as final step

Instrumentation

- Anatomic landmarks
- Fluoroscopic guidance
- O-arm
- Navigation

- Osteoporosis
  - Cement augmentation

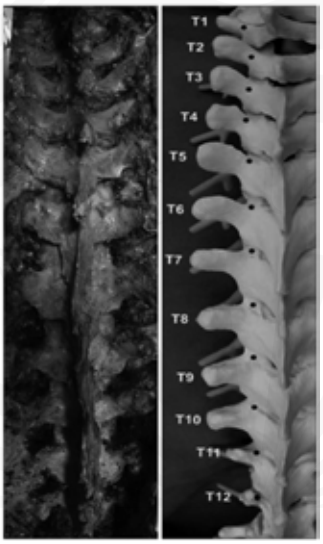

Lumbar Instrumentation

- Pre-operative assessment of rotation

- Triggered EMG
- Use lumbar decompression to palpate pedicles
- Pay attention to deformity

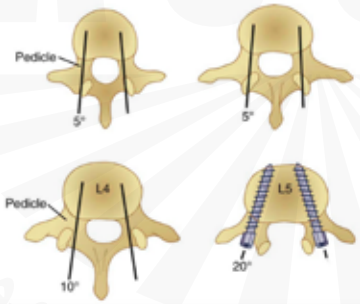

Sacroiliac fixation

- S1 tricortical
- Standard iliac
- S2 screw
- S2AI screws

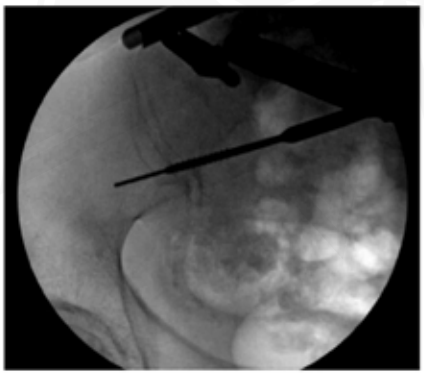

Decompression

- Identify and expose pars
- Detach flavum from caudal surface of cranial lamina
- Ronguer, Kerrison, High speed drill, osteotome
- Medial wall of pedicle is guide

Revision Decompression

- Careful review of pre-op imaging evaluation
- Preserve facet capsules and PLC
- Bony margins of previous decompression
  - Large blunt instruments

- Define dural margin
  - Fine angled curettes, Penfield #1
- Can often leave epidural fibrosis adhered to dura
- Pedicle as guide

Osteotomy

- Templating is key
- Adequate fixation is requisite
- Ensure complete decompression
- Breakable table

- Smith Peterson, PSO, BDBO, VCR
- Post correction long films mandatory
- Consider staging
- Neuromonitoring, wake-up test

Smith Peterson

- 1 degree/mm
- 10 degrees per level
- Can be performed asymmetrically
- 3 SPO = 1 PSO with less blood loss

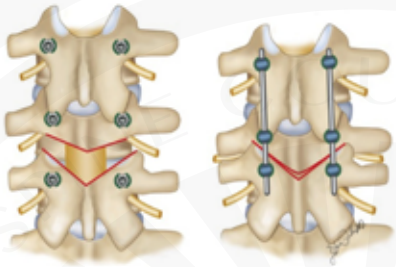

Pedicle Subtraction Osteotomy

- Adequate fixation
- 30-40 degree correction
- Sagittal/coronal
- Lock L4-S1
- Rod-rod domino, manua pressure, break table
- 3- or 4- rod construct

Bone Disc Bone Osteotomy

- Adequate fixation
- 35-60 degree correction
- Can supplement with anterior structural graft

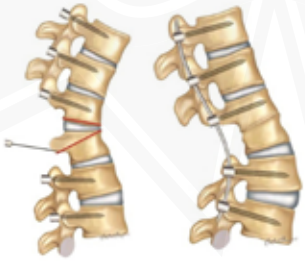

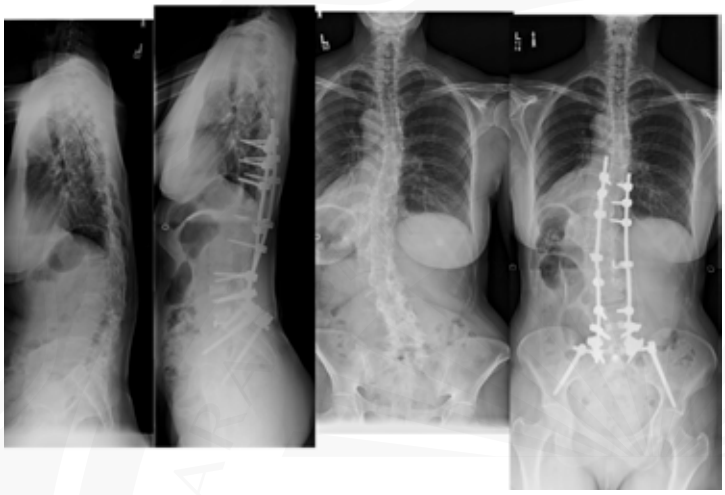

Vertebral Column Resection

- Powerful coronal and sagittal correction
- 35-40% complication rate
- 11.4-17.1% neurologic

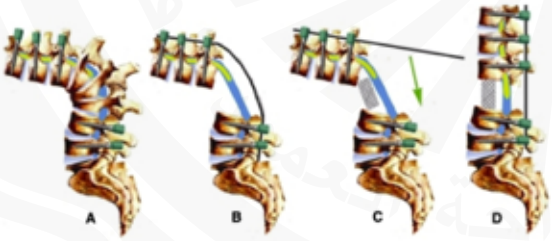

Rod Contouring

- Don't stress individual fixation point
- Rod holder with downward pressure on cranial end
- Stiff spine: in situ bending
- Multiple reduction towers

- "You can never bend too much kyphosis at the proximal end of the rod"

Miscellaneous Tips

- If durotomy during osteotomy with taut edges, can wait until osteotomy is closed to repair (redundancy)
- Decortication and grafting technique important, pay attention near screws and underneath rod connectors
- Two hands are better than one
- Most dangerous part of the case is whenever you lose focus

Key References

- Bridwell et al. Pedicle Subtraction Osteotomy for the Treatment of Fixed Sagittal Imbalance. JBJS 2004.
- Enercan et al. Osteotomies/spinal column resections in adult deformity. Eur Spine J. March 2013.

ANTERIOR APPROACH: PRINCIPLES AND TECHNICAL NOTES

Disclosures

- Depuy:
  - Consultant
  - Speaker Bureau
  - Research support
  - Royalty

BOSTON UNIVERSITY

Tony Tannoury, M.D.

Minimaly Access Spine Surgery...

- Less:
  - muscle damage (fusion disease)
  - deinnervation
  - blood loss
  - hospitalization
  - time off work

BOSTON UNIVERSITY

Tony Tannoury, M.D.

Reality of Current Minimal Access Spine Surgery...

- More technical
- More time consuming
- Has a steep learning curve
- Use a lot of fluoroscopy time
- Questions need answers:
  - Fusion for multilevel pathologies
  - Deformity correction
  - decompression

BOSTON UNIVERSITY

Tony Tannoury, M.D.

IS IT WORTH IT?

- If MIS is good for small cases:
  - One or two level stenosis
  - One level fusion
  - Etc…
- MIS should be ideal for much larger cases:
  - Tumors
  - Deformities
  - Trauma
  - Patients with significant co-morbidities

BOSTON UNIVERSITY

Tony Tannoury, M.D.

Learning Curve

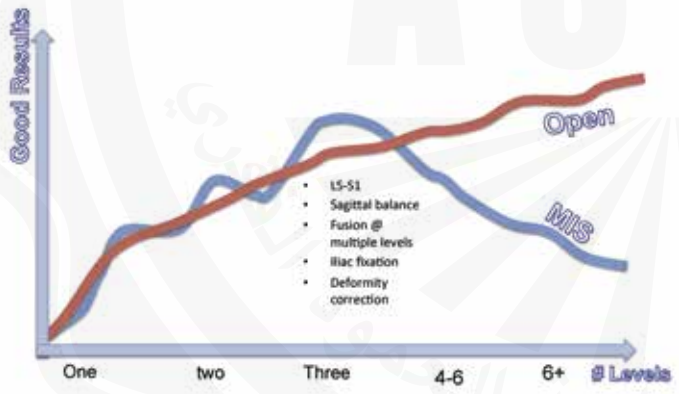

BOSTON UNIVERSITY

Tony Tannoury, M.D.

Challenges Of MIS surgeries

- L5-S1
- Fusion @ multiple levels
- Iliac fixation
- Deformity correction
  - Sagittal Balance
  - Coronal Balance
  - Axial derotation

BOSTON UNIVERSITY

Tony Tannoury, M.D.

Posterior Access: Good progress

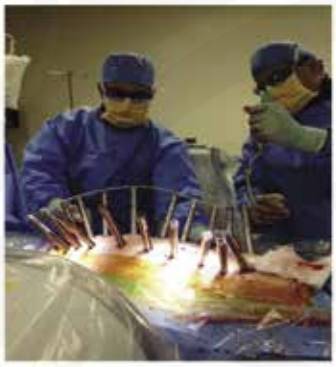

BOSTON UNIVERSITY

Tony Tannoury, M.D.

The Value of L5-S1

- Sagittal correction:
  - 15-20°from L5–S1alone
  - For Each 10° ⟹ SVL:80mm/
- Mechanical
  - Load sharing
- Biological
  - fusion

L5-S1: No interbody fusion

L5-S1: Insufficient interbody fusion

BOSTON UNIVERSITY

Tony Tannoury, M.D.

Must Achieve items

- Sagittal balance
- Coronal balance
- Spinal decompression
- Successful spinal fusion
- Mechanically sound fixation:
  - Proximal foundation
  - Distal foundation

BOSTON UNIVERSITY

Tony Tannoury, M.D.

Challenges of MIS for Deformity: three main questions

- How to achieve sagittal balance
  - ~~osteotomy~~
  - Interbody reconstruction
- How to achieve fusion
  - ~~Posterior~~
  - interbody
- Decompression:
  - ~~Direct: laminectomy facetectomy~~
  - Indirect: Spinal reduction Foraminal distraction

BOSTON UNIVERSITY

Tony Tannoury, M.D.

MIS Fusion Options

- Postero-lateral

- Posterior interbody

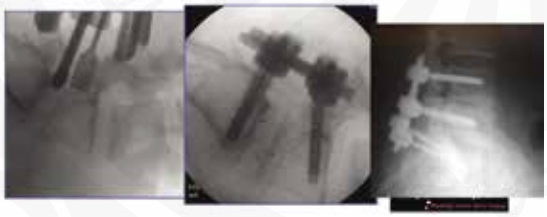

BOSTON UNIVERSITY

Direct anterior: Great Spinal work through Hostile territory

BOSTON UNIVERSITY

Tony Tannoury, M.D.

Promising techniques
MIS Lateral

- Straight lateral surgery (XLIF, DLIF, Lateral Cougar etc...)
  - Lateral decubitus position
  - Incision at lateral border of erector spinae
  - Dilates through iliopsoas
    - "Finger assisted"
    - Neuromonitoring

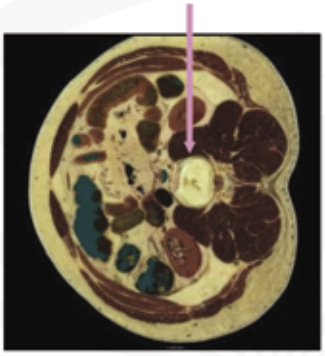

BOSTON UNIVERSITY

Tony Tannoury, M.D.

Issues to resolve with the direct lateral:

- The safety for the Lumbo-sacral plexus
- Ability to perform Proximal (L1-2, L2-3) and Distal (L4-5, L5-S1) levels
- Sagittal balance reconstruction
- Preservation of the end plates
  - Later cage subsidence
  - Recurrence of stenosis
- Ability to reconstruct the anterior spine
- Radiation use
- Availability and Cost of Neuro-monitoring

BOSTON UNIVERSITY

Tony Tannoury, M.D.

Case Example: What went wrong?

- Breakage of endplates
- Loss of sagittal balance
- Did not address L5-S1
- Stopped at L1 & screws breaking into the endplate
- Loss of distal fixation

Direct lateral L2-L5 and Post L1-S1

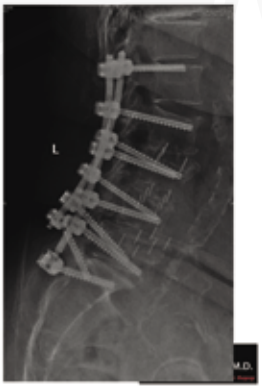

BOSTON UNIVERSITY

My preferred approach:
Antero-lateral interbody fusion

- T12-L1, L1-2, L2-3, L3-4, L4-5, possibly L5-S1
- Split fibers of oblique and transversus muscles
- Retract anterior 10-15% of psoas
- be Very careful of the misleading Quadratus Lumborum muscle

BOSTON UNIVERSITY

Tony Tannoury, M.D.

ATP access is NOT a direct lateral with slightly more anterior incision

Left side approach

Right side approach

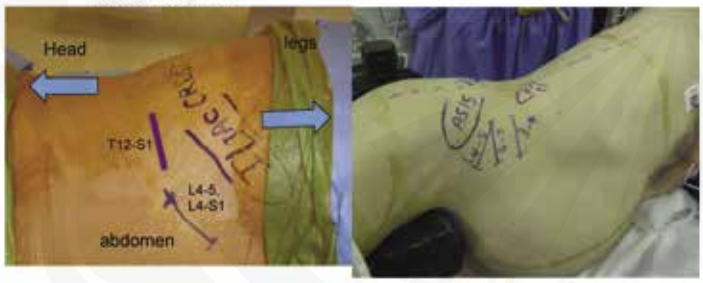

BOSTON UNIVERSITY

Tony Tannoury, M.D.

ATP access is NOT a direct lateral with slightly more anterior incision

- Anatomically different
- Mechanically different
- Neurologically different
- Pathology management

BOSTON UNIVERSITY

Tony Tannoury, M.D.

External oblique fascia and muscle split

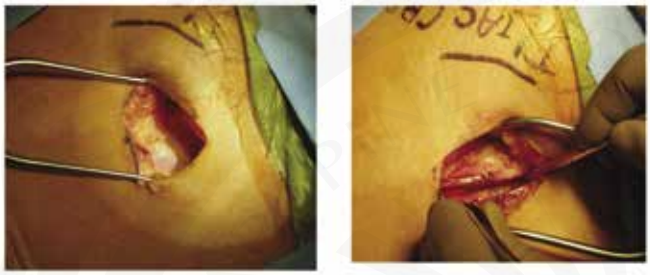

BOSTON UNIVERSITY

Tony Tannoury, M.D.

Internal oblique and transversus fascia split

BOSTON UNIVERSITY

Tony Tannoury, M.D.

Surgical Approach for L3-S1

Left lateral decubitus

Right antero-lateral approach

BOSTON UNIVERSITY

Tony Tannoury, M.D.

Surgical Technique: Abdominal wall

External oblique fascia | Internal oblique

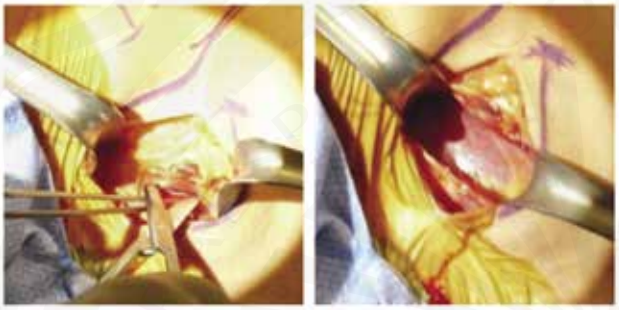

BOSTON UNIVERSITY

Tony Tannoury, M.D.

Surgical Technique

Psoas belly | Psoas retracted laterally

BOSTON UNIVERSITY

Tony Tannoury, M.D.

Anterior to Psoas Surgical Technique

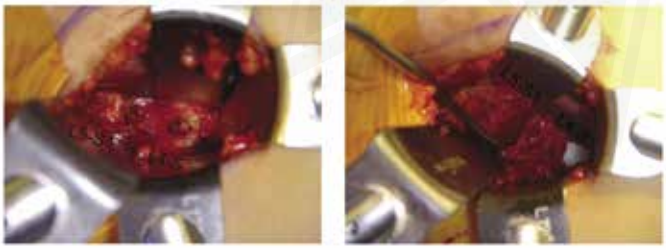

BOSTON UNIVERSITY

Tony Tannoury, M.D.

Standard Operative Approach: Surgical Technique

Spreaders

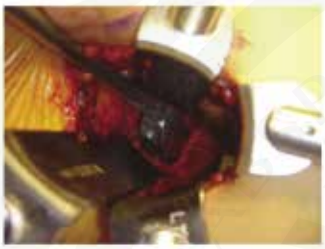

Cage insertion

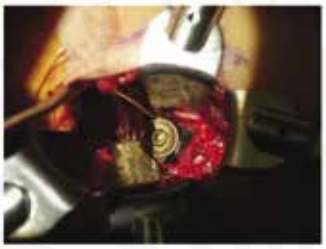

BOSTON UNIVERSITY

Tony Tannoury, M.D.

Normal Disc anatomy
Very strong anterior and posterior tether

BOSTON UNIVERSITY

Pictures: Courtesy of Wolfgang Rauschning

Tony Tannoury, M.D.

Disc anatomy & Biomechanical behavior

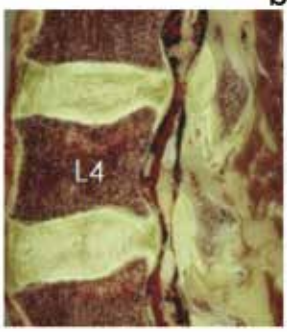

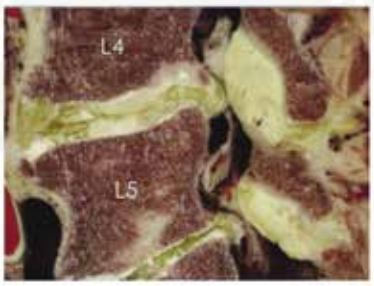

BOSTON UNIVERSITY

Pictures: Courtesy of Wolfgang Rauschning

Tony Tannoury, M.D.

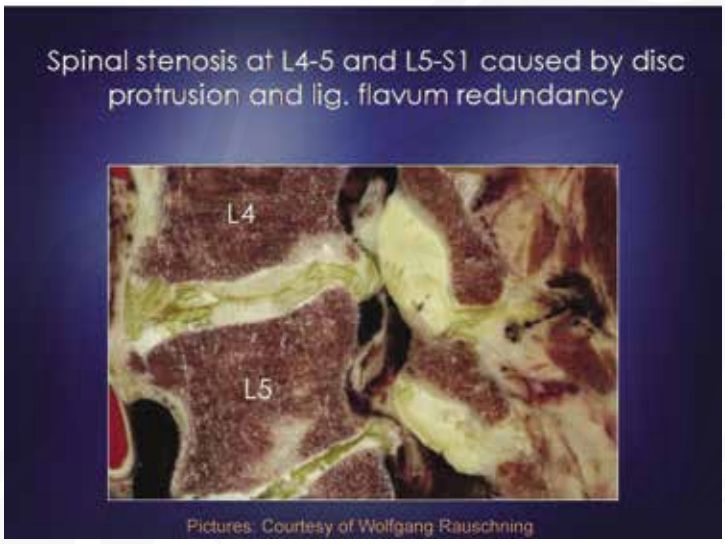
Spinal stenosis at L4-5 and L5-S1 caused by disc protrusion and lig. flavum redundancy
L4
L5
Pictures: Courtesy of Wolfgang Rauschning

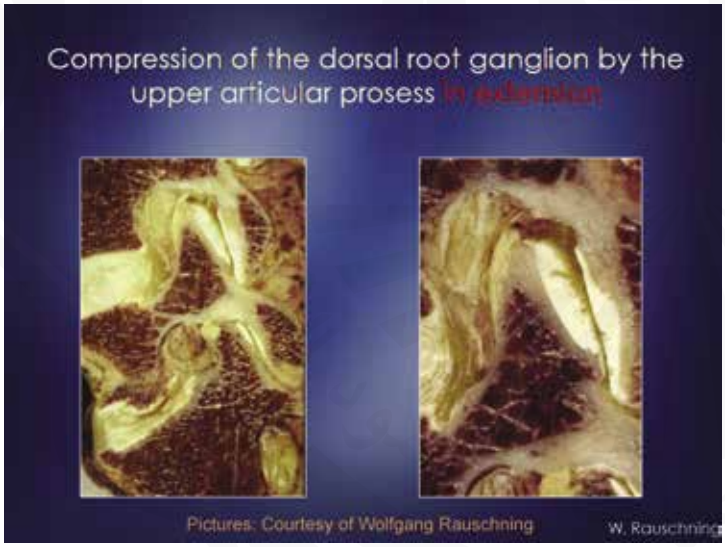
Compression of the dorsal root ganglion by the upper articular prosess in extension
Pictures: Courtesy of Wolfgang Rauschning
W. Rauschning

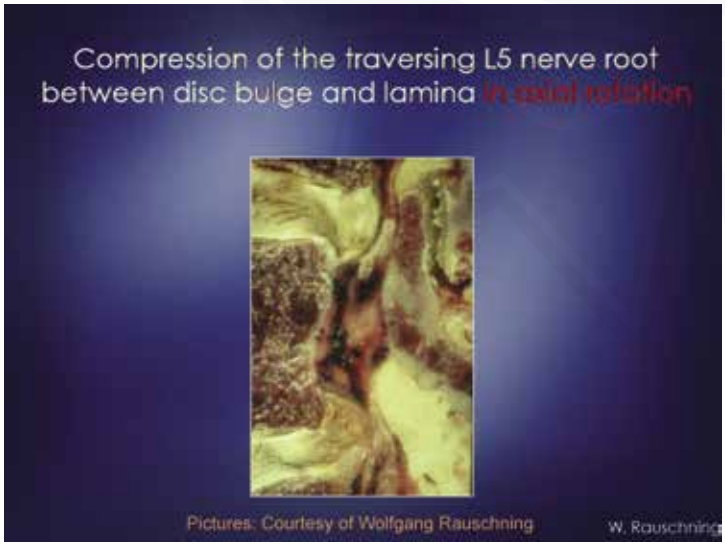
Compression of the traversing L5 nerve root between disc bulge and lamina in axial rotation
Pictures: Courtesy of Wolfgang Rauschning
W. Rauschning

Complete disc resorption causing kissing spines
W. Rauschning

Sclerotic L4-5 spondylophyte, kissing laminae
neoarthtosis and infolding ligamentum flavum
W. Rauschning

Spinal stenosis at L4-5 and L5-S1 caused by disc
protrusion and lig. flavum redundancy
L4
L5
W. Rauschning

Indirect decompression: requirements

- We have to re-establish disc height
- Create a vacuum, negative intradiscal pressure
- Reduce the anterior or posterior translation
- Stop the micro-motion
- Preservation of the end plates in order to preserve the decompression

BOSTON UNIVERSITY

Tony Tannoury, M.D.

Direct lateral approach

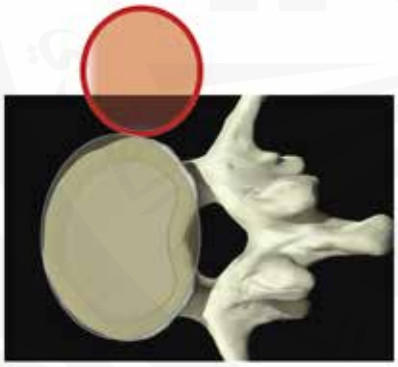

BOSTON UNIVERSITY

Tony Tannoury, M.D.

Trans-psoas muscle splitting: Space is limited

BOSTON UNIVERSITY

Tony Tannoury, M.D.

Middle 1/3 Channel discectomy

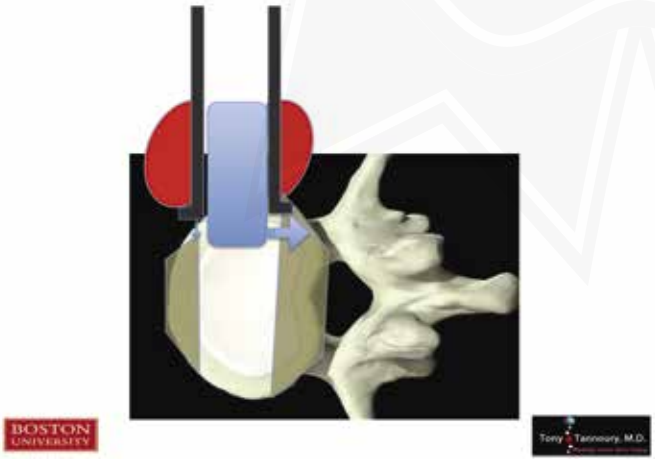

Potential Iatrogenic stenosis

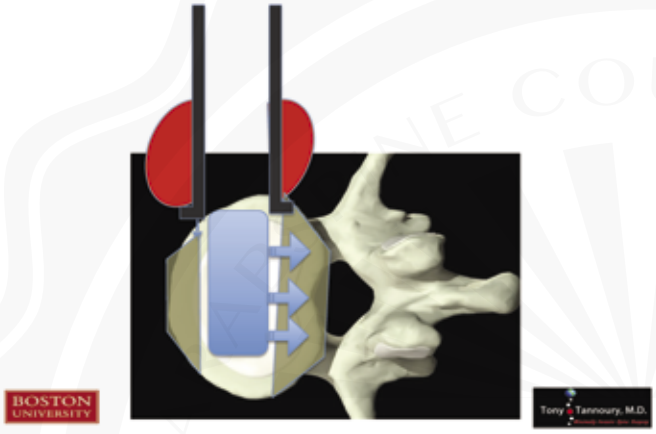

Anterior to the Psoas approach

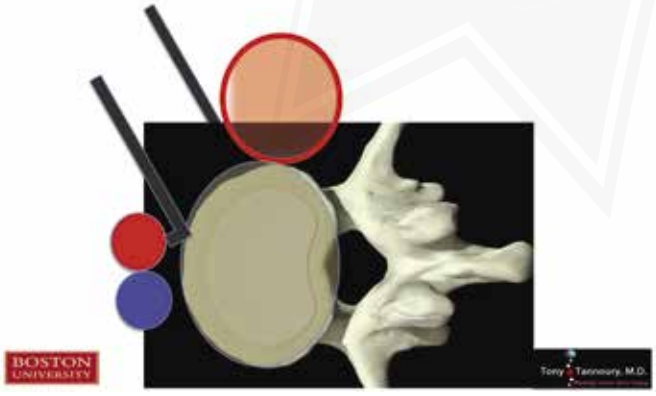

Oblique direct visualization access. No second bottle neck

More thorough discectomy:

significant thinning of the ALL, and PLL
allows complete release for kyphotic spine
always a gap between cage and remaining disc
ability to perform complete corpectomy
ability to directly perform Osteophytectomy

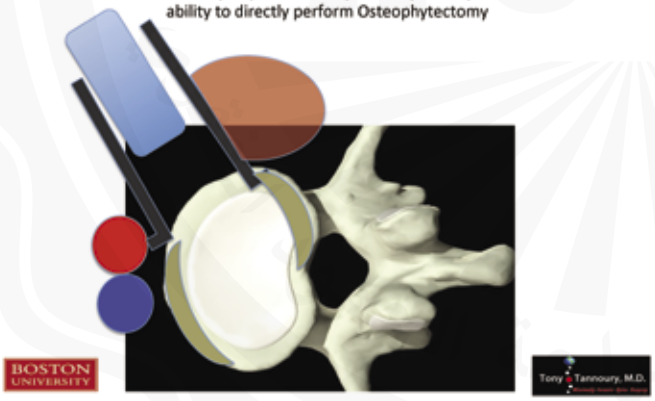

Direct Decompression When needed

BOSTON UNIVERSITY
Tony Tannoury, M.D.

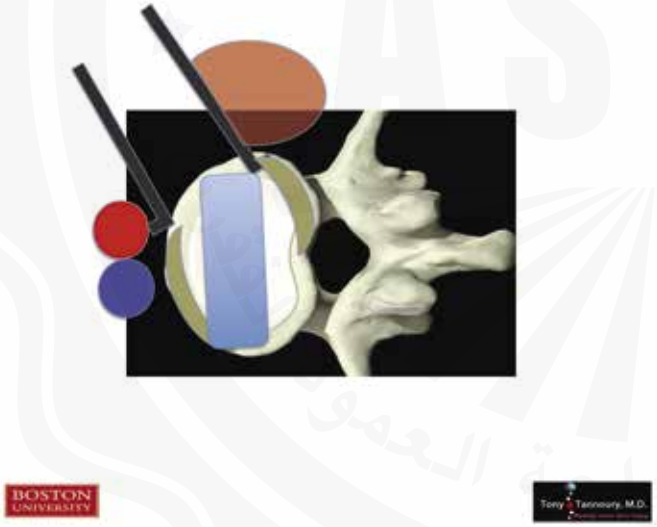
BOSTON UNIVERSITY
Tony Tannoury, M.D.

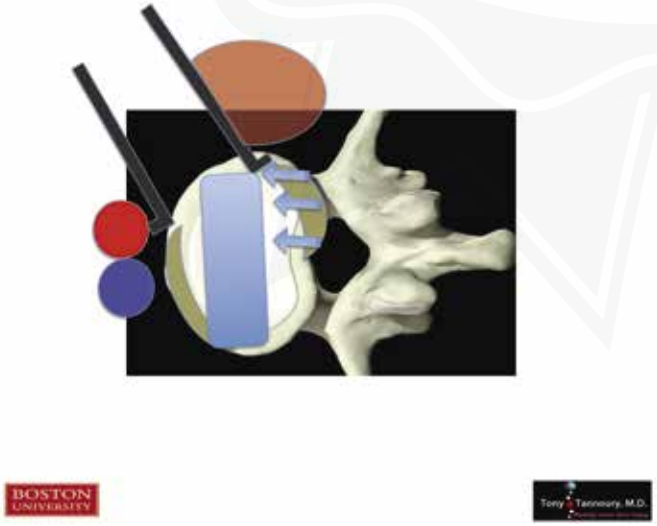
BOSTON UNIVERSITY
Tony Tannoury, M.D.

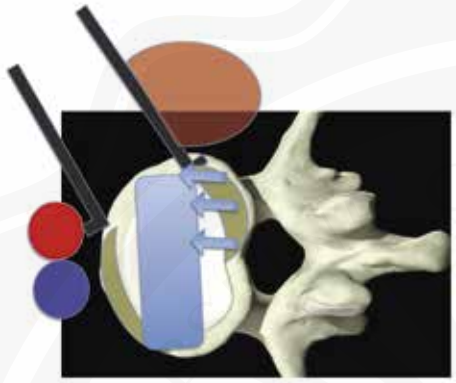

BOSTON UNIVERSITY

Tony Tannoury, M.D.

Indirect decompression

ATP	Trans Psoas
• Disc height reconstruction, reliable	• Disc height reconstruction: not reliable
• Negative suction intradiscal pressure: reliable	• Negative suction intra-discal pressure: Not reliable
• End plate preservation: reliable	• End plates: more commonly compromised – Risk of recurrent stenosis

BOSTON UNIVERSITY

Tony Tannoury, M.D.

Decompression: Direct vs Indirect

- Opening the foramina
- Recoil of the Posterior annulus
- Re-alignment of the spine; listhesis
- Stop the micro-motion and dynamic stenosis

BOSTON UNIVERSITY

Tony Tannoury, M.D.

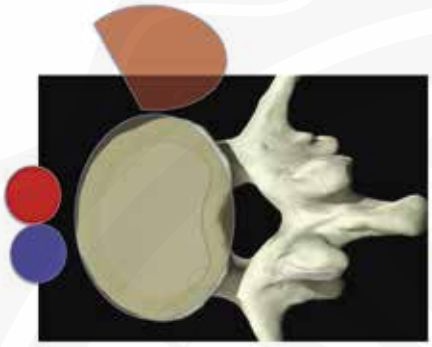

BOSTON UNIVERSITY

Tony Tannoury, M.D.

Mechanics: Direct lateral

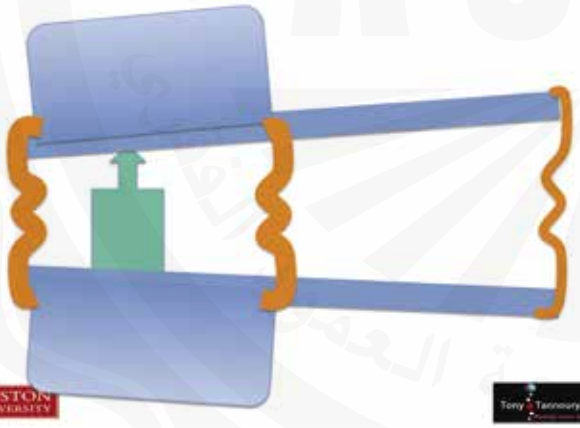

BOSTON UNIVERSITY

Tony Tannoury, M.D.

Initial distraction

- Tightening but not release of the anterior tether
- Some early lordosis

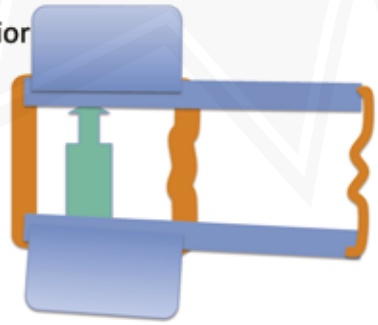

BOSTON UNIVERSITY

Tony Tannoury, M.D.

Direct Lateral: Further Distraction

- Lengthening of the PLL and posterior facet
- No further lengthening of the ALL/Ant annulus
- Loss of early lordosis

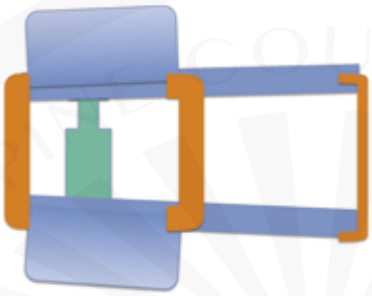

BOSTON UNIVERSITY

Tony Tannoury, M.D.

Direct Lateral: Further distraction

- The soft tissue tether remains strong
- Creep of the bony endplates
- Late subsidence
- Recurrent stenosis
- Loss of sagittal balance

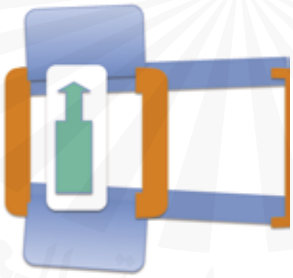

BOSTON UNIVERSITY

Tony Tannoury, M.D.

Biomechanics Anterior to the Psoas approach

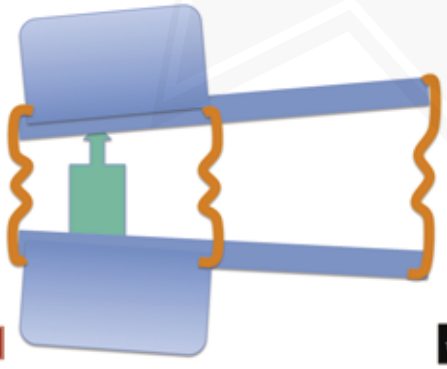

BOSTON UNIVERSITY

Tony Tannoury, M.D.

ATP: Early distraction

- Stretching of the ALL.
- Early lordosis

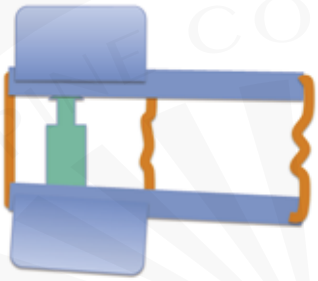

BOSTON UNIVERSITY

Tony Tannoury, M.D.

ATP: further distraction

- Ripping of the ALL, anterior annulus, pll.
- Hinges on the posterior facets
- Satisfactory Lordosis
- Effective Indirect Decompression

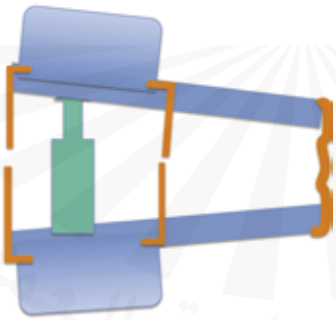

BOSTON UNIVERSITY

Tony Tannoury, M.D.

Triangular discs = Release of the Anterior tether

BOSTON UNIVERSITY

Tony Tannoury, M.D.

Anterior tether:
ALL+ Anterior annulus

Younger disc

Older Arthritic disc

Anterior tether, despite thinning, stronger than the bone

Complete the Release

Another Anterior Release

BOSTON UNIVERSITY

Tony Tannoury, M.D.

BM 3799814
77F with morbid obesity
L3-4, L4-5 advanced degenerative disc disease with spondylolisthesis
LBP with Decreased sensation over the side of the thigh and difficulty walking Motor: 4+/5

BOSTON UNIVERSITY

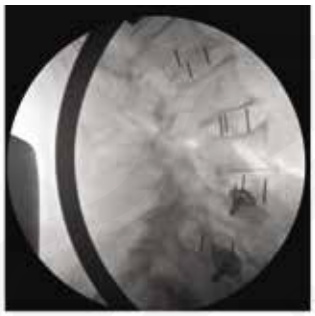

NS, 3819047
81F
Diffuse degenerative disc disease, lumbar spine, with L3-L4 spondylolisthesis

Walks with a forward hunched gait.
Neurology:
Sensation: She has some decreased sensation in both legs, left more than right.
Motor: 5/5 except for the quadriceps on the left which is 4/5. EHL is also 4/5.

ATP enable future technologies:

- Anterior plating/rod fixation
- L5-S1 implants
- L1-2 implants
- Corpectomy cages/implants

BOSTON UNIVERSITY

Tony Tannoury, M.D.

67/M with lymphoma metastatic to spine, s/p chemotherapy, in remission, back pain with bilateral proximal lower extremity weakness

BOSTON UNIVERSITY

Tony Tannoury, M.D.

Fx at the base of Auto-Ankylosis

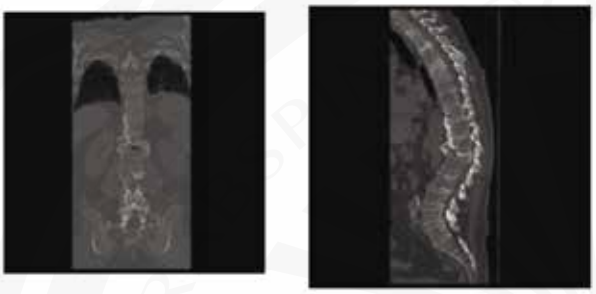

BOSTON UNIVERSITY

Tony Tannoury, M.D.

MRI

STIR

T1 + C

BOSTON UNIVERSITY

Tony Tannoury, M.D.

CT -Scan

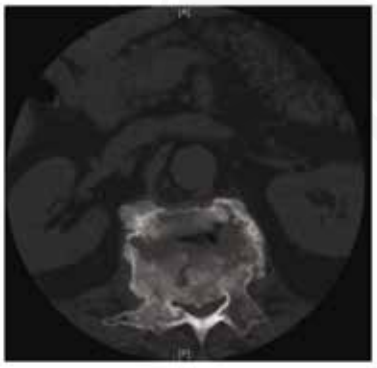

BOSTON UNIVERSITY

Tony Tannoury, M.D.

Flexion-Extension

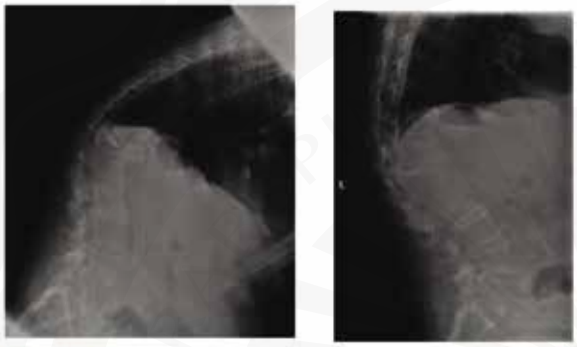

BOSTON UNIVERSITY

Tony Tannoury, M.D.

Thoracotomy for L1 Corpectomy and T12-L1 interbody fusion;
L2-L5 ALIF via anterolateral approach

Stage 1: Anterior

BOSTON UNIVERSITY

Tony Tannoury, M.D.

Stage I

Stage 1: Anterior

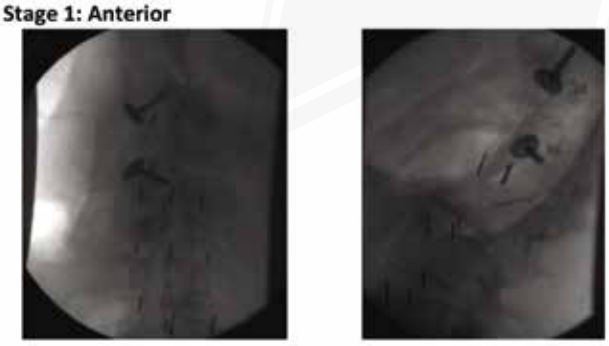

BOSTON UNIVERSITY

Tony Tannoury, M.D.

Stage 1: Post-op

BOSTON UNIVERSITY

Tony Tannoury, M.D.

Stage 2: PSIF with bone cement

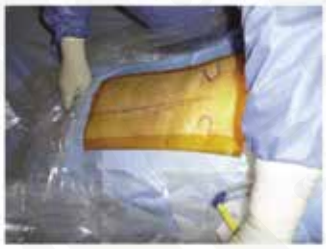

BOSTON UNIVERSITY

Tony Tannoury, M.D.

BOSTON UNIVERSITY

Tony Tannoury, M.D.

Cementing

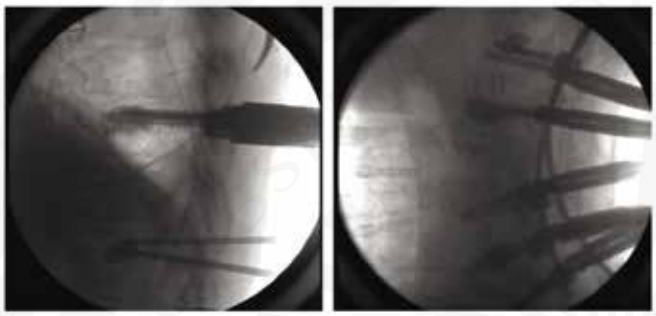

BOSTON UNIVERSITY

Tony Tannoury, M.D.

BOSTON UNIVERSITY

Tony Tannoury, M.D.

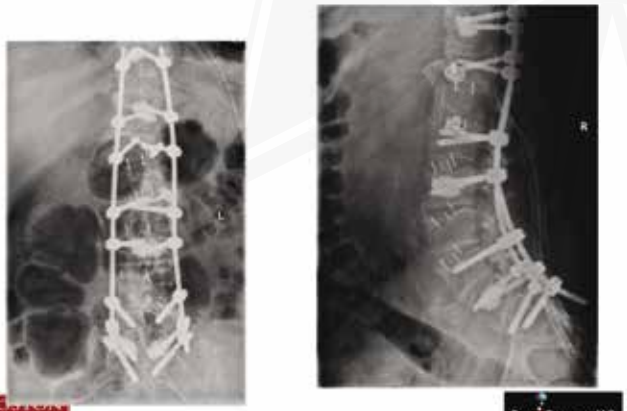

BOSTON UNIVERSITY

Tony Tannoury, M.D.

Other advantages for ATP

- Allows anterior plating or Rods placement
- Allows access of L4-5 and L5-S1
- Allows access of the L1-2 and T12-L1 without going through the diaphragm

BOSTON UNIVERSITY

Tony Tannoury, M.D.

78 yo lady s/p 2 spinal surgeries, laminectomies then fusion

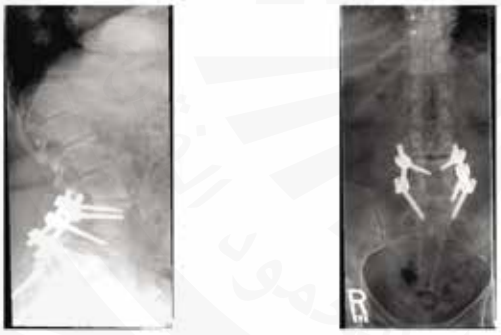

BOSTON UNIVERSITY

Tony Tannoury, M.D.

CT and Myelogram

BOSTON UNIVERSITY

Tony Tannoury, M.D.

options

- PT
- DECOMPRESSION
- FUSION
  - POSTERIOR
  - ANTERIOR
  - A/P
  - HARDWARE!!!

BOSTON UNIVERSITY

Tony Tannoury, M.D.

Anterior Fusion and plating

BOSTON UNIVERSITY

Tony Tannoury, M.D.

Another patient with Two level ASD

Case presentation
ASD with severe osteoporosis

- **MS- 73F with severe back and left leg pain**
  - **Aggravated by standing, lifting, bending**
  - **Improved with lying**
  - **Back pain 70%, Leg pain 30%**
- 3 past spine surgeries (OSH)
  - L4-5 discectomy and decompression x2. (2006, 2008)
    - Brief relief of symptoms following 1st decompression with minimal relief from repeat decompression
  - L4-5 ALIF/PSIF (2009)
    - 6 months of improvement in back and leg pain

BOSTON UNIVERSITY

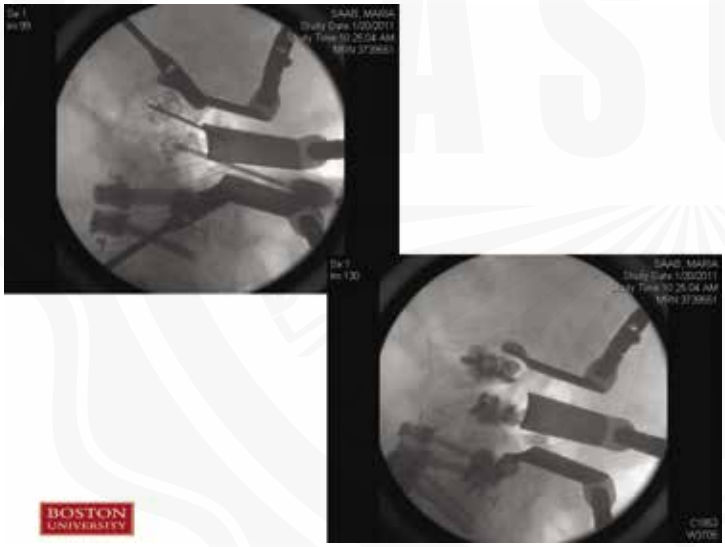

BOSTON UNIVERSITY

BOSTON UNIVERSITY

45 yo s/p fall
severe right LE weakness



BOSTON UNIVERSITY

Final X-rays

BOSTON UNIVERSITY

Tony Tannoury, M.D.

conclusion

- ATP IS VERY INTIUITIVE PROCEDURE
- GIVE SIGNIFICANT ACCESS TO THE SPINE
- MECHANICALLY AND NEUROLOGICALLY SOUND
- NO NEED FOR FLUOROSCOPY OR NEURO-MONITORING
- APPIICABLE FOR VERY LARGE SCOPE OF PATHOLOGY

BOSTON UNIVERSITY

Tony Tannoury, M.D.

HYBRID FIXATION (HOOKS, SCREWS, WIRES)

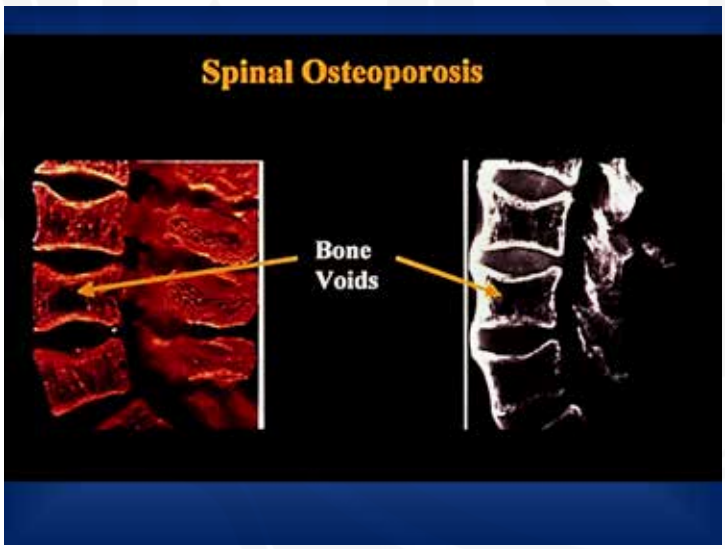

Strategies for Surgical Fixation

- Pre-operative optimization
- Surgical
  - Spinal fixation planning
  - Spinal fixation options
  - Spinal surgical pearls
- Post-operative management

Fixation in Osteoporotic Spine: General Considerations

- BMD single strongest predictor of pull-out strength. Linearly related to
  - insertion torque
  - fatigue failure
  - pullout strength
- Tactile sense of purchase predicts construct strength
  - insertion torque < 4 in-lb likely to fail early
- BMD normalization improves stability more than bicortical purchase

Implant Failure- Pedicle Screw Fixation

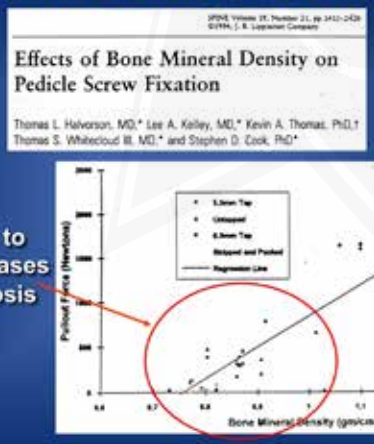

Resistance to pullout decreases in osteoporosis

DEXA Score (WHO)

- # of SDs from Ideal Peak Bone Mass
- T<1 SD Normal
- T= 1 – 2.5 SD Osteopenia
- T > 2.5 SD Osteoporosis
- Hx fragility fracture Severe osteoporosis

Strategies for Surgical Fixation

- Pre-operative optimization
- Surgical
  - Spinal fixation planning
  - Spinal fixation options
  - Spinal surgical pearls
- Post-operative management

Spinal Fixation Planning

Failure at bone – metal interface

- Increase construct strength by increasing fixation points
- Include more levels
- Multiple points of fixation to share the loads

Spinal Fixation Planning

- Pedicle screw most stable
- Hooks with claws the next most stable
- Hooks alone
- Cables proved least strength

Hilibrand et al. J Neurosurgery Spine 2002

Spinal Fixation Planning

Hook hierarchy

- Transverse process hook
- Laminar hook
- Pedicle hook

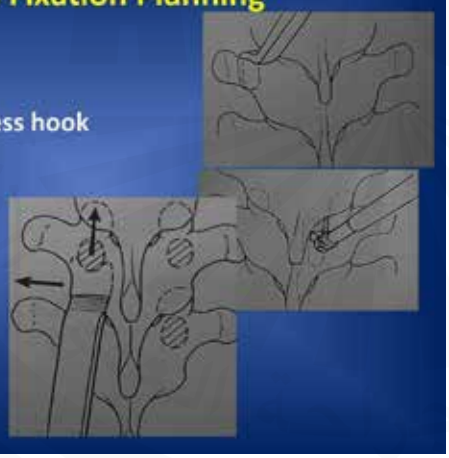

Spinal Fixation Planning

Claw hierarchy

- Single lamina claw less stable
- Two lamina claw more stable
  - Wide claw
  - Lamina/transverse process
  - Lamina/lamina
  - Pedicle hook/lamina

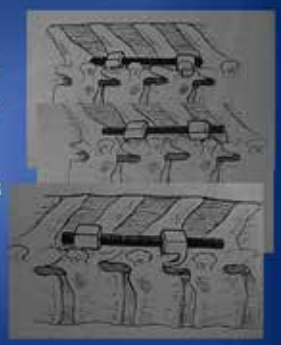

Spinal Fixation Planning

- Pedicle screw fixation most stable
- Better resistance against spinal forces
  - Axial compression
  - Flexion
- Most stable screw construct
  - Largest diameter possible to fit in pedicles
  - Longest screw
  - Triangulation

Spinal Fixation Planning

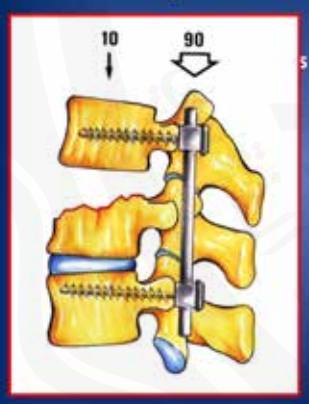

Strategies for Surgical Fixation

- Pre-operative optimization
- Surgical
  - Spinal fixation planning
  - Spinal fixation options
  - Spinal surgical pearls
- Post-operative management

Spinal Fixation Options

- PMMA cement commonly used
- Calcium phosphate cement
- Calcium sulfate cements
- All demonstrate comparable biomechanical strengths for screw augmentation
- Osteoporotic beagle dogs
  - Increased pullout (56%)
  - Increased resistance to toggle forces (76%)

Polikeridis et al. Spine Journal 2002
Tarnowski et al. J Ortho Sci 2003

Spinal Fixation Options

- Increase fixation strength to bone
- Failure at bone/metal interface
- Cementing pedicle screws
  - Injection along entire length of screw hole is strongest
  - Injection at just the distal tip of the screw hole provides less stability

Renner et al. Spine 2004

Spinal Fixation Options

- Pedicle screws placed
- Augmented with hook at the same level
- Increased biomechanical rigidity
- Superior to cementing screws
- Especially good for compromised bone

Hilibrand et al. Spine 1999
Tan et al. Spine 2004

Spinal Fixation Options

- Pedicle screws placed
- Can also be augmented with sublaminar wires at the same level
- Superior to cementing screws alone

Tan et al. Spine 2004

Sublaminar Wires

- Maximize radius of curvature
- Pass as close to midline as possible
- Avoid tip more than 45 degrees

Spinal Fixation Options

- Pedicle screw fixation with washers
- Biomechanical studies demonstrate
  - Increased insertional torque
  - Increase pullout strength
- Option with some instrumentation systems

Shepard et al. Clin Orthop 2002

Screw – Bone Interface

- Anterior cortical penetration increases fixation
- No difference in pull-out between 4.5 and 6.5 screws with bicortical fixation

Zindrick et al

Triangulation & Transverse Connectors

- Transverse connectors
  - ↑ axial rotation and lateral bending stability
  - >2 level constructs → 2 crosslinks
  - Optimal locations:
    - one in middle
    - second at proximal 1/8th
- Bilateral triangulated screws
  - Transverse connector
  - Holds all bone between screws
  - Rather than bone within threads of each screw.

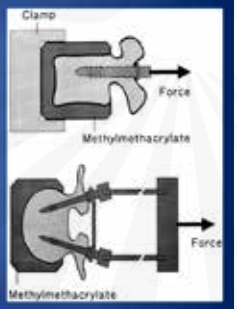

Spinal Fixation Options

- Expandable pedicle screw
- Increased pullout strength
- Increased stability
- Cementation of expandable screw
  - 250% greater pullout strength
  - Compared to cemented non-expandable screw

Cook et al. Spine Journal 2004

Pedicle Screw Augmentation

- Placement of "shims" of allograft into pedicle screw holes
- Improves insertional torque
- Increased biomechanical stability

Polly et al. Spine 1998

Screw Design Considerations

- Increasing the major diameter
- Decreasing the minor diameter
- Fully threaded > partially threaded

Perforated Screws

Sacral Screws

- Direct screws towards sacral promontory
- 99% increase in insertional torque compared to bicortical fixation

Lehman et al.
Abitbol, Rodzuk et al.

My Preference

- Two divergent triangulated screws > one screw
  - ↑ stiffness by > 120%

Ref: Leong, Spine, 1998

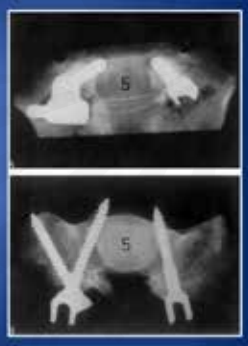

Biomechanics - Sacrum

- Iliac fixation significantly improves construct stiffness
  - "Protects" L5/S1 screws
  - Distributes load

McCord, Spine,1993

Strategies for Surgical Fixation

- Pre-operative optimization
- Surgical
  - Spinal fixation planning
  - Spinal fixation options
  - Spinal surgical pearls
- Post-operative management

Surgical Pearls

Don't back out pedicle screw once placed

- Decreased torque and stability with even a quarter backout turn of screw
- Better to leave screw more proud initially than lower screw to lower level

Shepard et al. Clin Orthop 2002

Compress Contructs

- Pedicle screws or hooks
- Compressive forces increase
  - Construct stiffness (45%)
  - Decrease rod strain (22%)

Belmont et al. Spine 2002

Don't

- Compression and Distraction maneuvers
  - Not against implants themselves
    - Even optimally placed and sized screws do not completely fill pedicle
  - Use lamina spreaders or other devices on:
    - Cortical posterior elements
    - Interbody space

Don't

- In situ bending
  - Done with extreme caution if at all
- "Towers" and "persuaders"
  - Risk construct failure

Strategies for Surgical Fixation

- Pre-operative optimization
- Surgical
  - Spinal fixation planning
  - Spinal fixation options
  - Spinal surgical pearls
- Post-operative management

Post-op Management

- Post-operative bracing
- Activity restrictions
- Allowing longer healing times

Summary

- Osteoporotic patients present management difficulties for spine surgery
- Pre-operative optimization
- Operative planning and techniques
- Post-operative immobilization
- All may help with decreased hardware failure

NAVIGATION IN DEFORMITY SURGERY

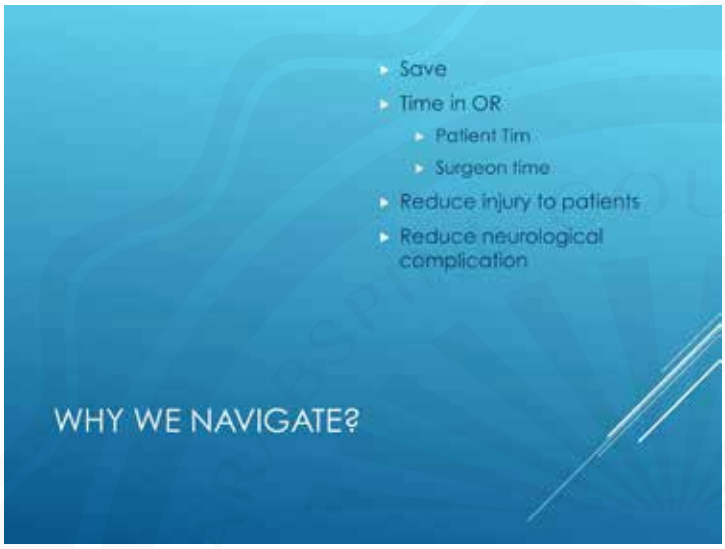
Save
Time in OR
Patient Tim
Surgeon time
Reduce injury to patients
Reduce neurological complication
WHY WE NAVIGATE?

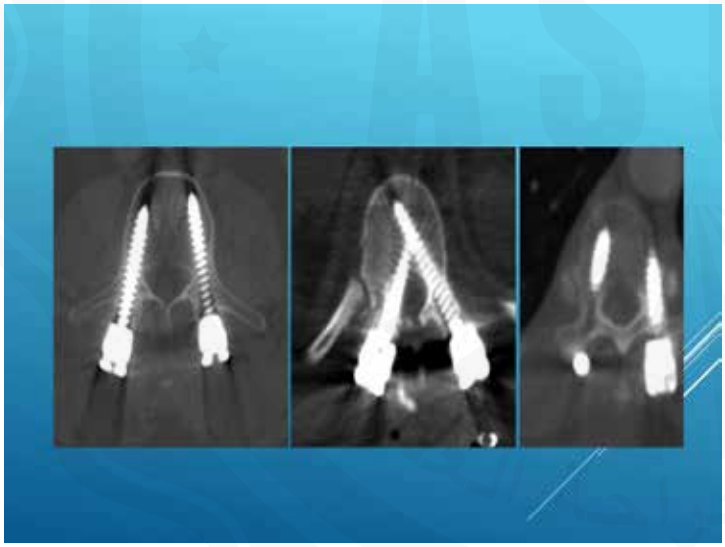

Simple scoliosis
May be I can do free hand technique
Anatomy
DEFORMITY

SEVER SCOLIOSIS
DISTURBED ANATOMY
DEFORMITY

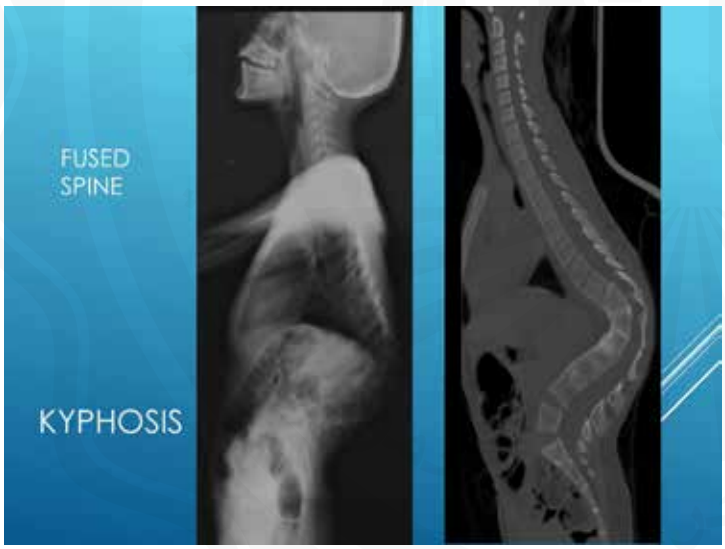
FUSED
SPINE
KYPHOSis

Lower Thoracic Spine (T9-T12)
T9
T10
T11
T12
FREE HAND TECHNIQUE

Simultaneous
Multi-planar
Visualization of spinal anatomy
Virtual tracking of any instrument
In displayed anatomy in real time
Improved
Accuracy
Safety
Radiation exposure
IGS PROVIDES

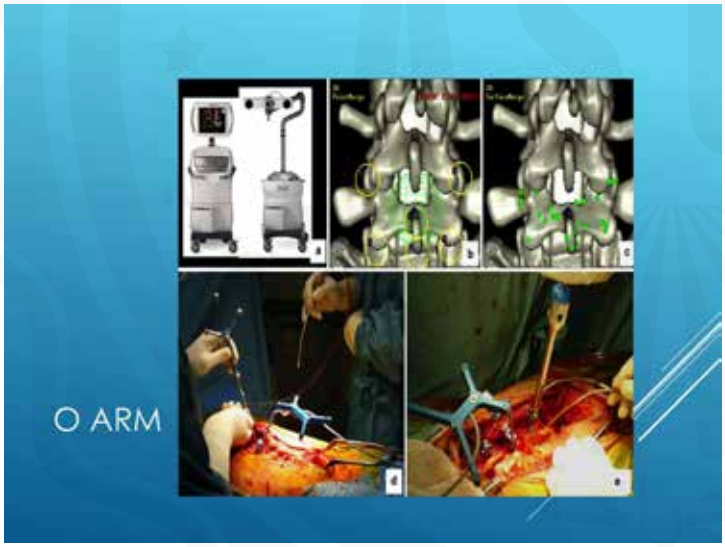
O ARM

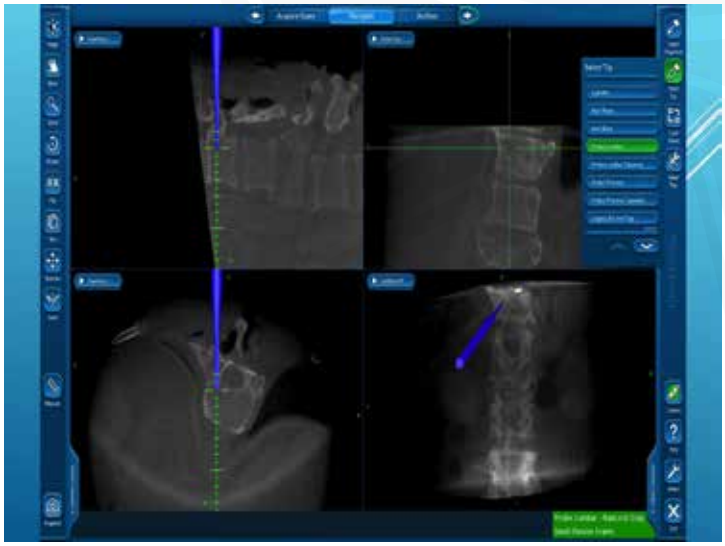

Several modalities
Direct visualization
Serial radiography
C-arm fluoroscopy
CT scan based
O Arm navigation
Intra operative CT scan
IMAGE-GUIDED NAVIGATION

C-ARM FLUOROSCOPY

INTRA OPERATIVE CT SCAN
BRAINLAP

O ARM

Reference
Image acquiring
CR scan
O arm
Navigator
Camera
Instruments identified
TECHNIQUE

Navigated
Pedicel finder
Tap
Screw drive
INSTRUMENTS

SOME TIME YOU AN NAVIGATE
EXTRA INSTRUMENT

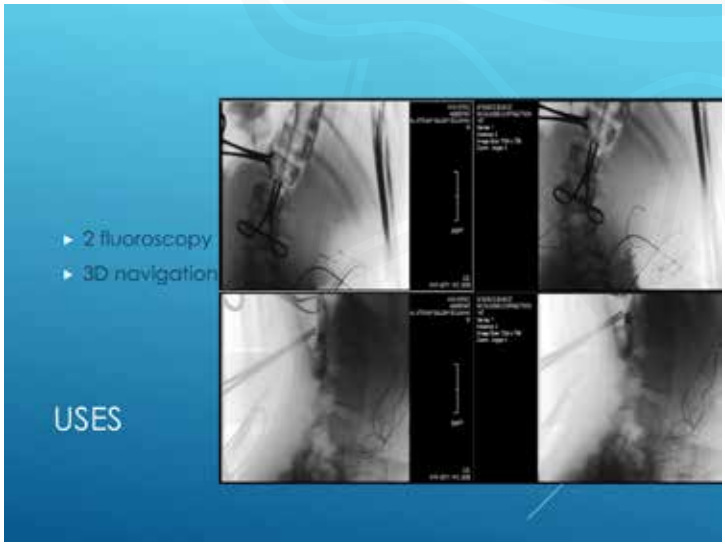
2 fluoroscopy
3D navigation
USES

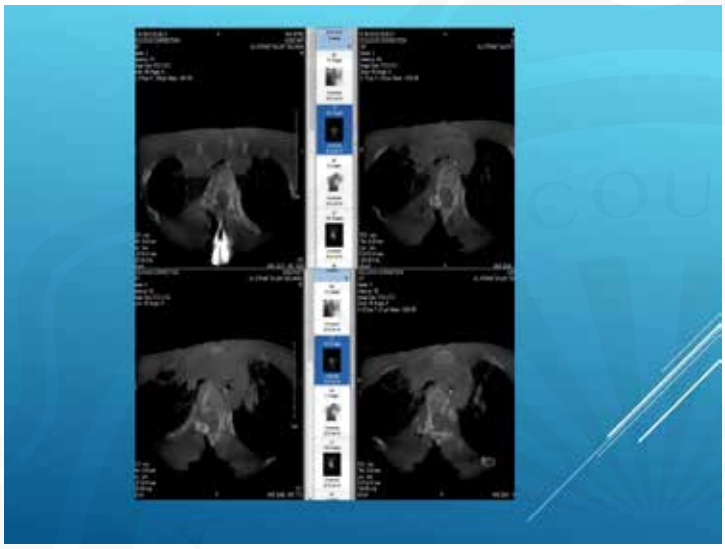

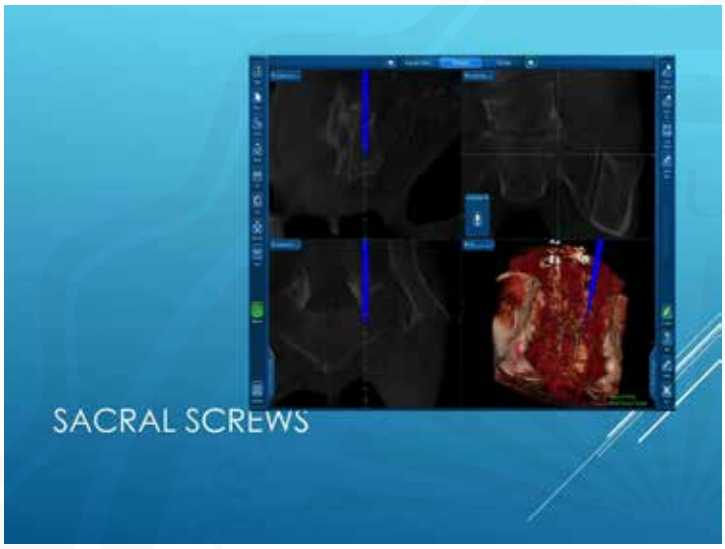
SACRAL SCREWS

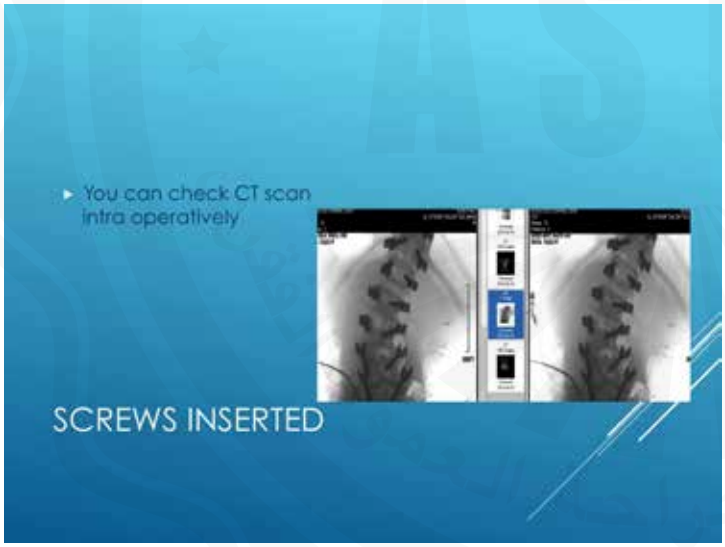
You can check CT scan intra operatively
SCREWS INSERTED

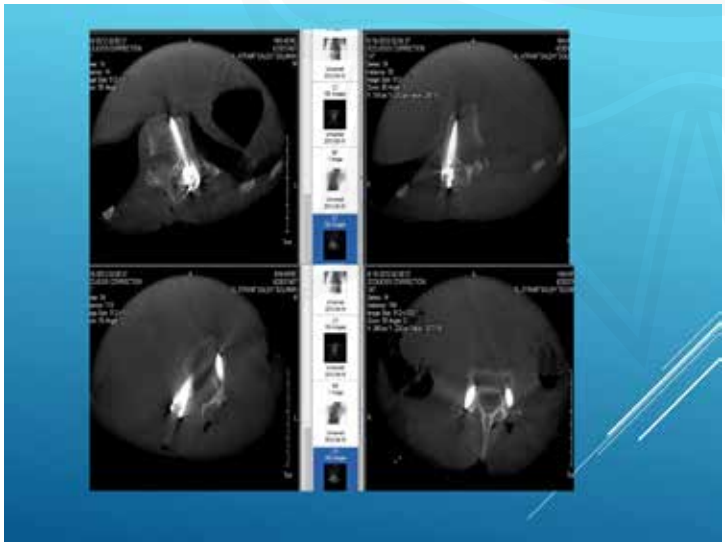

DISADVANTAGES

- Bulky tools
- Pedicle finder tip
- Instruments long
- Sensitive
  - Offset false images
- Radiations
- OR flow

TRICKS

- Well positioned
- Jackson table
- Arms tacked at the sides
- Give yourself extra space
- Avoid excessive manipulation
- Hammering
- Delay osteotomy after screws insertion
- Start away from the reference
- Alternate side sat each level

MANAGING COMPLEX CASES

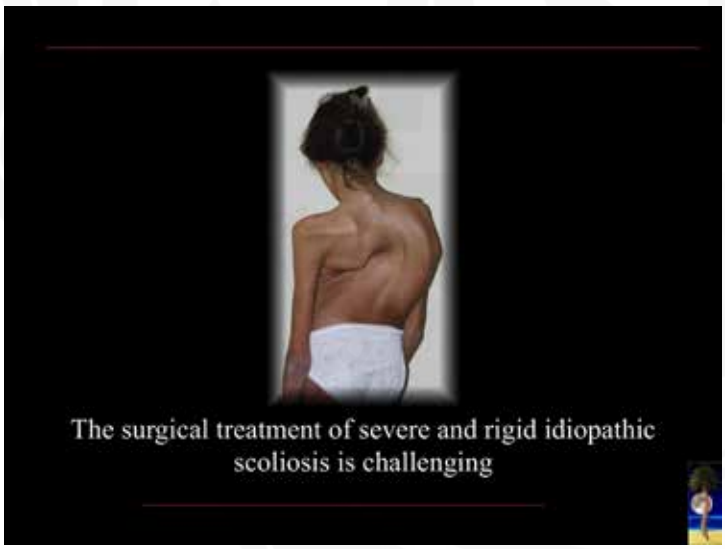

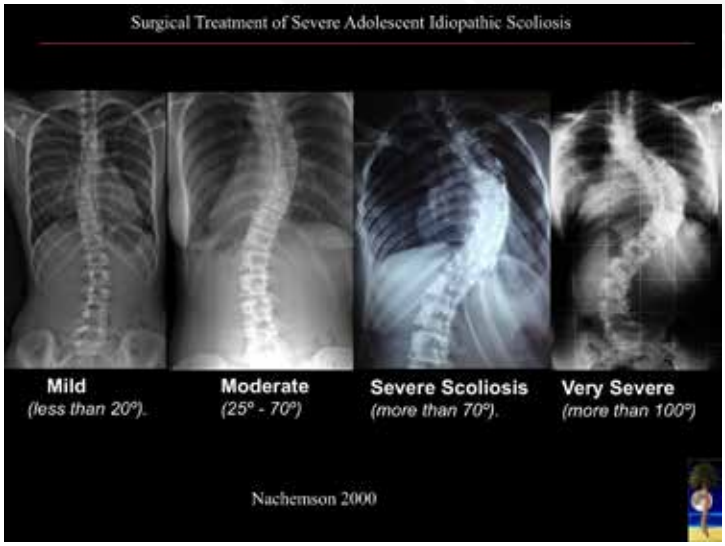

Severe Adolescent Idiopathic Scoliosis
98°
The severity of the scoliosis depends on the degree of the curvature and whether it threatens vital organs, specifically the lungs and heart.

Severe Adolescent Idiopathic Scoliosis
This problem is very uncommon in western countries

Surgical Treatment of Severe Adolescent Idiopathic Scoliosis
Technically demanding and should be performed by an experienced surgical team.

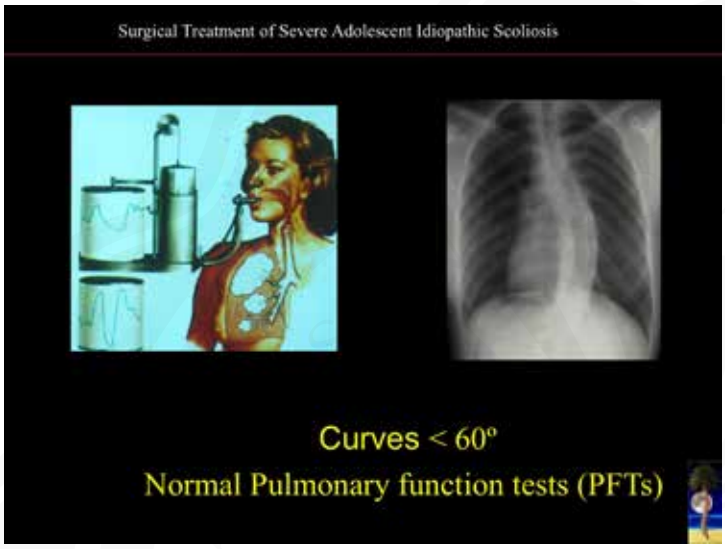
Surgical Treatment of Severe Adolescent Idiopathic Scoliosis
Curves < 60°
Normal Pulmonary function tests (PFTs)

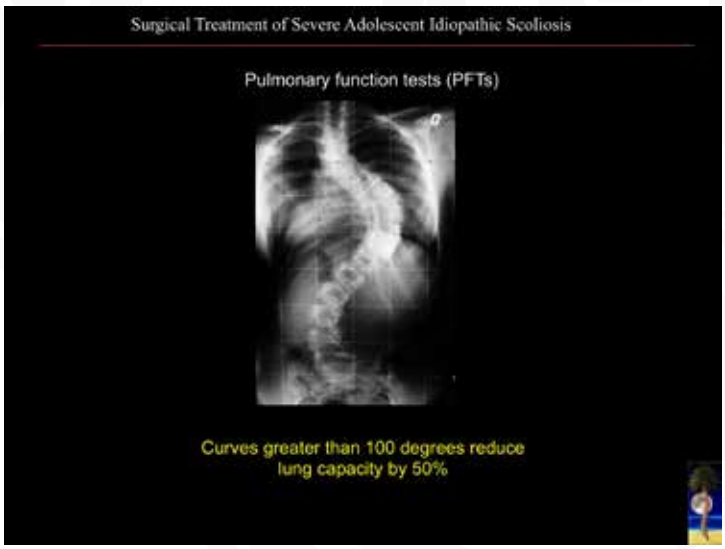
Surgical Treatment of Severe Adolescent Idiopathic Scoliosis
Pulmonary function tests (PFTs)
Curves greater than 100 degrees reduce
lung capacity by 50%

Surgical Treatment of Severe Adolescent Idiopathic Scoliosis
They can also cause breathing difficulties
in everyday activities

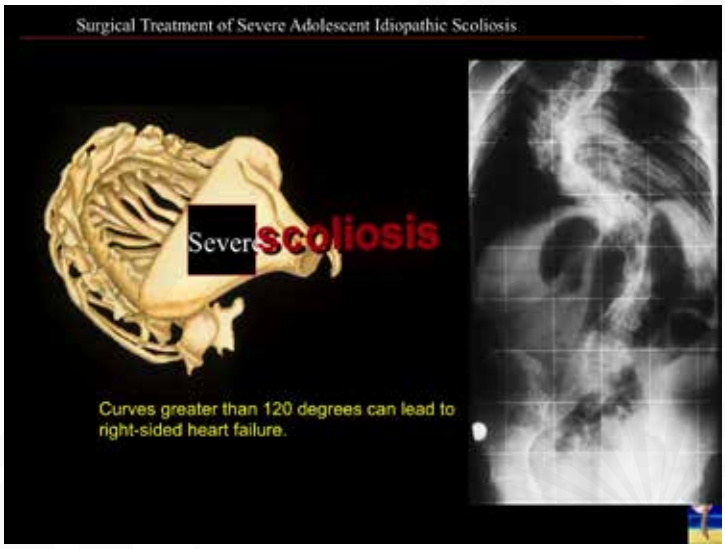
Surgical Treatment of Severe Adolescent Idiopathic Scoliosis
Severe scoliosis
Curves greater than 120 degrees can lead to right-sided heart failure.

Surgical Treatment of Severe Adolescent Idiopathic Scoliosis
✓ Anterior release and a posterior correction and instrumentation
✓ Anterior release and Period of halo traction
✓ Anterior and posterior vertebral column resection (APVCR)
✓ Posterior vertebral column resection (PVCR)
✓ Posterior segmental pedicle screw instrumentation
✓ posterior pedicle screw instrumentation Luque instrumentations

Surgical Treatment of Severe Adolescent Idiopathic Scoliosis
Correction rate of 50–60%
55
80
70
Pre-op.
Post. Op.

Surgical Treatment of Severe Adolescent Idiopathic Scoliosis
Patient require ventilator support after anterior surgery will compromise pulmonary function and means longer hospital stay time

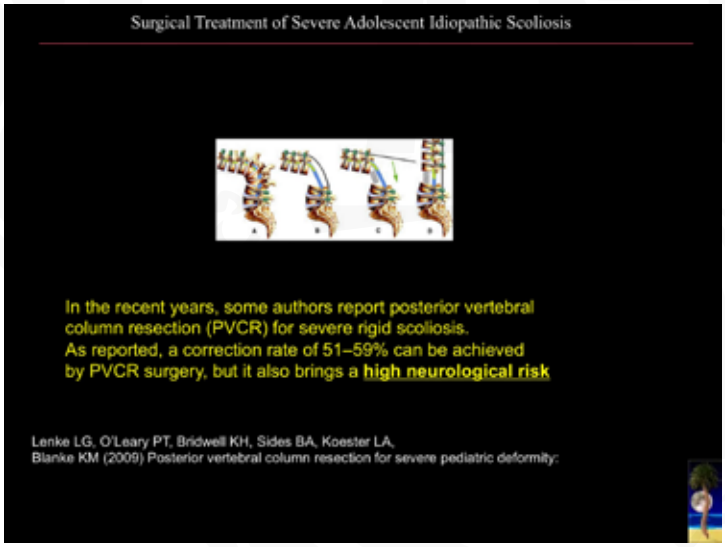
Surgical Treatment of Severe Adolescent Idiopathic Scoliosis
In the recent years, some authors report posterior vertebral column resection (PVCR) for severe rigid scoliosis.
As reported, a correction rate of 51–59% can be achieved by PVCR surgery, but it also brings a high neurological risk
Lenke LG, O'Leary PT, Bridwell KH, Sides BA, Koester LA, Blanke KM (2009) Posterior vertebral column resection for severe pediatric deformity:

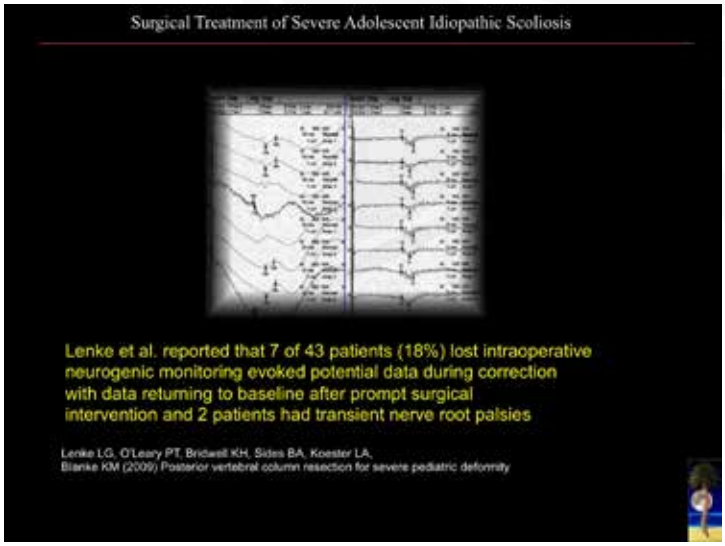
Surgical Treatment of Severe Adolescent Idiopathic Scoliosis
Lenke et al. reported that 7 of 43 patients (18%) lost intraoperative neurogenic monitoring evoked potential data during correction with data returning to baseline after prompt surgical intervention and 2 patients had transient nerve root palsies
Lenke LG, O'Leary PT, Bridwell KH, Sides BA, Koester LA, Blanke KM (2009) Posterior vertebral column resection for severe pediatric deformity

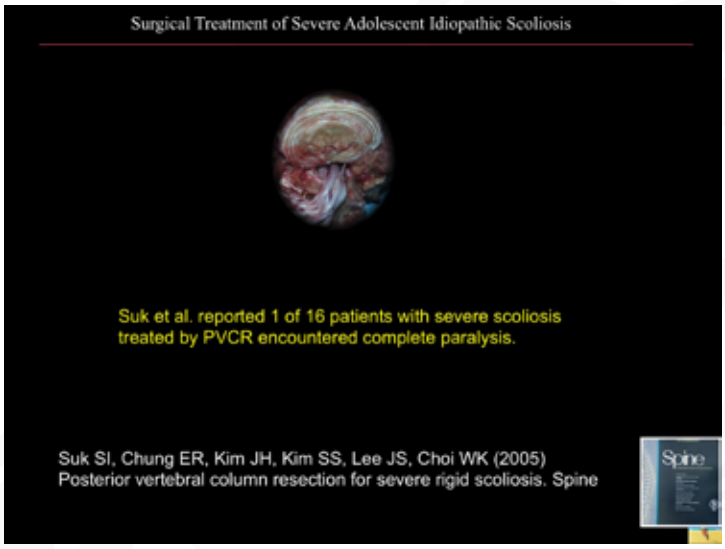
Surgical Treatment of Severe Adolescent Idiopathic Scoliosis
Suk et al. reported 1 of 16 patients with severe scoliosis treated by PVCR encountered complete paralysis.
Suk SI, Chung ER, Kim JH, Kim SS, Lee JS, Choi WK (2005)
Posterior vertebral column resection for severe rigid scoliosis. Spine
Spine

Surgical Treatment of Severe Adolescent Idiopathic Scoliosis
Posterior-only approach with the use of an all-pedicle screw construct and osteotmies has the advantage of providing the same correction as an anterior/posterior spinal fusion.
Dobbs MB, Lenke LG, Kim YJ, Luhmann SJ, Bridwell KH (2006). Spine
Chunguang Zhou • Limin Liu • Yueming Song Eur Spine J (2011)

Surgical Treatment of Severe Adolescent Idiopathic Scoliosis
To optimize curve correction and to eliminate both patient discomfort and a prolonged hospital stay resulting from halo traction; pulmonary and neurologic complications
✓ Pedicle screw and hybrid instrumentations offer significantly safer correction

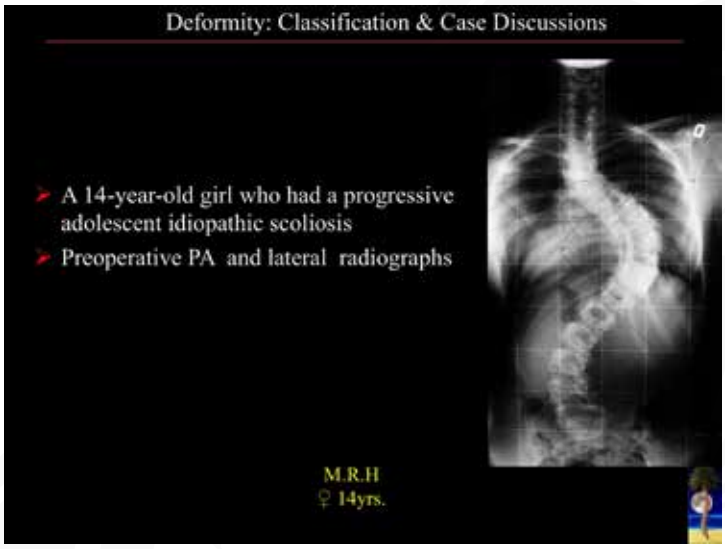
Deformity: Classification & Case Discussions
A 14-year-old girl who had a progressive adolescent idiopathic scoliosis
Preoperative PA and lateral radiographs
M.R.H
♀ 14yrs.

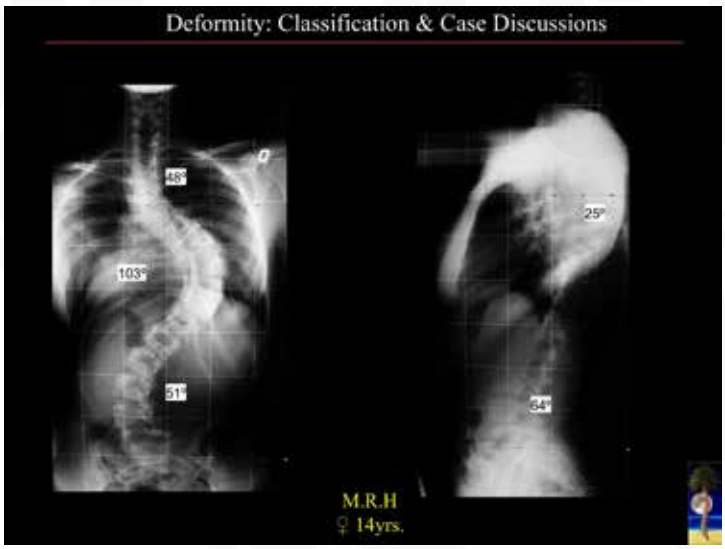
Deformity: Classification & Case Discussions
48°
103°
51°
25°
64°
M.R.H
♀ 14yrs.

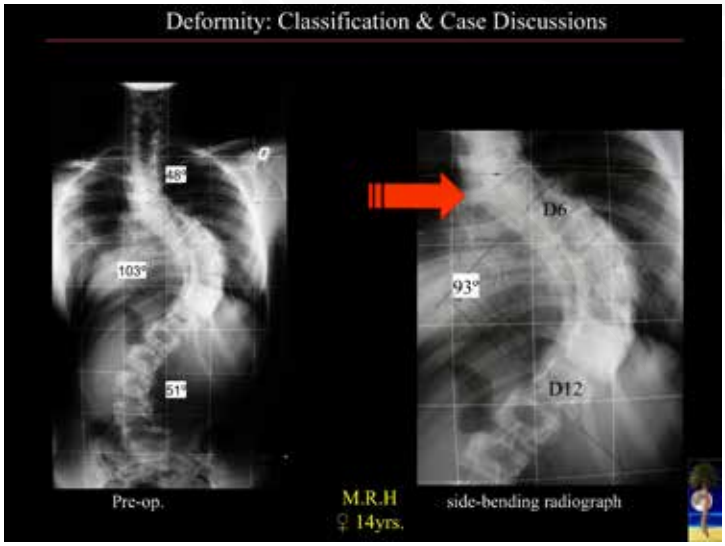
Deformity: Classification & Case Discussions
48°
103°
51°
D6
93°
D12
Pre-op.
M.R.H
♀ 14yrs.
side-bending radiograph

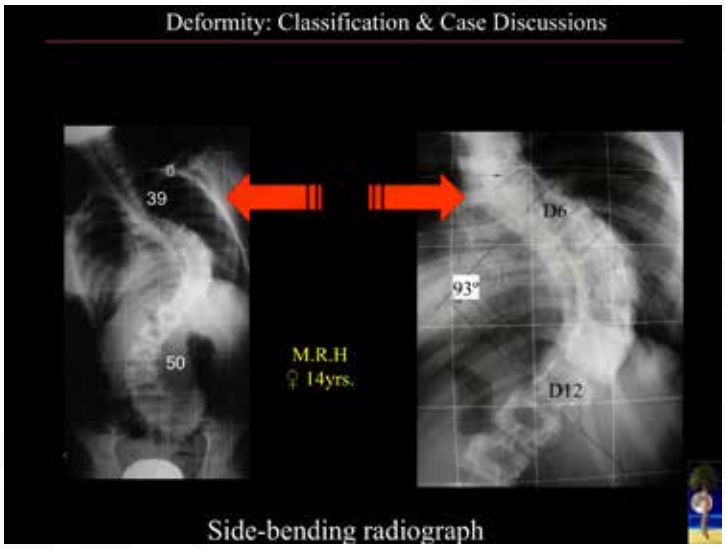
Deformity: Classification & Case Discussions
39
50
M.R.H
♀ 14yrs.
D6
93°
D12
Side-bending radiograph

Deformity: Classification & Case Discussions
M.R.H
♀ 14yrs.

Deformity: Classification & Case Discussions
M.R.H
♀ 14a.

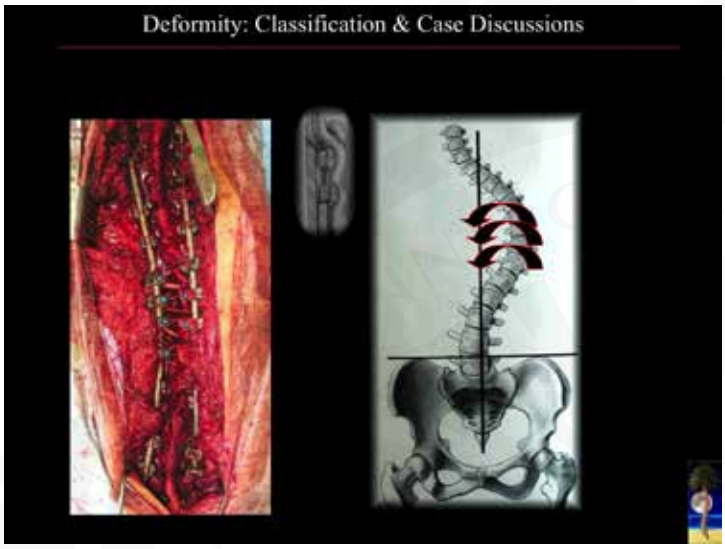
Deformity: Classification & Case Discussions

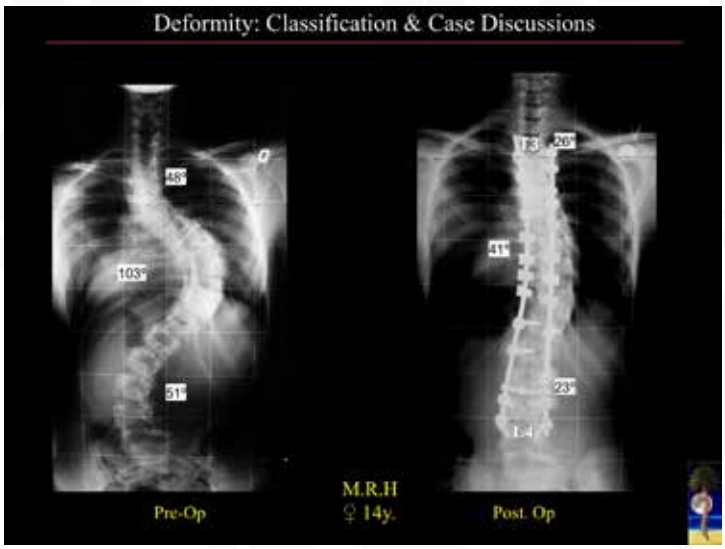
Deformity: Classification & Case Discussions
48°
103°
51°
13
26°
41°
23°
L4
Pre-Op
M.R.H
♀ 14y.
Post. Op

Deformity: Classification & Case Discussions
Pre-Op.
Post. Op

Deformity: Classification & Case Discussions
M.R.H
♀ 14a.

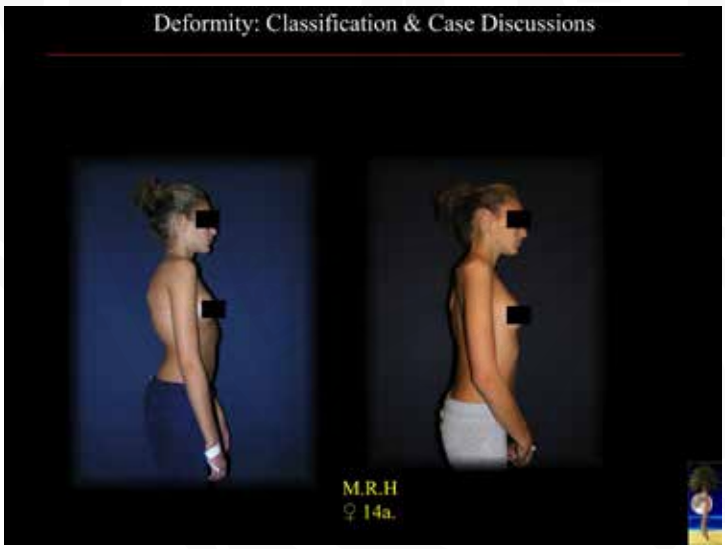
Deformity: Classification & Case Discussions
M.R.H
♀ 14a.

Deformity: Classification & Case Discussions
M.R.H
♀ 17 y
3 ys post. Op.

GOP Site: Marrakech, Morocco
98°

GOP Site: Marrakech, Morocco

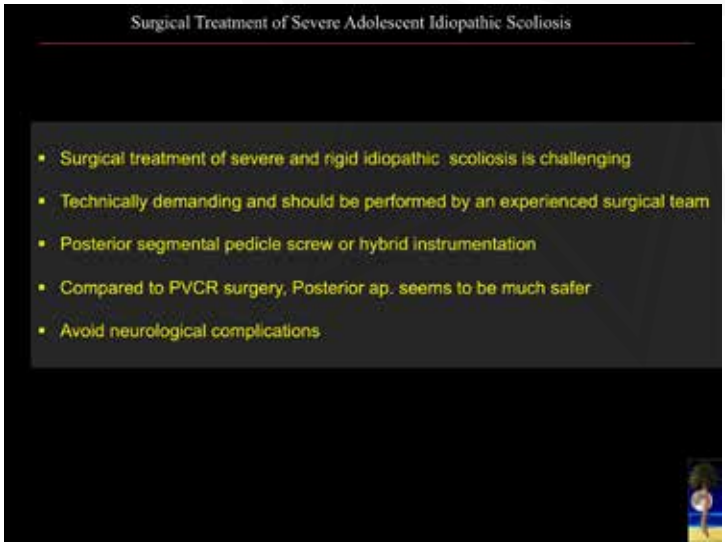
Surgical Treatment of Severe Adolescent Idiopathic Scoliosis
Surgical treatment of severe and rigid idiopathic scoliosis is challenging
Technically demanding and should be performed by an experienced surgical team
Posterior segmental pedicle screw or hybrid instrumentation
Compared to PVCR surgery, Posterior ap. seems to be much safer
Avoid neurological complications

SACRO-ILIAC FIXATION PRINCIPLE AND TECHNICAL OPTIONS

Indications

- Severe Degenerative Sacroiliitis
- Post-traumatic Sacroiliac Degeneration
- Adjacent level SI Joint Degenerative Arthritis
- SI Joint Osteolysis with Instability

SI Joint Facts

- Hyaline Cartilage with a Synovial Membrane
- Possible 4 Degrees of Rotation (Sagitta Plane) and 1.6mm Translation
- Motion does not differ Between Painful and Asymptomatic SI Joints
- Dorsal Innervation L5-S4, Ventral L5-S2
- SI Joint Does Not Typically Ankylose

Anatomy

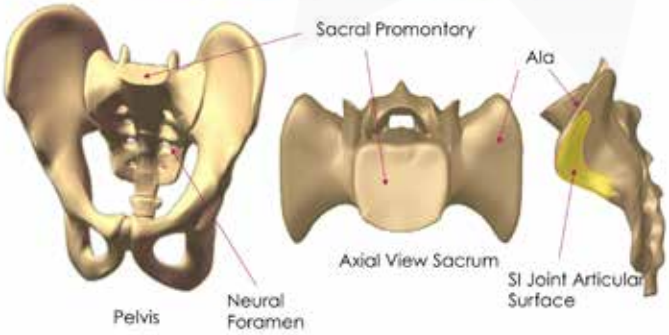

Nerves and Blood Vessels

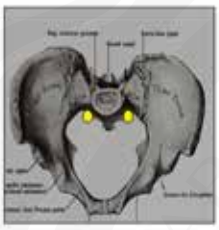

L5 Nerve Root

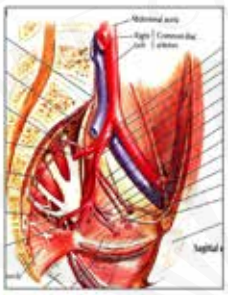

Arteries and Veins

Prevalence of SI Joint Pain

15-30% Component of Low Back Pain

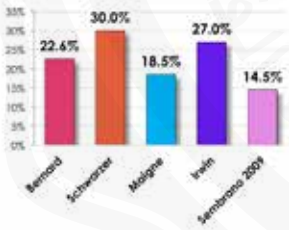

32-43% Post Lumbar Fusion SI Joint Pain

Katz 2003	32%
Maigne 2005	35%
De Palma 2011	43%
Liliang 2011	40%

ISAP SI Joint Pain Diagnosis Criteria

Merskey, H. 1994/2002, ISAP Guidelines

IASP
International Association for the Study of Pain

SI Joint Provocative Tests

3 out of 5 Positive Tests Confirm SI Joint as Pain Generator

Pain Distribution

- Pain at or Lateral to PSIS
- Pain in Buttock
- Pain in Posterolateral Thigh
- Ocassional Pain in Proximal Posterolateral Calf

Image source: http://www.arabspineinstitute.com/

SI Joint Treatment

Preoperative Radiographs

Patient Name _____ Date _____

Address _____

CT scan of the Pelvis: Bone and Soft Tissue windows, special attention to the SI Joints

(Evaluate bone and soft tissue structures of pelvis)

Thin cut bone windows to include all of the SI joint on all views (1 – 2 mm):

1. Sagittal cuts, align from lateral aspect left ilium to lateral aspect right ilium
2. Coronal cuts, parallel to the posterior sacral wall of S1 (include entire sacrum)
3. Axial cuts, align perpendicular to the coronal cuts (include entire sacrum)
4. 3D reconstruction

DX _____

Physician Name (printed) _____ *Physician Signature* _____

Implant System

- Triangular Titanium Implant
- Interference Press-fit
- Decreases Rotational Instability
- Porous Coating
- 20,000 Cases performed

Patient Positioning

- Flat Jackson Table
- Prone Position
- Rolled Blanket Under Chest, Pelvis and Ankles

C-Arm Positioning

SI Fusion Procedure

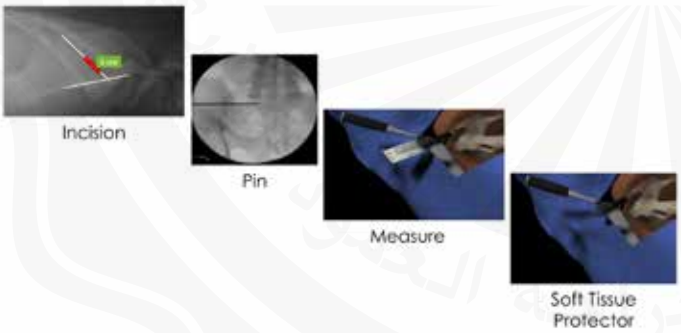

SI Fusion Procedure



Fluoroscopic View Pin Placement

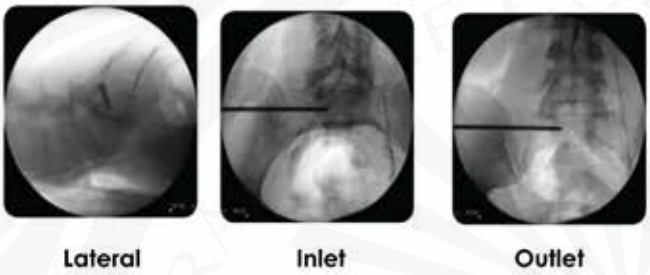

Final Implant Positioning

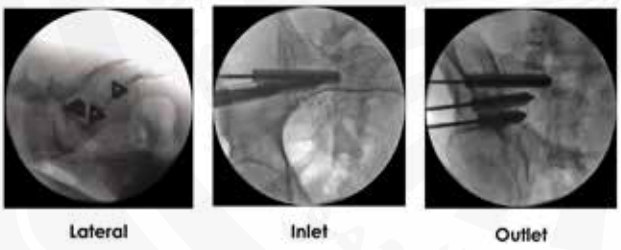

Level I Study

- Prospective, multicenter randomized controlled trial
  - 19 centers in US
  - 148 patients
  - Enrollment from January 2013 to May 2014
- Sponsored by device manufacturer (SI-BONE, Inc., San Jose, CA)

Non-Surgical Management (NSM)
(n=46)

NSAIDs
Physical Therapy
Steroid Injections
Radio Frequency Ablation

MIS SI Joint Fusion
(n=102)

SI Joint Fusion

ClinicalTrials.gov ID
NCT01681004

VAS Comparison



ODI Comparison

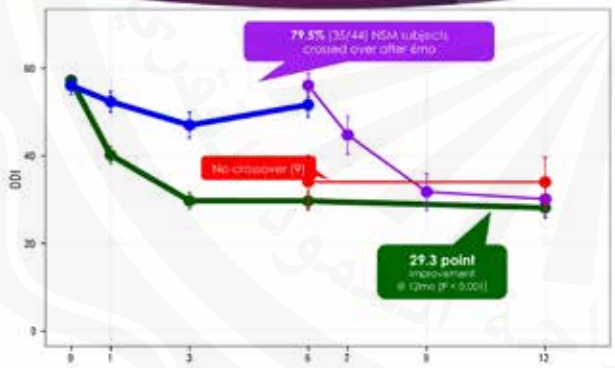

Summary

- Patient Selection Continues to be the Most important Predictor of a Good Prognosis
- Physical Examination with Provocative Testing Critical
- Patient Positioning and Fluoroscopic Alignment will Decrease Intraoperative Complications
- Still Remains the Treatment of Choice for Intractable SI Joint Pain that is Resulting in a Poor Quality of Life and an Inability to Complete Activities of Daily Living.

ROLES AND OPTIONS OF OSTEOTOMIES IN DEFORMITY CORRECTION

Sagittal balance

- Is the **balance** between the **normal sagittal curves** of the spine to center the head on the pelvis with the least energy expenditure.
- **Normal curves:**
  Cervical lordosis (≈30°)
  Thoracic kyphosis (10°-40°)
  Lumbar lordosis (40°-60°)
  These curves should balance the occiput over the sacropelvic axis.
- **Hips and Knees** share spine and pelvis in sagittal balance control.

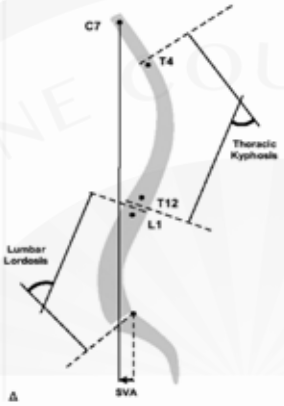

Causes of Sagittal imbalance

- **Primary spine causes:**
  -All causes of kyphosis (congenital, ankylosis, Scheuermann, neuromuscular,.....)
  - Destructive lesions(Tumors, infections)
  - Traumatic lesions (fractures)
  -Degenerative lesions (multilevel disc disease, high grade spondylolythesis)
- **Secondary spine causes:**
  - Iatrogenic flat back
  - Postlaminectomy kyphosis
  - Adjacent segment disease
- **Extra spinal causes:**
  - Hips and knees contractures

- Sagittal vertical axis (plumb line):
  - From center of C7 downwards.
  - Normally pass within 0.5 cm from the postero-superior aspect of S1.
  - Offset >2.5-4 cm ant. Or post. is abnormal.
- Thoracic kyphosis: from T2-T12
- Lumbar lordosis: from T12-S1

Normally lumbar lordosis should be 30° more than thoracic kyphosis

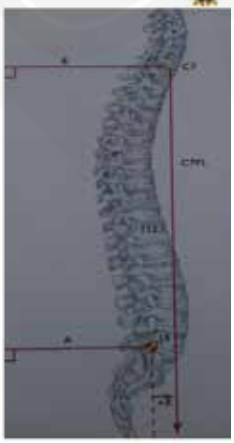

- Sacropelvic parameters:

- Pelvic incidence(PI): (50°-60°)
- Sacral slope (SS)
- Pelvic tilt angle (PT)

"PI = SS+PT"

" Lumbar lordosis is greatly related to PI"

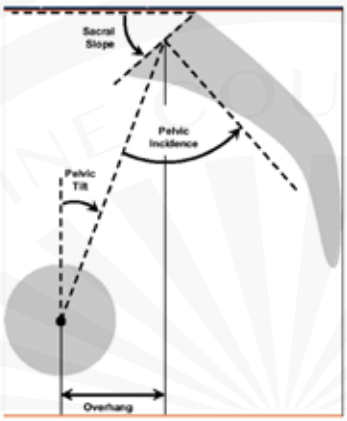

- Bridwell classification of curves:

- Totally flexible
- Partially flexible through mobile segments
- Totally inflexible (rigid)

Surgical treatment of Flexible curves (Disc based deformities)

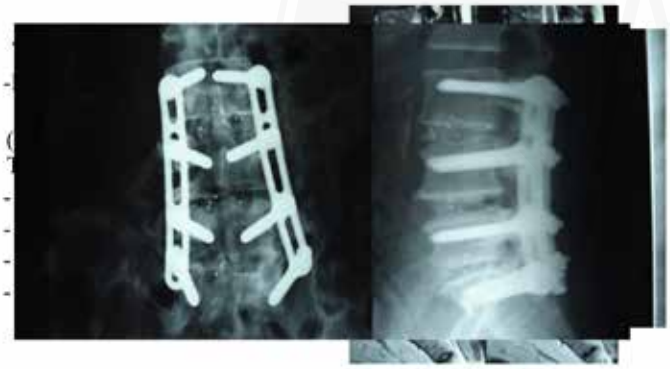

Surgical treatment of Rigid curves (osteotomies)

➢ Smith Peterson osteotomy:

- Correct 10° degrees per level.
- Hinge on the posterior disc aspect.
- It lengthen the anterior column thus may result in disastrous vascular and neurologic complication.
- Contraindicated if anterior column fused.

➢ Pedicle subtraction osteotomy:

- 3 columns osteotomy.
- 30° - 40° correction per lumbar level and 25 ° per dorsal level.
- Hinge over the anterior body cortex.
- Shorten the posterior column without anterior column lengthening.

Operative steps

- **Posterior midline approach** with sub-periosteal paravertebral muscle dissection.
- Insertion of **pedicle screws** in the desired levels above and below the osteotomy level.

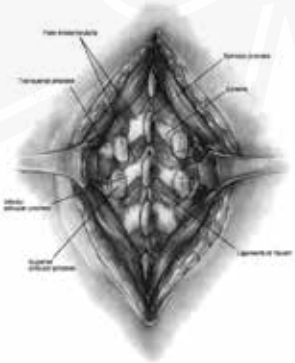

- **Wide laminectomy** over the osteotomy level and **exposure** of the **pedicle** bilaterally.

  * * The dura in long standing deformities is very thin and liable for injury.

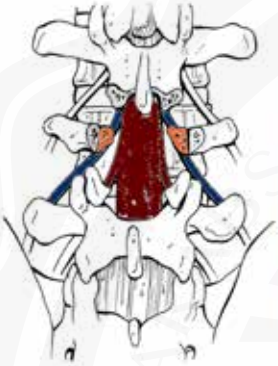

- Introduction of a **sharp osteotome** ;after **retraction of the dura;** just **above the pedicle** through the vertebral body with medial inclination.
- Introduction of the **other osteotome** below the pedicle ;after **retraction of the root;** passing below the pedicle through the body with proper angulation to produce the planned wedge.

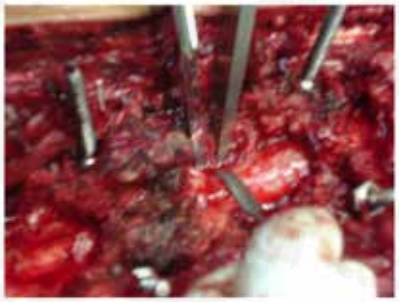

- Both osteotomes **stop behind the anterior vertebral cortex** leaving it intact.
- **Check** the position by the **image intensifier**.
- **Repeat** the same maneuver on the **contralateral pedicle**.
- **Remove the bony wedge** by manchers, curettes, rongeurs and electric burr.

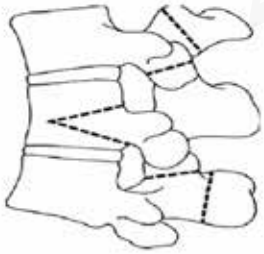

- Be sure of **removal** of the **posterior vertebral cortex** by curved curettes.

** The **dura** should be completely **free** anteriorly.

** Any **residual bone** will **buckle** against the dura when the wedge closed.

- After being sure that the dura is free all through, **extend the table** to close the wedge.

- **Assemble the rods** after contouring to the screws and apply **compression** to the screws above and below the osteotomy to finely close it.

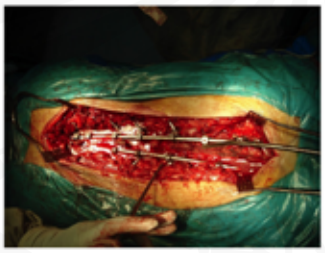

- **Somatosensory** evoked potential or **Stagnara** wake up test.
- **Recheck the dura and roots** after closure of the wedge to be sure that they are not compressed.
- **Recheck** the **whole correction** by image intensifier.
- Closure of the wound after careful haemostasis with a **haemovac** application.

Complications of pedicle subtraction osteotomy

- **Pseudo arthrosis**
  - 10 %*(Lapresle 2001)*
  - 23% *(Chiffolot 2004)*
- **Metal failure**

- **Neurological complications :**
  - **Deficits** due to:
    - **anterior subluxation,**
    - **residual dorsal impingement**
    - **dural buckling.**

- Jacob M. Buchowski and associates (110 patients) :
  Intra- and postoperative deficits: 10.9%
  Permanent deficits: 2.8%.

-Multicenteric french study of 402 cases: 18.7%.

-Van Royen BJ (2006) listed among the complications of his series postoperative nerve root compression requiring reoperation.

➢ Partial pedicle subtraction osteotomy:

- Modification of PSO.
- Preserve the lower one third of the pedicle.
- 22° per level correction.
- It protects the exiting nerve root, more smooth correction, preserve the intervertebral foramen with unchanged dimensions, no metal failure or subluxation.

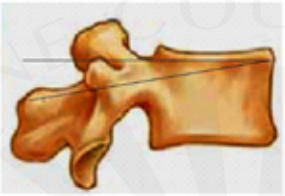

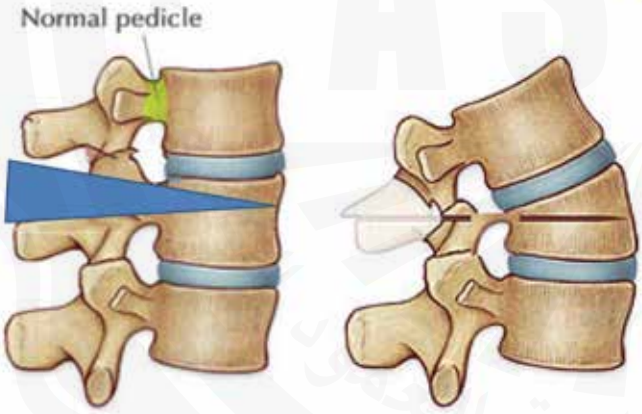

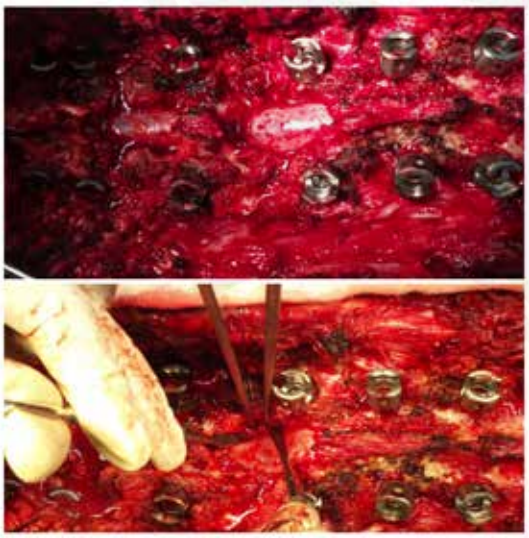

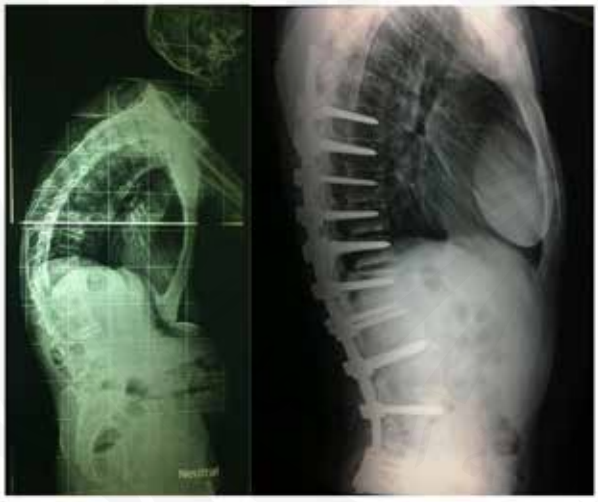

Advantages of partial pedicle subtraction osteotomy

- **Protection of the exiting nerve roots;**
  - due to preservation of the smooth inferior wall of the pedicle.
  - The vertical diameter of the intervertebral foramen unaffected.

- **Being smaller wedges:**

- Better apposition of the osteotomy site.
- Better chances for fusion (no pseudoarthrosis).
- No much force is needed to close the osteotomy (osteoporotic bone).

- **Double level PPSO in global loss of lumbar lordosis:**
  - Provides more **smooth correction** of the deformity; rather than the sharp correction at one level.
  - It **decreases the incidence of anterior subluxation** that resulted due to closing of large wedges which endangers the neural elements posteriorly due to kinking at the osteotomy sites.

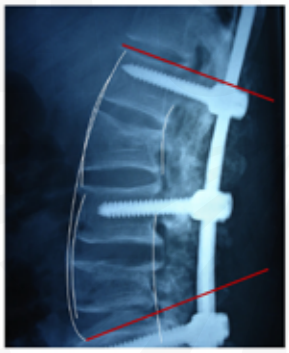

- **The remained lower third of the pedicle:**
  - **Adhere to the posterior fusion mass** and **transverse process** when fusion accomplished to connect the osteotomized vertebra to the posterior elements again.

➢ Vertebral Column Resection:

- For severe coronal, sagittal deformity, spondyloptosis, tumors.
- Can be done totally posterior.
- Involve resection of a vertebra or more followed by anterior reconstruction and posterior fusion.

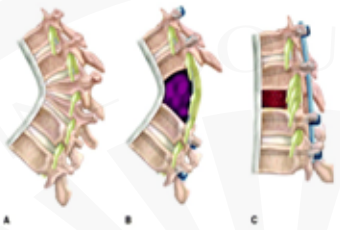

- The only procedure that will provide translation of spinal column.
- VCR reduces morbidity and complication.
- Offers more reliable reconstruction of the vertebral column than the conventional anteroposterior VCR.

Suk et al. 2005

- Significant correction can be achieved at a single level.
- Offers the advantage of a controlled manipulation (translational and rotational) of both the anterior and posterior column at the same time through a single approach.

Lawrence G. Lenke 2007
Azmi Hamzaoglu et al. 2012

- Female
- 30 yrs
- Deformity since birth
- Severe Kyphosis
- Resection D12 + Fixation D8→L4
- Reconstruction Rib strut

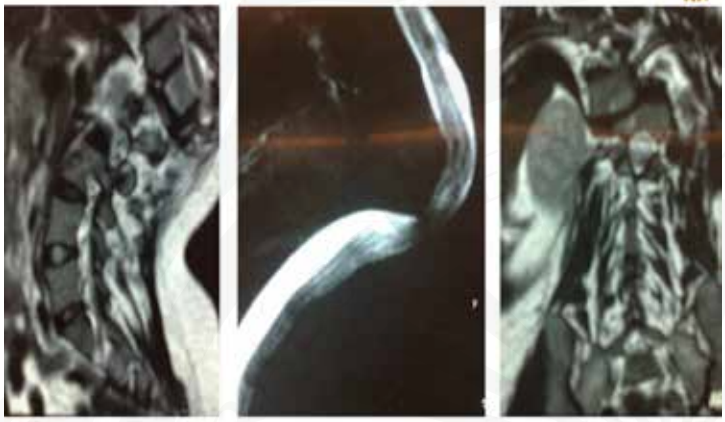

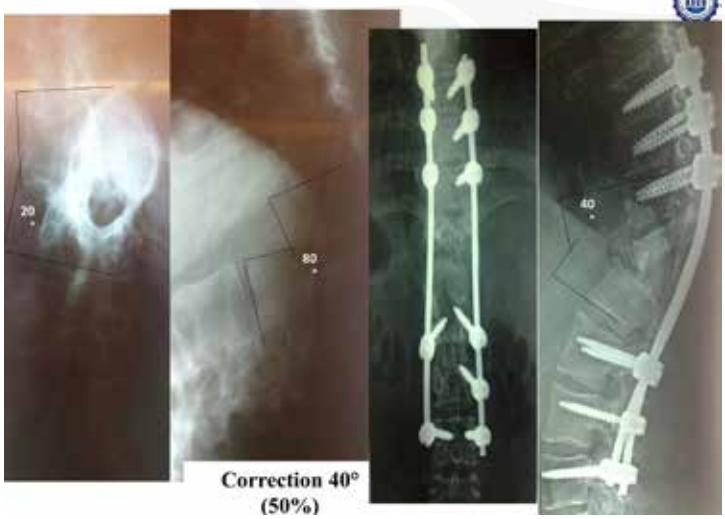
Correction 40°
(50%)

- Female
- 30 yrs
- MCA → Missed Burst D4 Fracture
- Paraplegic
- Resection D4 Fixation D2→ D6
- Reconstruction by Rib straut
- Fusion after 1 yr (Mild loss of 5°)
- Pt regained L.L function Grade III

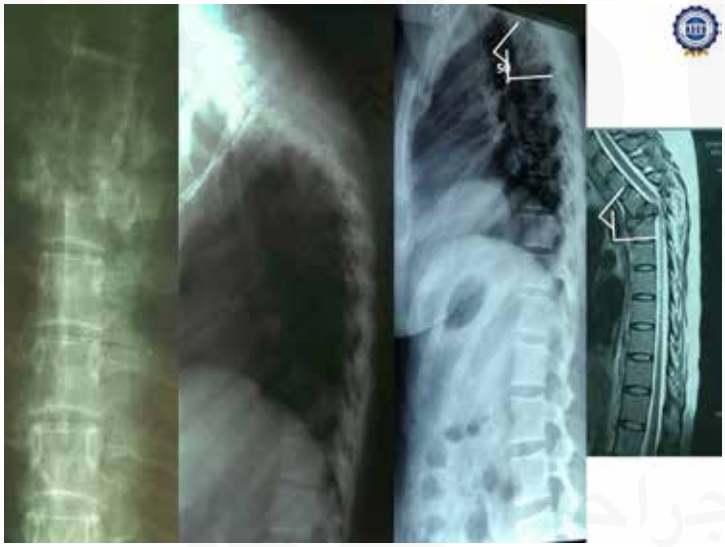

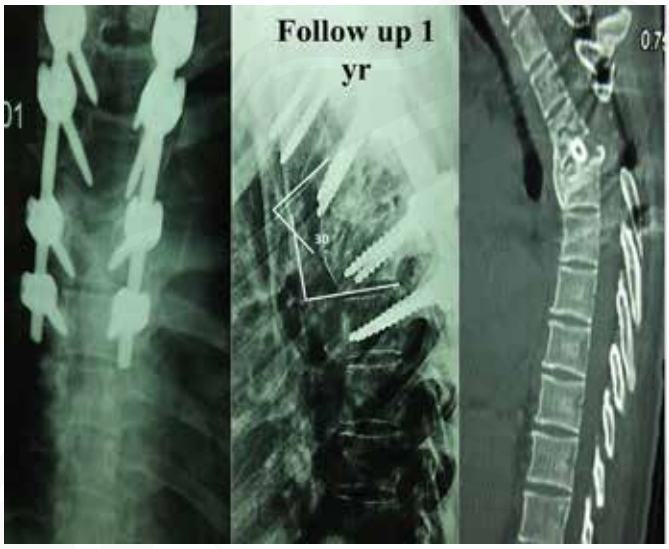

- Male
- 52 yrs
- Back pain (progressively inc.)
- UMNL manifestation (clonus, Hyper-reflexia, retention with overflow)
- Congenital wedging D4,5,6
- Resection D4,5,6 + Fixation D2-D9
- Reconstruction Rib strut + Morselized B.G
- Postoperative → Brace

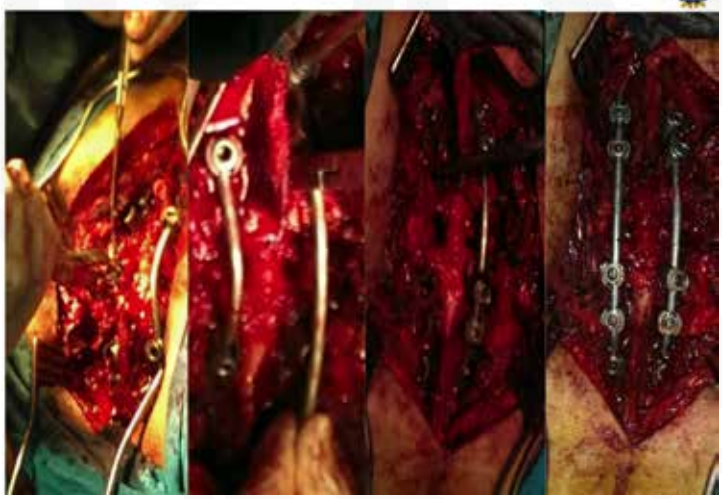

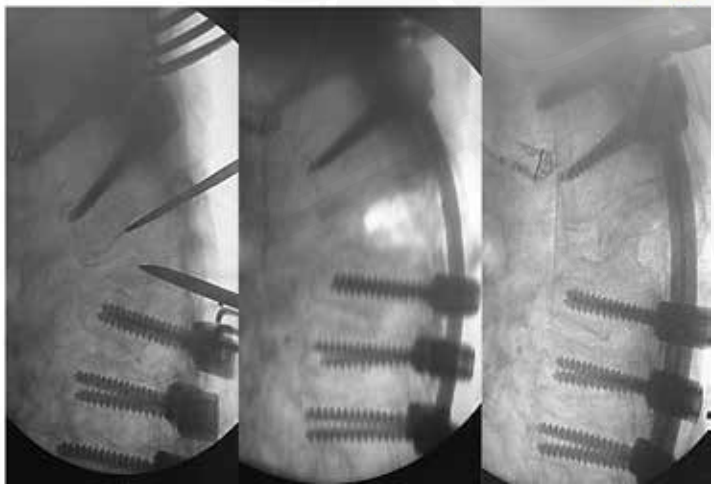

- Male
- 35 yrs
- Addict HCV + ve
- Painful Deformity of back noticed 20 days ago
- No Toxic symptoms
- Neurologically intact
- Spondylodiscitis D12,L1(Pott's spine)
- Resection D12,L1 + Fixation D9-L3
- Reconstruction Rib strut + Morselized B.G
- Dural tear + avulsion L1 root → CSF leak
- C&S → T.B

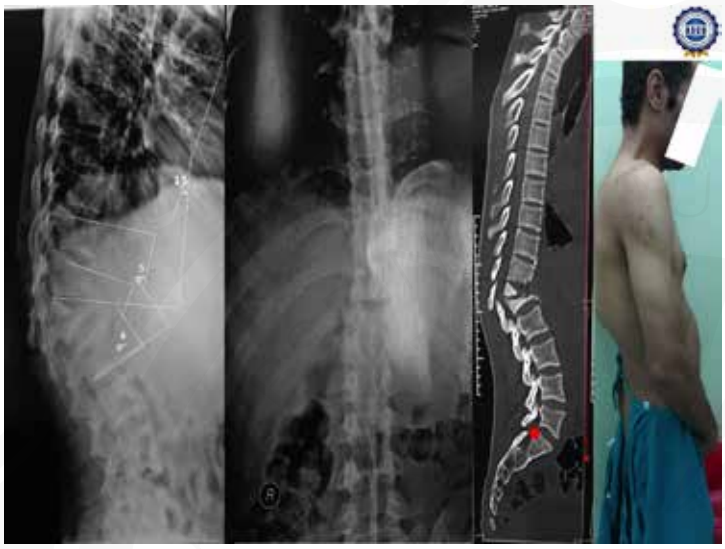

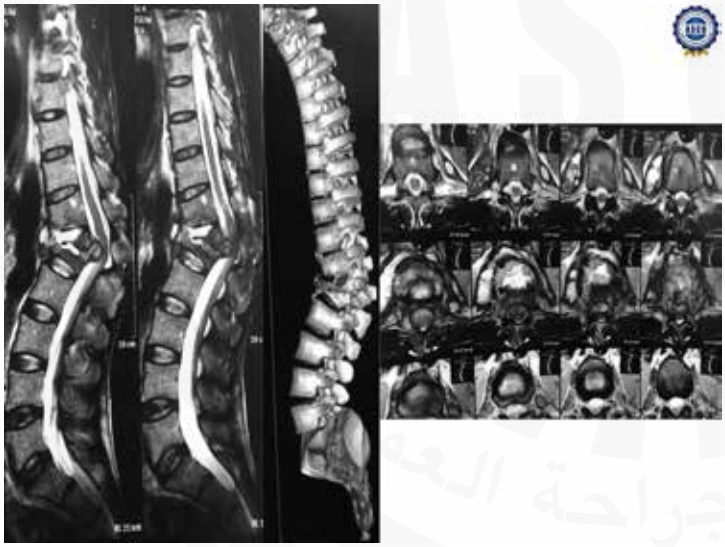

Correction 55°
(92%)

- Female
- 53 yrs
- Back pain 3 months ago
- Complete Paraplegia + sensory level umbilicus
- Urine + Stool incontinence
- Spondylodiscitis D8,9
- Resection D8,9 + Fixation D5→D11
- Reconstruction Mesh cage + B.G
- Post operative infection → Debridement

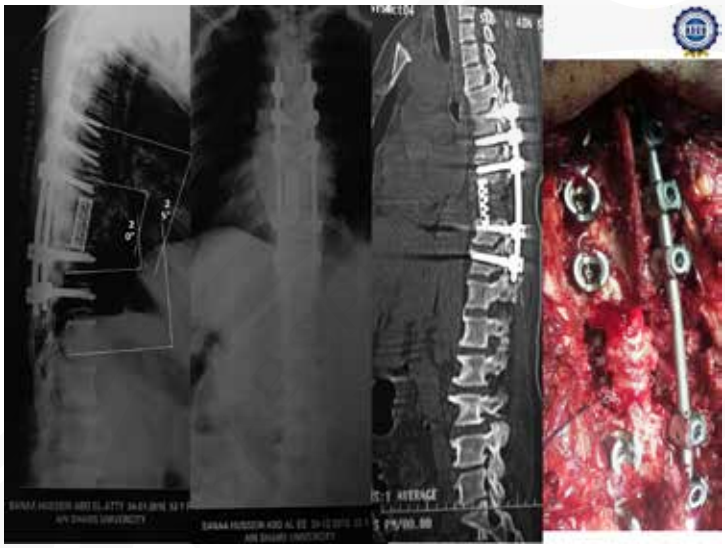

- Male
- 4 yrs
- Deformity since birth (progressively inc.)
- Congenital dislocation of the spine
- Neurologically intact
- Resection L1 + Fixation D11-L4
- Reconstruction Morselized B.G
- Postoperative casting → Brace

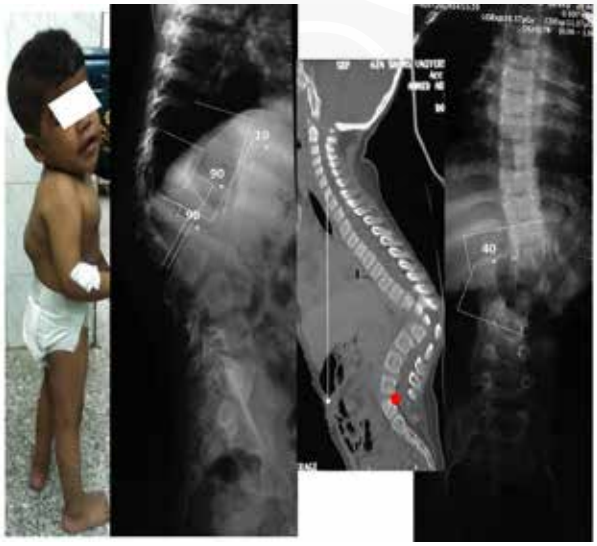

Correction 50°
(55%)

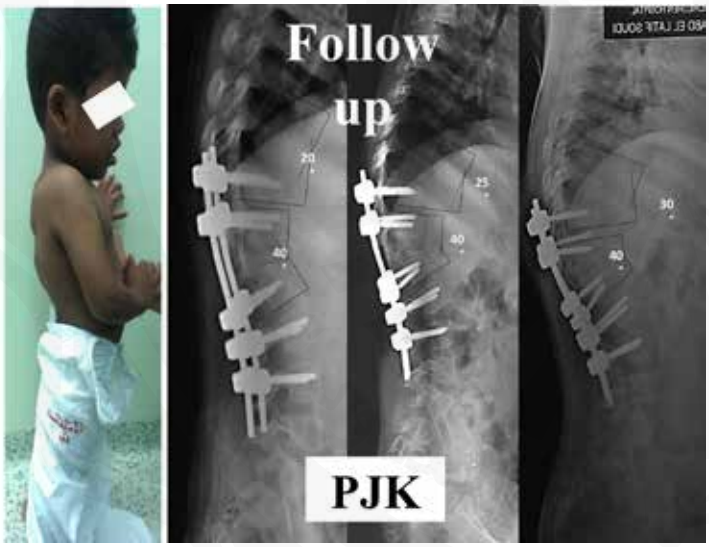

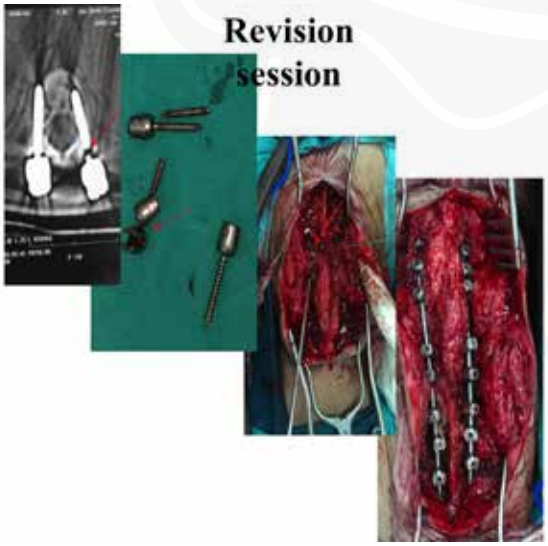

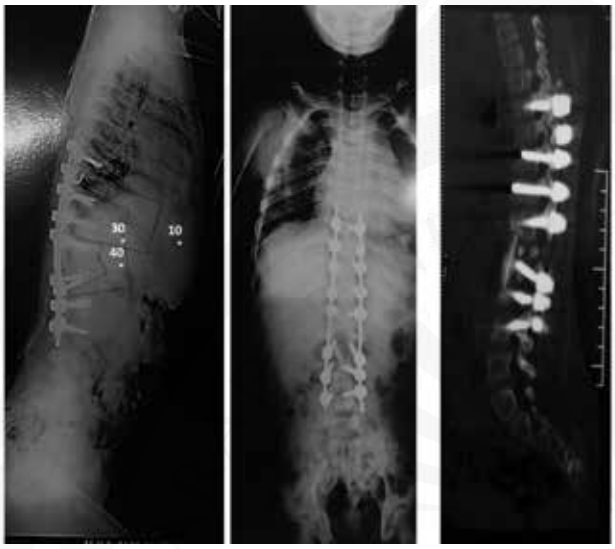

➢ Cervical osteotomy:

- To elevate the chin from the sternum.
- Prevent atlantoaxial and cervical subluxations and dislocations by weight of the head.
- To relieve tracheal and esophageal distortion.
- To prevent irritation of the spinal cord tracts or excessive traction on the nerve roots.
- Usually done at the lower cervical spine.

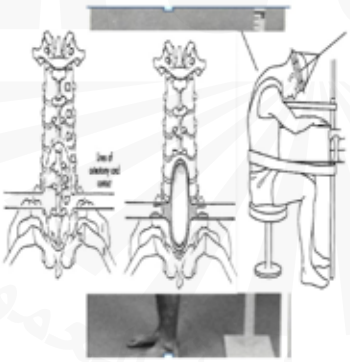

Schwab classification(2013):

TABLE 1. Spinal Osteotomy Classification

	Anatomic Resection	Description	Surgical Approach Modifiers
Grade 1	Partial facet joint	Resection of the inferior facet and joint capsule at a given spinal level	P (posterior approach only)
Grade 2	Complete facet joint	Both superior and inferior facets at a given spinal segment are resected with complete ligamentum flavum removal; other posterior elements of the vertebra including the lamina, and the spinous processes may also be resected	P (posterior approach only) A/P (anterior soft tissue release combined with posterior resection)
Grade 3	Pedicle/partial body	Partial wedge resection of a segment of the posterior vertebral body and a portion of the posterior vertebral elements with pedicles	P (posterior approach only) A/P (both)
Grade 4	Pedicle/partial body/disc	Wider wedge resection through the vertebral body; includes a substantial portion of the posterior vertebral body, posterior elements with pedicles, and includes resection of at least a portion of 1 endplate with the adjacent intervertebral disc	P (posterior approach only) A/P (both)
Grade 5	Complete vertebra and discs	Complete removal of a vertebra and both adjacent discs (rib resection in the thoracic region)	P (posterior approach only) A/P (both)
Grade 6	Multiple vertebrae and discs	Resection of more than one entire vertebra and adjacent discs. Grade 5 resection and additional adjacent vertebral resection	P (posterior approach only) A/P (both)

Please refer to book of

DAY-2 (MODULE-4)

for continuation...

ARABSPINE COU
AS
الفقري
راحة العمود